This is a digital copy of a book that was preserved for generations on library shelves before it was carefully scanned by Google as part of a project to make the world's books discoverable online.

It has survived long enough for the copyright to expire and the book to enter the public domain. A public domain book is one that was never subject to copyright or whose legal copyright term has expired. Whether a book is in the public domain may vary country to country. Public domain books are our gateways to the past, representing a wealth of history, culture and knowledge that's often difficult to discover.

Marks, notations and other marginalia present in the original volume will appear in this file - a reminder of this book's long journey from the publisher to a library and finally to you.

Usage guidelines

Google is proud to partner with libraries to digitize public domain materials and make them widely accessible. Public domain books belong to the public and we are merely their custodians. Nevertheless, this work is expensive, so in order to keep providing this resource, we have taken steps to prevent abuse by commercial parties, including placing technical restrictions on automated querying.

We also ask that you:

+ *Make non-commercial use of the files* We designed Google Book Search for use by individuals, and we request that you use these files for personal, non-commercial purposes.
+ *Refrain from automated querying* Do not send automated queries of any sort to Google's system: If you are conducting research on machine translation, optical character recognition or other areas where access to a large amount of text is helpful, please contact us. We encourage the use of public domain materials for these purposes and may be able to help.
+ *Maintain attribution* The Google "watermark" you see on each file is essential for informing people about this project and helping them find additional materials through Google Book Search. Please do not remove it.
+ *Keep it legal* Whatever your use, remember that you are responsible for ensuring that what you are doing is legal. Do not assume that just because we believe a book is in the public domain for users in the United States, that the work is also in the public domain for users in other countries. Whether a book is still in copyright varies from country to country, and we can't offer guidance on whether any specific use of any specific book is allowed. Please do not assume that a book's appearance in Google Book Search means it can be used in any manner anywhere in the world. Copyright infringement liability can be quite severe.

About Google Book Search

Google's mission is to organize the world's information and to make it universally accessible and useful. Google Book Search helps readers discover the world's books while helping authors and publishers reach new audiences. You can search through the full text of this book on the web at `http://books.google.com/`

[redacted]

No 7786.3

OMNIVM CIVIVM

OF THE CITY OF BOSTON
1852 1878



THE FRANCIS A. COUNTWAY
LIBRARY OF MEDICINE
BOSTON, MA

SEP 03 2003

TRANSACTIONS

OF THE

PATHOLOGICAL SOCIETY OF LONDON.

VOLUME THE FIFTY-FIFTH.

COMPRISING THE REPORT OF THE PROCEEDINGS FOR THE SESSION 1903-1904.

THE FRANCIS A. COUNTWAY
LIBRARY OF MEDICINE
BOSTON, MA

SEP 03 2003

Edited by Samuel G. Shattock.

LONDON:
SMITH, ELDER & CO., 15 WATERLOO PLACE.
1904

THE Council think it right to state that the authors of the several communications herein published are alone responsible for the statements made or the views put forward by them.

Mar. 2. 1905
*7786 C
v. 55

PUBLIC LIBRARY
OF THE
CITY OF BOSTON

TABLE OF CONTENTS

OF VOLUME LV.

	PAGE
List of Presidents of the Society	iv
List of Officers and Members for 1904–1905	v
Annual Report of the Council for 1903-1904	xxix
List of Communications made during the Session 1903–1904	xxxiii
List of Reports by Committees	xxxv
List of Plates	xxxvi
List of Figures in the Text	xxxvii
Communications	1
Index	459

Presidents of the Society.

ELECTED

1846 CHARLES J. B. WILLIAMS, M.D., F.R.S.
1848 CHARLES ASTON KEY.
1850 PETER MERE LATHAM, M.D.
1852 CÆSAR H. HAWKINS, F.R.S.
1853 BENJAMIN GUY BABINGTON, M.D., F.R.S.
1855 JAMES MONCRIEFF ARNOTT, F.R.S.
1857 SIR THOMAS WATSON, BART., M.D., F.R.S.
1859 SIR WILLIAM FERGUSSON, BART., F.R.S.
1861 JAMES COPLAND, M.D., F.R.S.
1863 SIR PRESCOTT G. HEWETT, BART., F.R.S.
1865 THOMAS BEVILL PEACOCK, M.D.
1867 SIR JOHN SIMON, K.C.B., D.C.L., F.R.S.
1869 SIR RICHARD QUAIN, BART., M.D., LL.D., F.R.S.
1871 JOHN HILTON, F.R.S.
1873 SIR WILLIAM JENNER, BART., M.D., G.C.B., D.C.L., F.R.S.
1875 GEORGE D. POLLOCK.
1877 CHARLES MURCHISON, M.D., LL.D., F.R.S.
1879 JONATHAN HUTCHINSON, F.R.S.
1881 SIR SAMUEL WILKS, BART., M.D., F.R.S.
1883 JOHN WHITAKER HULKE, F.R.S.
1885 JOHN SYER BRISTOWE, M.D., F.R.S.
1887 SIR JAMES PAGET, BART., D.C.L., LL.D., F.R.S.
1889 WILLIAM HOWSHIP DICKINSON, M.D.
1891 SIR GEORGE MURRAY HUMPHRY, M.D., LL.D., F.R.S.
1893 FREDERICK WILLIAM PAVY, M.D., LL.D., F.R.S.
1895 HENRY TRENTHAM BUTLIN, D.C.L.
1897 JOSEPH FRANK PAYNE, M.D.
1899 WILLIAM WATSON CHEYNE, C.B., F.R.S.
1902 SIR JOHN BURDON SANDERSON, BART., M.D., D.C.L., F.R.S.

OFFICERS AND COUNCIL

OF THE

Pathological Society of London,

ELECTED AT

THE GENERAL MEETING, MAY 17TH, 1904,

FOR THE SESSION 1904–1905.

President.

SIR JOHN BURDON SANDERSON, BART., M.D., D.C.L., F.R.S.

Vice-Presidents.

R. J. GODLEE. (1)
W. D. HALLIBURTON, F.R.S. (4)
E. KLEIN, F.R.S. (2)
F. W. PAVY, F.R.S. (3)

Treasurer.

P. H. PYE-SMITH, M.D., F.R.S.

Council.

Members of Committee of Section A.

F. E. BATTEN.
J. H. DRYSDALE.
J. FAWCETT.
H. M. FLETCHER.
H. BATTY SHAW.
C. P. WHITE.

Members of Committee of Section B.

F. W. ANDREWES.
J. W. H. EYRE.
A. G. R. FOULERTON.
R. T. HEWLETT.
J. RITCHIE.
A. E. WRIGHT.

Members of Committee of Section C.

J. R. BRADFORD, F.R.S.
C. J. MARTIN, F.R.S.
M. S. PEMBREY, M.D.
E. H. STARLING, F.R.S.

Members of Committee of Section D.

V. HARLEY.
J. B. LEATHES.
F. G. HOPKINS.

Sectional Secretaries.

Section A.
G. F. STILL, M.D.

Section B.
W. BULLOCH, M.D.

Section C.
T. G. BRODIE, M.D., F.R.S.

Section D.
A. E. GARROD, M.D.

General Secretary and Editor of the 'Transactions.'

S. G. SHATTOCK.

Trustees.

J. F. PAYNE.
HENRY MORRIS.
THOMAS BRYANT.

NOTE.—Section A: Pathological Anatomy and Histology. Section B: Bacteriology. Section C: Experimental Pathology. Section D: Chemical Pathology.
(1) Chairman of Section A. (2) Chairman of Section B.
(3) Chairman of Section C. (4) Chairman of Section D.

Committees.

The members of Council forming each Section (A, Pathological Anatomy and Histology; B, Bacteriology; C, Experimental Pathology; D, Chemical Pathology) constitute committees of reference in the subjects enumerated, with power to add to their numbers in particular cases.

*** *Members are requested to inform the General Secretary of any change of address, etc., which may be necessary.*

LIST OF MEMBERS OF THE SOCIETY.

Honorary Members.

BOUCHARD, C., M.D., Professor of General Pathology, Paris.
CHAUVEAU, A., M.D., Professor of Physiology at the Medical School of Lyons.
KOCH, R., M.D., Director of the Institute for Infective Diseases, Berlin.
The Right Honourable Lord LISTER, F.R.S., F.R.C.S., 12, Park crescent, Portland place, W.
METCHNIKOFF, E., M.D., Chef de Service à l'Institut Pasteur, Paris.
ORTH, J., M.D., Professor of Pathological Anatomy in the University of Berlin.
VON RECKLINGHAUSEN, F. D., Director of the Pathological Institute, Strassburg.
RINDFLEISCH, E., M.D., Professor of Pathological Anatomy in the University of Bonn.
ROUX, P. P. E., M.D., Sous-directeur de l'Institut Pasteur, Paris.
SALOMONSEN, C. J., Professor of General Pathology and Bacteriology in the University of Copenhagen.
WELCH, W. H., M.D., Professor of Pathology, Johns Hopkins University, Baltimore.
WILKS, SIR SAMUEL, Bart., M.D., LL.D., F.R.S., F.R.C.P., 8, Prince Arthur Road, Hampstead, N.W.
ZIEGLER, E., M.D. Professor of Pathological Anatomy, Freiburg.

EXPLANATION OF ABBREVIATIONS.

P.—President.
T.—Treasurer.
V.-P.—Vice-President.
S.—Secretary.
C.—Member of Council.
E.—Editor of the 'Transactions.'

The surnames of Members who have compounded for their subscriptions are printed in this type (**TYPE**). The surnames of Members who have paid the Composition Fee for the 'Transactions' are printed in this type (**Type**).

GENERAL LIST OF MEMBERS.

Elected

1879 **ABERCROMBIE**, JOHN, M.D., 23, Upper Wimpole street, W. (C. 1897-1900.)

1896 ABRAHAMS, BERTRAM LOUIS, B.Sc., M.B., 14, Welbeck street, W.

1883 ACLAND, THEODORE DYKE, M.D., 19, Bryanston square, W. (C. 1892-4.)

1891 ADAMI, J. GEORGE, M.A., M.D., Montreal, Canada.

1890 ADAMS, JAMES, M.D., 4, Chiswick place, Eastbourne.

1848 **AIKIN**, CHARLES A., 12, Ladbroke terrace, W. (C. 1864-6.)

1872 AIKIN, CHARLES EDMUND, Llandrillo, Corwen, North Wales.

1897 ALCOCK, SAMUEL K., M.D., Portland House, Burslem.

1882 **ALLCHIN**, WILLIAM HENRY, M.D., 5, Chandos street, W.

1884 ANDERSON, ALEXANDER RICHARD, 5, East Circus street, Nottingham.

1897 ANDREWES, FREDERICK W., M.D., 31, Hampstead lane, Highgate, N. (C. 1900—. Com. Sect. B, 1901—.)

1902 ARMOUR, DONALD, M.B., 89, Harley street, W.

1883 ASHBY, HENRY, M.D., 13, St. John street, Manchester.

1863 BAGSHAWE, FREDERICK, M.A., M.D., 35, Warrior square, St. Leonard's-on-Sea.

1904 BAILEY, WILLIAM HENRY, M.B., Featherstone Hall, Southall, Middlesex.

1902 BAINBRIDGE, F. A., M.B., 1, Vernon Chambers, Southampton row, W.C.

1856 **Balding**, DANIEL BARLEY, Royston, Herts.

1881 BALLANCE, CHARLES A., M.S., 106, Harley street, W. (C. 1890-2. C. Com. Sect. C, 1901—4. S. 1899—1901.)

1875 BARKER, ARTHUR E. J., 87, Harley street, W. (C. 1884-6. V.P. 1896-7.)

1899 BARKER, A. J. G., Kuching, Sarawak, Borneo.

1885 BARLING, GILBERT, M.B., 87, Cornwall street, Newhall street, Birmingham. (C. 1894-7.)

1901 BARNARD, HAROLD L., M.S., 21, Wimpole street, W.

1874 **BARLOW**, Sir THOMAS, Bart., K.C.V.O., M.D., B.S., 10, Wimpole street, W. (C. 1879-81. V.-P. 1894-6.)

1899 BARRATT, JOHN OGLETHORPE WAKELIN, M.D., Schnorrstrasse, 9, München.

1877 BARROW, A. BOYCE, 8, Upper Wimpole street, W.

1881 BARRS, ALFRED GEORGE, M.D., 22, Park place, Leeds.

1853 **BARWELL**, RICHARD, 55, Wimpole street, W. (C. 1862-4. V.-P. 1889-90.)

Elected

1861 **BASTIAN**, H. CHARLTON, M.A., M.D., F.R.S., 8A, Manchester square, W. (C. 1869-71. V.-P. 1885-7.)

1877 BATEMAN, ARTHUR W., B.A., Tenterfield, New South Wales.

1895 BATTEN, FREDERICK E., M.D., 33, Harley street, W. (C. Com. Sect. A, 1903—.)

1876 **BATTESON**, JOHN, 188, Goldhawk road, Shepherd's Bush.

1882 BATTLE, WILLIAM HENRY, 49, Harley street, W. (C. 1898—1901.)

1902 BAUMANN, E. P., M.D., 38, Harley street, W.

1870 BÄUMLER, CHRISTIAN G. H., M.D., University of Erlangen.

1874 BEACH, FLETCHER, M.B., 79, Wimpole street, W., and Winchester House, Kingston Hill, Surrey.

1892 BEADLES, CECIL F., Colney Hatch Lunatic Asylum, N. (C. 1898—1901.)

1879 BEALE, EDWIN CLIFFORD, M.B., 23, Upper Berkeley street, W.

1852 **BEALE**, LIONEL S., M.B., F.R.S., 6, Bentinck street, Manchester square, W. (C. 1858-9. V.-P. 1874-5.)

1856 BEALEY, ADAM, M.D., M.A., Felsham Lodge, Hollington park, St. Leonard's-on-Sea.

1900 BEATON, ROBERT MILNE, M.B., 97, Dartmouth park avenue, N.W.

1897 BEDDARD, ARTHUR P., M.D., 44, Seymour street, W.

1865 BEEBY, WALTER, M.D., Rapollo, Liguria, Italy (Nov.—May), and Varallo, Valsesia (May, June, Sept., Oct.).

1880 **BEEVOR**, CHARLES EDWARD, M.D., 135, Harley street, W. (C. 1888-90.)

1883 BENHAM, R. FITZROY, 11, Earl's Court square, S.W.

1886 BENNETT, FREDERICK JOSEPH, 17, George street, Hanover square, W.

1877 BENNETT, Sir WILLIAM HENRY, K.C.V.O., 1, Chesterfield street, W. (C. 1891-3.)

1889 BENTLEY, ARTHUR, J. M., M.D., Mena House, Pyramids, Cairo, Egypt.

1878 BERNARD, FRANCIS R., M.D., Prawls, Stone, near Tenterden, Kent.

1882 BERRIDGE, WILLIAM ALFRED, Redhill, Surrey.

1886 BERRY, JAMES, B.S., 21, Wimpole street, W. (C. 1895-7.)

1903 BEVERIDGE, WILFRID WILLIAM OGILVIE, M.B., R.A.M.C., D.S.O., c/o Sir C. R. McGrigor, Bart., and Co., 25, St. James's square, S.W.

1856 **Bickersteth**, EDWARD R., 2, Rodney street, Liverpool.

1882 BINDLEY, PHILIP HENRY, M.B. Address uncommunicated.

1865 BISSHOPP, JAMES, Mount Pleasant, Tunbridge Wells.

1889 BLACK, ROBERT, M.D., 14, Pavilion Parade, Brighton.

1863 BLANCHET, JEAN B., M.D., M.S., Montreal, Quebec, Canada.

1879 BOILEAU, J. P. H., M.D., Brigade-Surgeon, Army.

1900 BOKENHAM, THOMAS JESSOPP, 10, Devonshire street, Portland place, W.

1904 BOLTON, CHARLES, M.D., 22, Bentinck street, Manchester square, W.

1900 BOLTON, JOSEPH SHAW, M.D., B.S., B.Sc., East Sussex County Asylum, Hellingly S.O., Sussex.

1902 BONNEY, W. F. VICTOR, M.D., M.S., 10, Devonshire street, Portland place, W.

1899 BOSANQUET, W. CECIL, M.D., 117*a*, Harley street, W.

1869 BOURNE, WALTER, M.D. (Travelling).

1861 BOWER, RICHARD NORRIS (Travelling).

Elected

1881 BOWLBY, ANTHONY A., C.M.G., 24, Manchester square, W. (M.G.C. 1884—1900. C. 1886-8, 1895-7. S. 1893-5. V.-P. 1898—1900.)

1895 BOX, CHARLES R., M.D., 2, Devonshire place, Portland Place, W.

1892 BOYCE, RUBERT WILLIAM, M.S., F.R.S., Thompson Yates Laboratories, Liverpool University, Liverpool.

1904 BOYCOTT, ARTHUR FAGIN, B.Sc., M.B., B.Ch., Guy's Hospital, S.E.

1882 BOYD, STANLEY, B.S., 134, Harley street, W. (C. 1893-6. V.-P. 1897-9.)

1889 BRADFORD, JOHN ROSE, M.D., F.R.S. 8, Manchester square, W. (C. 1897—1900. C. Com. Sect. C, 1902—. S. 1900-2.)

1880 BRAMWELL, BYROM, M.D., 23, Drumsheugh Gardens West, Edinburgh.

1889 BREDIN, J. NOBLE, The Vines, Sutton Valence, Maidstone.

1902 BREWERTON, ELMORE W., 45, Weymouth street, W.

1877 BRIDGES, ROBERT, M.B., M.A., Manor House, Yattendon, Berks.

1867 **Bridgewater**, THOMAS, LL.D. Glas., M.B. Lond., Harrow-on-the-Hill, Middlesex.

1873 BRIGGS, JACOB MYERS, M.D., Coeymans, New York, U.S.A.

1868 BRIGHT, GEORGE CHARLES, M.D., Cannes, Alpes Maritimes, France.

1902 BRINCKER, JOHN AUGUSTUS HERMAN, M.B., B.C., Borough Hospital, Waddon, Croydon.

1857 BRISCOE, JOHN, 5, Broad street, Oxford.

1885 BRISCOE, JOHN F., Westbrooke House, Alton, Hants.

1903 BROADBENT, J. F. H., M.D., 35, Seymour street, W.

1860 **BROADBENT**, Sir WILLIAM HENRY, Bart., M.D., 84, Brook street, W. (C. 1871-3. V.P. 1882-4.)

1886 BROCKATT, ANDREW ALEXANDER, M.D., Hazeldean, Malvern.

1884 BRODIE, CHARLES GORDON, Fernhill, Wootton Bridge, Isle of Wight.

1899 BRODIE, THOMAS GRIGOR, M.D., F.R.S. (HON. SECRETARY, SECTION C.), 4, Lancaster terrace, Regent's Park, N.W. (C. 1900—1901. S. Sect. C. 1901—.)

1871 BROWN, FREDERICK GORDON, 17, Finsbury circus, E.C.

1903 BROWNE, H. S. D., 78, High street, Winchester.

1877 BRUCE, J. MITCHELL, M.D., 23, Harley street, W.

1902 BRUCE, SAMUEL NOBLE, 15, Queensborough terrace, W.

1890 BRUNTON, Sir T. LAUDER, M.D., D.Sc., LL.D., F.R.S., 10, Stratford place, W.

1898 BRYANT, JOHN HENRY, M.D., 4, St. Thomas's street, London bridge, S.E.

1855 **BRYANT**, THOMAS, M.Ch. (TRUSTEE), 27, Grosvenor street, Grosvenor square, W. (C. 1863-6. V.-P. 1877-9.)

1894 BUCHANAN, GEORGE SEATON, M.D., 9, Hammersmith terrace, W.

1890 BUCKLAND, FRANCIS O., M.A., M.B., C.M., Brockenhurst, Hants.

1899 BULLOCH, WILLIAM, M.D., M.B., C.M. (HON. SECRETARY, SECT. B), 66, Holland road, Kensington, W. (C. Com. Sect. B, 1901-3. S. Com. Sect. B, 1903—.)

1891 BURGHARD, FRÉDÉRIC FRANÇOIS, M.D., M.S., 86, Harley street, W.

1880 BURTON, SAMUEL HERBERT, M.B., 50, St. Giles' street, Norwich.

1900 BUSCH, JOSEPH PAUL-ZUM, M.D., Chiswell House, 133, Finsbury Pavement, E.C.

Elected

1903 BUSHNELL, FRANK GEORGE, M.D., 20, Athenæum street, Plymouth.

1872 **BUTLIN**, HENRY TRENTHAM, D.C.L., 82, Harley street, W. (M.G.C. 1875-86. C. 1876-8, 1887-9. S. 1884-6. V.-P. 1891-2. P. 1895-7.)

1883 **BUXTON**, DUDLEY W., M.D., 82, Mortimer street, W.

1903 BUZZARD, EDWARD FARQUHAR, M.D., 33, Harley street, W.

1856 **BUZZARD**, THOMAS, M.D., 74, Grosvenor street, W. (C. 1869-70. V.-P. 1881-3.)

1901 CADDY, ADRIAN, M.B., 2/2, Harrington street, Calcutta.

1899 CADDY, ARNOLD, 2/2, Harington street, Calcutta.

1893 CALEY, HENRY ALBERT, M.D., 24, Upper Berkeley street, W.

1897 CALVERT, JAMES, M.D., 113, Harley street, W.

1892 CAMPBELL, HENRY JOHNSTONE, M.D., 36, Manningham lane, Bradford.

1897 **Carwardine**, THOMAS, M.S., 16, Victoria square, Clifton, Bristol.

1877 CASSON, JOHN HORNSBY, H.B.M. Legation, Teheran, Persia.

1899 CAUTLEY, EDMUND, M.D., 15, Upper Brook street, W.

1864 CAY, CHARLES VIDLER, Deputy Surgeon General. Address uncommunicated.

1869 CHAFFERS, EDWARD, Abbotsrood, Milnthorpe road, Eastbourne.

1884 CHAVASSE, THOMAS FREDERICK, M.D., C.M., 22, Temple row, Birmingham.

1901 CHEATLE, G. LENTHAL, 117, Harley Street, W.

1879 CHEYNE, WILLIAM WATSON, C.B., M.B., C.M., F.R.S., 75, Harley street, W. C. 1885-7. (M.G.C. 1890-6. V.-P. 1892-3. P. 1899—1902.)

1873 CHISHOLM, EDWIN, M.D., 44, Rosslyn gardens, Darlinghurst, near Sydney, New South Wales [care of Messrs. Dawson, 121, Cannon street, E.C.].

1865 **CHURCH**, Sir WILLIAM SELBY, Bart., K.C.B., P.R.C.P., 130, Harley street, W. (M.G.C. 1869-74. C. 1871-3. V.-P. 1894-6.)

1868 **CHURCHILL**, FREDERICK, M.D., 4, Cranley gardens, Queen's gate, S.W.

1898 CHURTON, THOMAS, M.D., 35, Park square, Leeds.

1861 **CLAPTON**, EDWARD, M.D., Towercroft, 41, Eltham road, Lee, S.E.

1872 CLARK, ANDREW, 71, Harley street, W.

1886 CLARK, FRANCIS WILLIAM, M.B., Victoria, Hong Kong.

1885 CLARKE, JOHN MICHELL, M.D., 28, Pembroke road, Clifton, Bristol.

1881 CLARKE, W. BRUCE, M.B., 51, Harley street, W. (C. 1892-4.)

1904 CLELAND, JOHN BURTON, M.D., Sydney, New South Wales [Care of South Australian Register, 80, Fleet street, E.C.].

1899 CLEVELAND, ARTHUR JOHN, M.D., 45, Shooter's Hill road, Blackheath Park, S.E.

1875 **CLUTTON**, HENRY HUGH, M.A., 2, Portland place, W. (C. 1884-6. M.G.C. 1889-94. V.-P. 1892-3.)

1865 **Coates**, CHARLES, M.D., 10, Circus, Bath.

1892 COLE, ROBERT HENRY, M.D., Moorcroft, Hillingdon, Uxbridge.

1886 COLLIER, WILLIAM, M.D., High street, Oxford.

Elected

1888 COLLINS, Sir WILLIAM JOB, M.D., M.S., 1, Albert terrace, Regent's park, N.W.

1878 COLLYNS, R. T. POOLE, Kingsley, Lingfield road, Wimbledon, S.W.

1888 COLMAN, WALTER STACY, M.D., 9, Wimpole street, W.

1882 COLQUHOUN, DANIEL, M.D., Dunedin, New Zealand.

1896 CONNELL, W. T., M.D., Kingston, Canada.

1891 COOK, HERBERT G. GRAHAM, M.D., 22, Newport road, Cardiff.

1858 COOKE, R. T. E. BARRINGTON, 15, St. Nicholas cliff, Scarborough, Yorkshire.

1866 COOMBS, ROWLAND HILL, M.D., Mill street, Bedford.

1892 COOPER, C. DUDLEY.

1903 COOPER, PERCY ROBERT, M.D., B.Sc., Glenthorne, The Downs, Bowdon, Cheshire.

1900 CORNER, EDRED MOSS, M.B., 126, Harley street, W.

1899 CORNER, HARRY, M.D., Brook House, Southgate, N.

1876 COTTLE, WYNDHAM, M.D., 39, Hertford street, W.

1861 **COUPER**, JOHN, 80, Grosvenor street, W. (C. 1870-2.)

1873 **COUPLAND**, SIDNEY, M.D., 16, Queen Anne street, W. (M.G.C. 1882-6. C. 1878-81, 1889-91. S. 1886-8. V.-P. 1892-3. T. 1894—1903.)

1897 CRAWFURD, RAYMOND H. P., M.D., 71, Harley street, W. (C. Com. Sect. A, 1902-4.)

1884 CRICHTON, GEORGE, M.D., 96, Earl's Court road, W.

1873 CRIPPS, WILLIAM HARRISON, 2, Stratford place, W. (C. 1883-5. V.-P. 1893-4.)

1877 **CROCKER**, HENRY RADCLIFFE, M.D., 121, Harley street, W. (C. 1887-9. V.-P. 1897-9.)

1886 CROOKSHANK, EDGAR, M.B., Saint Hill, East Grinstead, Sussex. (C. 1890-3. V.-P., 1900-2.)

1875 CROSS, FRANCIS RICHARDSON, 5, The Mall, Clifton, Bristol.

1889 CUFF, ROBERT, M.B., 1, The Crescent, Scarborough.

1871 CUMBERBATCH, A. ELKIN, 11, Park crescent, Portland place, W.

1893 CURTIS, HENRY JONES, M.D., 152, Harley street, W.

1884 DAKIN, W. RADFORD, M.D., B.S., 8A, Grosvenor street, Grosvenor square, W.

1883 DALTON, NORMAN, M.D., 4, Mansfield street, W. (C. Com. Sect. A, 1901-3.)

1883 DAVIS, EDWIN HARRY, West Hartlepool.

1859 **Davis**, FRANCIS WILLIAM, R.N.

1879 DAVY, HENRY, M.D., 29, Southernhay, Exeter.

1894 DAWSON, BERTRAND, M.D., 32, Wimpole street, W.

1899 DEAN, GEORGE, M.D., The Lister Institute of Preventive Medicine, Queensberry Lodge, Elstree, Herts.

1889 DEAN, HENRY PERCY, M.B., M.S., 69, Harley street, W. (C. 1900—1901.)

1899 DE CHAZAL, EDMOND LUCIEN, M.D., Port Louis, Mauritius.

1887 DELÉPINE, SHERIDAN, M.B., C.M., Owens College, Manchester. (C. 1899—1901.)

Elected

1880 Dent, Clinton T., 61, Brook street, W.

1871 Dickinson, Edward Harriman, M.A., M.D. Address uncommunicated.

1858 **DICKINSON**, William Howship, M.D., 10, Stanhope place, Marble arch, W. (C. 1866-8. S. 1869-71. V.-P. 1872-4. P. 1889-90.)

1900 Dixon, W. E., M.D., 28, Benson road, Forest Hill, S.E.

1872 Diver, Ebenezer, M.D., 7, Pittville terrace, Stanshaw road, Portsmouth.

1872 Doran, Alban Henry Griffiths, 9, Granville place, W. (C. 1882-4. V.-P. 1894-6.)

1893 Dowson, Walter, M.D., Newcome, Stanley road, Sutton, Surrey.

1877 Drake-Brockman, Edward F., 14, Welbeck street, W.

1880 Dreschfeld, Julius, M.D., 3, St. Peter's square, Manchester. (C. 1896-9.)

1893 Drysdale, John Hannah, M.D., 11, Devonshire place, W. (C. Com. Sect. A, 1904—.)

1865 **DUCKWORTH**, Sir Dyce, M.D., LL.D., 11, Grafton street, Bond street, W. (C. 1877.)

1847 **DUDGEON**, Robert E., M.D., 22, Carlton hill, St. John's Wood, N.W.

1902 Dudgeon, L. S., 6, Powis gardens, Bayswater, W.

1871 Dukes, Clement, M.D., B.S., Sunnyside, Rugby.

1877 Dunbar, J. J. MacWhirter, M.D., Hedingham House, Clapham common, S.W.

1889 Duncan, John, M.D., St. Petersburg.

1884 Dunn, Louis Albert, M.B., M.S., 51, Devonshire street, Portland place, W.

1879 Durham, Frederic, M.B., 52, Brook street, W.

1899 Eastes, George Leslie, M.B., B.Sc., 35, Gloucester terrace, W.

1901 Eastwood, A., M.D., Tuberculosis Commission, Stansted, Essex.

1893 Eccles, William McAdam, M.S., 124, Harley street, W.

1892 Eddowes, Alfred, M.D., 28, Wimpole street, W.

1880 **EDMUNDS**, Walter, M.C., 2, Devonshire place, Portland place, W. (C. 1892-4. C. Com. Sect. C, 1901-2.)

1882 Edwards, F. Swinford, 55, Harley street, W.

1889 Elam, William Henry, New Barnet, Herts.

1883 Elder, George, M.D., 17, Regent street, Nottingham.

1867 Ellis, James, M.D., Coburg street, Fratton, Portsmouth, and California.

1902 Emanuel, Joseph George, M.B., B.S., B.Sc., 47, Newhall street, Birmingham.

1902 Emery, Walter d'Este, M.D., 141, Harley street, W.

1863 Engelmann, George Julius, M.D., A.M., 336, Beacon street, Boston, Mass., U.S.A.

1875 Evans, Julian Augustus, A.M., M.D., 123, Finborough road, Radcliffe square, S.W.

1879 Eve, Frederic S., 125, Harley street, W. (M.G.C. 1884-94. C. 1885-7. V.-P. 1895-7.)

1876 Ewart, James Cossar, M.B., C.M., F.R.S., School of Medicine, Edinburgh.

Elected

1881 EWART, Sir JOSEPH, M.D., Bewcastle, Dyke road, Brighton.

1877 EWART, WILLIAM, M.D., 33, Curzon street, W. (C. 1889-91.)

1859 **Ewens**, JOHN, 17, Redland Grove, Bristol.

1887 EYLES, CHARLES HENRY, Gold Coast Colony.

1897 EYRE, JOHN W. H., M.D., The Bacteriological Laboratory, Guy's Hospital, S.E. (C. Com. Sect. B, 1904—.)

1889 FAIRBANK, FREDERICK ROYSTON, M.D., Hillside, Westcott, Dorking.

1894 FAWCETT, JOHN, M.D., 26, St. Thomas's street, S.E. (C. Com. Sect. A, 1902—.)

1872 FENN, EDWARD L., M.D., Nayland, Colchester.

1902 FENNELL, CHARLES HENRY, M.A., M.B., Tooting Bec Asylum, S.W.

1872 FENWICK, JOHN C. J., M.D., Long Framlington, Morpeth.

1892 FENWICK, W. SOLTAU, M.D., 29, Harley street, W.

1885 FÉRÉ, CHARLES, M.D., Médecin de Bicêtre; Boulevard St. Michel 37, Paris.

1897 FISHER, THEODORE, M.D., 25, Pembroke road, Clifton, Bristol.

1893 FLETCHER, H. MORLEY, M.A., M.D., B.C., 98, Harley street, W. (C. Com. Sect. A, 1903—. S. Sect. A, 1901-3.)

1872 FORBES, DANIEL MACKAY, 5, Bedford place, Croydon.

1904 FORBES, JAMES GRAHAM, M.D., 10, Bentinck street, Cavendish square, W.

1866 **Foster**, Sir BALTHAZAR WALTER, M.D., M.P., 30, Grosvenor road, Westminster.

1891 FOULERTON, ALEXANDER GRANT RUSSELL, Bacteriological Laboratory, Middlesex Hospital, W. (C. 1900—1901. C. Com. Sect. B, 1903—. S. Sect. B, 1901-3.)

1880 FOWLER, JAMES KINGSTON, M.A., M.D., 35, Clarges street, W. (C. 1887-8.)

1878 FOX, THOMAS COLCOTT, B.A., M.B., 14, Harley street, W. (C. 1892-4.)

1902 FREMLIN, H. STUART, Government Lymph Laboratory, Chelsea Bridge, S.W.

1896 FREYBERGER, LUDWIG, M.D., 41, Regent's park road, N.W. (C. Com. Sect. A, 1902-3.)

1891 FRIPP, Sir ALFRED DOWNING, C.B., M.V.O., M.S., 19, Portland place, W.

1864 FRODSHAM, JOHN MILL, M.D., Streatham, S.W.

1899 FÜRTH, KARL, M.D., 39, Harley street, W.

1894 FURNIVALL, PERCY, 28, Weymouth street, Portland place, W.

1893 FYFFE, WILLIAM KINGTON, M.B., 1, Boullcott street, Wellington, New Zealand.

1880 GABBETT, HENRY SINGER, M.D., 8, Chiswick place, Eastbourne.

1858 **Gairdner**, Sir WILLIAM TENNANT, K.C.B., M.D., LL.D.Edin., F.R.S., 32, George square, Edinburgh. (V.-P. 1891-2.)

1890 GALLOWAY, JAMES, M.A., M.D., 54, Harley street, W. (C. 1899-1902. Com. Sect. A, 1901-2.)

1870 GALTON, JOHN H., M.D., Sylvan road, Upper Norwood, S.E.

Elected

1846 GARROD, Sir ALFRED BARING, M.D., F.R.S., 10, Harley street, W. (C. 1851. V.-P. 1863-5.)

1892 GARROD, ARCHIBALD EDWARD, M.D. (HON. SECRETARY, SECT. D), 9, Chandos street, Cavendish square, W. (C. 1898—1901. S. Sect. D, 1901—.)

1879 GARSTANG, THOMAS WALTER HARROPP, Englefield, Delamer road, Bowdon, Cheshire.

1872 GARTON, WILLIAM, M.D., Inglewood, Aughton, near Ormskirk, Lancashire.

1902 GASK, G. E., M.B., 45, Weymouth street, W.

1880 GIBBES, HENEAGE, M.B., University of Michigan, Ann Arbor, Michigan, U.S.A.

1853 GIBBON, SEPTIMUS, M.D., 39, Oxford terrace, Hyde park, W.

1878 GIBBONS, ROBERT A., M.D., 29, Cadogan place, S.W.

1876 GILL, JOHN, M.D., 30, West mall, Clifton, Bristol.

1881 GLYNN, THOMAS ROBINSON, M.D., 62, Rodney street, Liverpool.

1898 GOADBY, KENNETH WELDON, 21, New Cavendish street, Portland place, W.

1873 GODLEE, RICKMAN JOHN, M.B., M.S., 19, Wimpole street, W. (M.G.C. 1875-84. C. 1877-80, 1891-2. S. 1887-9. V.-P. 1893-4, 1902—. Chairman, Sect. A.)

1878 GOLDING-BIRD, CUTHBERT H., M.B., B.S., 12, Queen Anne street, W. (C. 1885-7. V.-P. 1894-6.)

1902 GOODBODY, FRANCIS WOODCOCK, M.D., 6, Chandos street, W.

1871 GOODHART, JAMES FREDERIC, M.D., 25, Portland place, W. (M.G.C. 1874-86. C. 1876-8, 1886-8. S. 1883-5. V.-P. 1892-3.)

1894 GOSSAGE, ALFRED MILNE, M.B., B.Ch., 54, Upper Berkeley street, W.

1875 GOULD, ALFRED PEARCE, M.S., 10, Queen Anne street, W. (C. 1883-5. V.-P. 1898-1900.)

1870 GOWERS, Sir WILLIAM, M.D., F.R.S., 50, Queen Anne street, W. (C. 1878-9. V.P. 1896-7.)

1888 GRANT, J. DUNDAS, M.A., M.D., C.M., 18, Cavendish square, W.

1900 GREEN, ALAN B., M.A., M.D., B.C., 31, Cheyne court, Chelsea, S.W.

1895 GREEN, CHARLES DAVID, M.D., The Ferns, South street, Romford. (C. 1900-2. C. Com. Sect. A, 1901-2.)

1867 GREEN, T. HENRY, M.D., 74, Wimpole street, W. (M.G.C. 1869-83. C. 1871-3, 1878-9. S. 1875-6. V.-P. 1886-8.)

1873 GREENFIELD, WILLIAM SMITH, M.D., B.S., 7, Heriot row, Edinburgh. (M.G.C. 1874-81. C. 1877-80. V.-P. 1893-4.)

1886 GREVES, EDWIN HYLA, M.D., Rodney House, Suffolk road, Bournemouth.

1887 GRIFFITHS, JOSEPH, M.D., C.M., 63, Trumpington street, Cambridge.

1876 GRIFFITHS, THOMAS D., M.D., Hearne Lodge, Swansea.

1900 GRUBE, KARL, M.D., Neuenahr, Germany.

1899 GRUBER, R., M.D., 67, Wimpole street, W.

1902 GRÜNBAUM, O. F. F., M.B., B.C., 30A, Wimpole street, W.

Elected

1887 HABERSHON, SAMUEL HERBERT, M.D., 88, Harley street, W. (C. Com. Sect. A, 1902-4.)

1851 HACON, E. DENNIS, 269, Mare street, Hackney, N.E. (C. 1872.)

1892 HADLEY, WILFRED JAMES, M.D., 33, Queen Anne street, W.

1882 HAIG, ALEXANDER, M.D., 7, Brook street, W.

1899 HALL, ARTHUR J., M.B., 342, Glossop road, Sheffield.

1904 HALL, ISAAC WALTER, M.D., Owen's College, Manchester.

1901 HALLIBURTON, WILLIAM DOBINSON, M.D., F.R.S., Church Cottage, 17, Marylebone road, W. (V.-P., Chairman Sect. D., 1901—.)

1894 HALLIDIE, ANDREW HALLIDIE SMITH, M.B., 50, Noord street, Johannesburg.

1886 HAMILTON, DAVID JAMES, M.B., 41, Queen's road, Aberdeen.

1890 HANDFIELD-JONES, MONTAGU, M.D., 35, Cavendish square, W.

1886 HANDFORD, HENRY, M.D., 6, Regent street, Nottingham.

1902 HANDLEY, WILLIAM SAMPSON, M.S., M.D., 51, Devonshire street, W.

1891 HANKIN, E. H., Agra, India.

1882 HARBINSON, ALEXANDER, M.D., County Lunatic Asylum, Lancaster.

1893 HARLEY, VAUGHAN, M.D., 25, Harley street, W. (C. Com. Sect. D, 1901—.)

1901 HARMER, W. D., The Warden's House, St. Bartholomew's Hospital, E.C.

1879 HARRIS, VINCENT DORMER, M.D., Woodrouffe House, Milford-on-Sea, near Lymington, Hants.

1891 HASLAM, WILLIAM F., 54, Newhall street, Birmingham.

1904 HAWES, COLIN SADLER, Albany General Hospital, Grahamstown, South Africa.

1899 HAWKES, CLAUDE SOMERVILLE, Glencairn, Wickham terrace, Brisbane, Queensland, Australia.

1886 HAWKINS, FRANCIS HENRY, M.D., 73, London street, Reading.

1890 HAWKINS, HERBERT PENNELL, M.D., 56, Portland place, W. (C. 1898—1901.)

1856 HEATH, CHRISTOPHER, 36, Cavendish square, W. (C. 1866-7. V.-P. 1879-81.)

1900 HEATON, CHARLES, Westgate-on-Sea, Thanet, Kent.

1892 HEATON, GEORGE, M.B., B.Ch., 47, Newhall street, Birmingham.

1881 HEBB, RICHARD G., M.A., M.D., 9, Suffolk street, S.W. (M.G.C. 1891—1900. C. 1891-3. 1898—1901. S. 1896-7.)

1884 HEBBERT, CHARLES ALFRED, care of C. Baylor, 7, Water street, Boston, U.S.A.

1901 HÉDIN, SVEN GUSTAV, M.D., Jenner Institute of Preventive Medicine, Chelsea bridge, S.W. (C. Com. Sect. D, 1901-4.)

1879 HENDERSON, GEORGE COURTENAY, M.D., Kingston, Jamaica, West Indies.

1869 HENSLEY, PHILIP J., M.D., 4, Henrietta street, W.

1884 HERRINGHAM, WILMOT PARKER, M.D., 40, Wimpole street, W. (C. 1894-7.)

1892 HEWLETT, RICHARD TANNER, M.D., Bacteriological Laboratory, King's College, Strand, W.C. (C. Com. Sect. B, 1902—.)

1897 HICHENS, PEVERELL S., M.B., B.Ch., 45, Sheep street, Northampton.

1900 HILLIER, WILLIAM THOMAS, Rougemont, Beaconsfield road, St. Albans.

Elected

1903 HOBDAY, F., F.R.C.V.S., 10, Silver street, Kensington, W.

1880 HOBSON, JOHN MORRISON, M.D., Glendalough, Morland road, Croydon.

1854 **HOLMES**, TIMOTHY, 6, Sussex place, Hyde park, W. (C. 1862-3. S. 1864-7. C. 1868. V.-P. 1869-71.)

1878 HOOD, DONALD WILLIAM CHARLES, M.D., 43, Green street, Park lane. W.

1864 HOOD, WHARTON P., M.D., 11, Seymour street, W.

1903 HOPEWELL-SMITH, ARTHUR, 26, Berkeley square, Mayfair, W.

1895 HOPKINS, FREDERICK GOWLAND, M.B., New Museums, Cambridge. (C. 1899—. Com. Sect. D, 1901—.)

1900 HORDER, THOMAS J., M.D., B.Sc., 141, Harley street, W.

1897 HORNE, W. JOBSON, M.B., 27, New Cavendish street, Portland place, W.

1883 HORSLEY, Sir VICTOR, M.B., B.S., F.R.S., 25, Cavendish square, W. (C. 1888-9. V.-P. 1900-1902.)

1896 HORTON-SMITH, PERCIVAL, M.D., B.C., 19, Devonshire street, W.

1880 **HOVELL**, T. MARK, 105, Harley street, W.

1893 HOWARD, ROBERT JARED BLISS, M.D., 31, Queen Anne street, W.

1875 HOWSE, Sir HENRY GREENWAY, M.S., 59, Brook street, W (M.G.C. 1876-84. C. 1878-81.)

1856 **HUDSON**, JOHN. M.D., 11, Cork street, W.

1874 HUMPHREYS, HENRY, M.D., St. Mary Church road, Torquay.

1897 HUNT, E. L., c/o King, King, and Co., Bombay.

1897 HUNT, GEORGE B., M.D., 47, Albemarle crescent, Scarborough.

1888 HUNTER, WILLIAM, M.D., 103, Harley street, W. (C. 1897-1900.)

1852 **HUTCHINSON**, JONATHAN, F.R.S., 15, Cavendish square, W. (C. 1856-9. V.-P. 1872-3, 1881-3. P. 1879-80.)

1901 HUTCHISON, ROBERT, M.D., 22, Queen Anne street, W.

1884 HUTTON, HENRY RICHMOND, M.B., 8A, St. John street, Manchester.

1880 INGRAM, ERNEST FORTESCUE, Newcastle, Natal, S. Africa.

1886 JACKSON, ARTHUR MOLYNEUX, M.D., Kent County Asylum, Barming Heath, Maidstone.

1865 JACKSON, J. HUGHLINGS, M.D., F.R.S., 3, Manchester square, W. (C. 1872-3. V.-P. 1888-9.)

1875 JALLAND, WILLIAM HAMERTON, St. Leonard's House, Museum street, York.

1897 JAMES, GEORGE T. B., Carlisle mansions, Victoria street, S.W.

1888 JAMES, JAMES THOMAS, M.D., 30, Harley street, W.

1853 **Jardine**, JOHN LEE, The Avenue, Kew gardens, S.W.

1904 JENNINGS, JOHN FREDERICK, M.B., B.S., St. Bartholomew's Hospital, E.C.

1881 JENNINGS, WILLIAM OSCAR, M.D., 74, Avenue Marceau, Paris.

1878 JOHNSON, ARTHUR JUKES, Yorkville, Ontario, Canada.

1876 JOHNSON, CHARLES HENRY, Winton House, Basingstoke, Hants.

1901 JOHNSON, EDWARD ANGAS, M.B., B.S., St. Catharine's, Prospect, South Australia.

1888 JOHNSON, RAYMOND, M.B., B.S., 11, Wimpole street, Cavendish square, W. (C. 1896-9.)

Elected

1899 JONAS, HERBERT C., M.D., Bear street, Barnstaple.

1853 **JONES**, SYDNEY, M.B., 8A, New Cavendish street, W. (C. 1864-6. V.-P. 1886-7.)

1888 JONES, TALFOURD, M.B., St. Davids, 11, Park road, Southborough.

1862 **JONES**, THOMAS RIDGE, M.D., 4, Chesham place, S.W. (C. 1882-4.)

1898 KEEP, ARTHUR CORRIE, M.D., M.C., 14, Gloucester place, W.

1897 KELLY, CHARLES E. M., M.D., Witney, Oxon.

1901 KELYNACK, T. N., M.D., 120, Harley street, W.

1859 KIALLMARK, HENRY WALTER, 5, Pembridge gardens, W. (C. 1875-6.)

1882 KIDD, PERCY, M.D., 60, Brook street, W. (C. 1889-91.)

1852 **KINGDON**, J. ABERNETHY, 6A, Princes street, Bank, E.C.

1901 KLEIN, EDWARD EMANUEL, M.D., F.R.S., Harewood, Riverdale gardens, Twickenham Park, Twickenham. (V.-P., Chairman, Sect. B, 1901—.)

1902 KOENIG, RENÉ PAUL, M.D., 3, Rue de la Monnaie, Geneva, Switzerland.

1903 LAKIN, CHARLES ERNEST, M.B., Middlesex Hospital, W.

1878 LANCEREAUX, ETIENNE, M.D., 44, Rue de la Bienfaisance, Paris.

1882 LANE, WILLIAM ARBUTHNOT, M.B., M.S., 21, Cavendish square, W. (C. 1891-3.)

1869 LARCHER, O., M.D.Par., 97, Rue de Passy, Paris. [M. Kliensieck, Libraire, Rue de Lille 11, Paris, per Messrs. Longmans.]

1884 LARDER, HERBERT, Whitechapel Infirmary, Vallance road, N.E.

1897 LATHAM, ARTHUR C., M.D., 44, Brook street, W.

1873 LATHAM, PETER WALLWORK, M.D., 17, Trumpington street, Cambridge.

1876 LAW, WILLIAM THOMAS, M.D., 32, Weymouth street, Portland place. W.

1853 LAWRENCE, HENRY JOHN HUGHES, Picton House, Llandowror, St. Clears. (C. 1873-5.)

1892 LAWRENCE, THOMAS WILLIAM PELHAM, M.B., 12, North hill, Highgate, N. (C. Com. Sect. A, 1901-3.)

1893 LAWSON, ARNOLD, M.D., 12, Harley street, W.

1879 LAYCOCK, GEORGE LOCKWOOD, M.B., Melbourne, Victoria, Australia.

1891 LAZARUS-BARLOW, WALTER SYDNEY, M.D., Fernholme, Woodside Park, N. Finchley, N. (C. Com. Sect. C, 1901-4.)

1901 LEATHES, JOHN BERESFORD, M.B., 10, Park mansions, Battersea park, S.W. (C. Com. Sect. D, 1904—.)

1875 LEDIARD, HENRY AMBROSE, M.D., 35, Lowther street, Carlisle. (C. 1897-1900.)

1877 **LEES**, DAVID B., M.D., 22, Weymouth street, W. (C. 1890-2.)

1867 LEES, JOSEPH, M.D., 21, Brixton road, S.W.

1877 LEESON, JOHN RUDD, M.D., C.M., 6, Clifden road, Twickenham.

1868 LEGG, JOHN WICKHAM, M.D. (Travelling.) (C. 1874-5.)

1902 LEGG, THOMAS PERCY, M.B., 141, Harley street, W.

1892 LEITH, ROBERT FRASER CALDIE, M.B., C.M., B.Sc.

1892 **Leudet**, ROBERT, 72, Rue de Bellechasse, Paris, France.

1897 LISTER, THOMAS DAVID, 50, Brook street, W.

Elected

1895 LITTLE, ERNEST GRAHAM GORDON, M.D., 61, Wimpole street, W.

1889 LITTLE, JOHN FLETCHER, M.B., 32, Harley street, W.

1862 LITTLE, LOUIS S., 31, Grosvenor street, W.

1896 LITTLEWOOD, HARRY, 25, Park square, Leeds.

1874 LIVEING, EDWARD, M.D., 52, Queen Anne street, W.

1863 LIVEING, ROBERT, M.D., 11, Manchester square, W. (C. 1876.)

1881 LUBBOCK, MONTAGU, M.D., 19, Grosvenor street, W.

1897 LUCAS, ALBERT, 9, Easy row, Birmingham.

1873 LUCAS, R. CLEMENT, M.B., B.S., 50, Wimpole street, W. (C. 1883-5.)

1879 LUNN, JOHN REUBEN, St. Marylebone Infirmary; Rackham street, Ladbroke grove road, W. (C. 1897-1900.)

1887 LYON, THOMAS GLOVER, M.D., 1, Victoria square, S.W.

1904 MCDONALD, STUART, *c/o* Fairbairn, 40, Warrender park road, Edinburgh.

1893 MCFADYEAN, JOHN, M.B., Royal Veterinary College, Great College street, N.W. (C. 1899—. Com. Sect. B, 1901-4.)

1896 MACFADYEN, ALLAN, M.D., B.Sc., Lister Institute of Preventive Medicine, Chelsea gardens, S.W. (C. 1900-3. Com. Sect. B, 1901-3.)

1899 MCGAVIN, LAWRIE H., 6, Mansfield street, Cavendish square, W.

1885 MACKENZIE, HECTOR WILLIAM GAVIN, M.A., M.D., 34, Upper Brook street, Grosvenor square, W. (C. 1895-7.)

1870 MACKENZIE, JOHN T., Bombay, India.

1878 MACKENZIE, SIR STEPHEN, M.D., Merrycourt, Great Bookham, Leatherhead, Surrey. (C. 1888-90.)

1902 MACKIE, FREDERIC PERCIVAL, Agents, *c/o* Grindlay, Groom and Co., Bombay.

1865 MACLAURIN, HENRY NORMAND, M.D., 187, Macquarie street, Sydney, New South Wales.

1896 MCWEENEY, EDMOND JOSEPH, M.D., M.Ch., 84, St. Stephen's green, Dublin.

1885 MAGUIRE, ROBERT, M.D., 4, Seymour street, W.

1877 MAKINS, GEORGE HENRY, C.B., 47, Charles street, Berkeley square, W. (C. 1889-91. V.-P. 1899-1901.)

1887 MALCOLM, JOHN DAVID, M.B., C.M., 13, Portman street, W.

1892 MANN, HAROLD EDWARD, Alderney.

1890 MANSON, Sir PATRICK, K.C.M.G., M.D., C.M., F.R.S., 21, Queen Anne street, W. (C. 1900-1.)

1876 MAPLES, REGINALD, Kingsclere, near Newbury.

1904 MARRIAGE, HERBERT JAMES, M.B., B.S., 109, Harley street, W.

1868 MARSH, Prof. F. HOWARD, 14, Hertford street, Mayfair, W. (C. 1876-7.) (V.-P 1889-90.)

1904 MARTIN, CHARLES J., M.B., D.Sc., F.R.S., Lister Institute of Preventive Medicine, Chelsea gardens, S.W. (C. Com. Sect. C, 1904—.)

1904 MARTIN, ERNEST WILLIAM, M.B., Ch.B., 3, Hamlet road, Upper Norwood, S.E.

1887 MARTIN, SIDNEY, M.D., B.S., F.R.S., 10, Mansfield street, W. (C. 1893-6. V.-P. 1900-1902.)

Elected

1889 MASON, DAVID JAMES, M.D., Rosemont, Maidenhead.

1898 MASTERMAN, ERNEST WILLIAM GURNEY, Surgeon, English Mission Hospital, Jerusalem, Syria.

1892 MASTERS, JOHN ALFRED, M.D., 94, Knightsbridge, S.W.

1884 MAUDSLEY, HENRY CARE, M.D., 11, Spring street, Melbourne, Victoria.

1902 MAVRAGORDATO, ANTHONY, 8, Ladbroke gardens, W.

1897 MAXWELL, J. P., c/o E.P. Mission, Eng Chhun, Amoy, China.

1900 MAXWELL, JAMES LAIDLAW, M.D., E.P. Mission, Yai-nan-fu, Formosa, *viâ* Hong Kong.

1852 MAY, GEORGE, M.B., Reading.

1888 MAY, WILLIAM PAGE, M.D., B.Sc., 9, Manchester square, W., and Helouan, near Cairo, Egypt (November to April).

1881 MAYLARD, ALFRED ERNEST, M.B., 4, Berkeley terrace, Glasgow.

1874 MEREDITH, WILLIAM APPLETON, C.M., 21, Manchester square, W.

1894 MICHELS, ERNST, M.D., 48, Finsbury square, E.C.

1900 MILBURN, LESLIE, Hollywood House, Wimbledon common, S.W.

1882 MONEY, ANGEL, M.D., Hunter street, Sydney, New South Wales.

1901 MOORE, ALFRED, Reculver Villa, Cheam road, Sutton, Surrey.

1899 MOORE, FREDERICK CRAVEN, M.D., The Priory, Ardwick Green, Manchester.

1879 MOORE, NORMAN, M.D., 94, Gloucester place, Portman square, W. (C. 1885-7. M.G.C. 1889-1900. V.-P. 1895-7.)

1875 MORGAN, JOHN H., C.V.O., 68, Grosvenor street, W. (C. 1886-8.)

1874 MORISON, ALEXANDER, M.D., C.M., 14, Upper Berkeley street, W.

1869 MORRIS, HENRY, M.A., M.B. (TRUSTEE), 8, Cavendish square, W. (C. 1877-9, 1884-6. S. 1881-3. V.-P. 1888-9.)

1879 MORRIS, MALCOLM ALEXANDER, 8, Harley street, W.

1894 MORRICE, GEORGE GAVIN, M.D., Holy Trinity Vicarage, Weymouth.

1891 MORTON, CHARLES A., 14, Vyvyan terrace, Clifton, Bristol.

1875 MORTON, JOHN, M.B., Guildford.

1884 MOTT, FREDERICK WALKER, M.D., F.R.S., 25, Nottingham place, W. (C. 1891-3. V.-P. 1899-1901.)

1900 MUIR, ROBERT, M.D., 4, Alfred terrace, Glasgow.

1893 MUMMERY, JOHN HOWARD, 10, Cavendish place, W.

1899 MURRAY, GEORGE R., M.D., 11, Ellison place, Newcastle-on-Tyne.

1885 MURRAY, HUBERT MONTAGUE, M.D., 25, Manchester square, W. (C. 1896-9.)

1894 MURRAY, JOHN, M.B., B.Ch., 110, Harley street, W.

1901 NABARRO, DAVID, M.D., B.Sc., D.P.H., 6, Crown Office Row, Inner Temple, E.C.

1887 NASON, EDWARD NOEL, M.D., 80, Abbey street, Nuneaton.

1904 NEAVE, SHEFFIELD, Mill Green park, Ingatestone, Essex.

1875 NEWBY, CHARLES HENRY, 63, Victoria road North, Southsea, Hants.

1902 NEWLAND, THOMAS SIMPSON, M.B., Ch.B., North terrace, Adelaide, S. Australia.

1884 NEWLAND-PEDLEY, FREDERICK, 32, Devonshire place, Portland place, W.

1865 NEWMAN, WILLIAM, M.D., Stamford, Lincolnshire.

Elected

1895 NIAS, J. BALDWIN, M.D., 5, Rosary gardens, S. Kensington, S.W.
1868 NICHOLLS, JAMES, M.D., Trekenning House, St. Columb, Cornwall.
1876 NICHOLSON, FRANK, M.D., 29, Albion street, Hull.
1864 NORTON, ARTHUR T., C.B., Leyfields Wood, Ashampstead, Berks. (C. 1877-9.)
1883 NORVILL, FREDERIC HARVEY, M.B., Dibrooghur, India.

1880 O'CONNOR, BERNARD, M.D., 25, Hamilton road, Ealing.
1873 O'FARRELL, Sir GEORGE PLUNKETT, M.D., 19, Fitzwilliam square, Dublin.
1894 OGLE, CYRIL, M.B., 96, Gloucester place, W. (C. 1899-1901.)
1888 OPENSHAW, THOMAS HORROCKS, C.M.G., M.S., 16, Wimpole street, W.
1892 ORD, WILLIAM WALLIS, M.D., The Hall, Salisbury.
1879 ORMEROD, JOSEPH A., M.D., 25, Upper Wimpole street, W. (C. 1887-9.)
1875 OSBORN, SAMUEL, Maisonnette, Datchet, Bucks.
1865 OWLES, JAMES ALLDEN, M.D., Hill View, Woking, Surrey.

1884 PAGET, STEPHEN, 70, Harley street, W. (C. 1894-7.)
1895 PAKES, WALTER CHARLES, Government Laboratory, Pretoria, South Africa. (C. Com. Sect. B, 1901-2.)
1897 PARFITT, CHARLES D., M.D., London, Canada.
1898 PARKER, ARTHUR PERCY, M.B., B.Ch., 27, Beaumont street, Oxford.
1874 PARKER, RUSHTON, M.B., B.S., 59, Rodney street, Liverpool.
1853 PARKINSON, GEORGE, Orchard Dene, Henley-on-Thames.
1901 PARSONS, JOHN HERBERT, M.B., B.S., B.Sc., 28, Great Ormond street, W.C.
1882 PASTEUR, WILLIAM, M.D., 4, Chandos street, W. (C. 1893-6.)
1885 PAUL, FRANK THOMAS, 38, Rodney street, Liverpool.
1865 PAVY, FREDERICK WILLIAM, M.D., LL.D., F.R.S., 35, Grosvenor street, W. (C. 1872-4. V.-P. 1891-2. V.-P., Chairman Sect. C, 1901—. P. 1893-4.)
1868 PAYNE, JOSEPH FRANK, M.D. (TRUSTEE), 78, Wimpole street, W. (M.G.C. 1872-85. C. 1873-5, 1883-5. S. 1880-2. V.-P. 1888-9. V.-P., Chairman Sect. A, 1901-2. P. 1897-8.)
1872 PEARCE, JOSEPH CHANING, M.D., C.M., Montague House, St. Lawrence-on-Sea, Kent.
1879 PEEL, ROBERT, 130, Collins street East, Melbourne, Victoria.
1899 PEMBREY, MARCUS SEYMOUR, M.D., B.Ch., Guy's Hospital, S.E. (C. Com. Sect. C, 1904—.)
1889 PENBERTHY, JOHN, Royal Veterinary College, Camden Town, N.W.
1887 PENROSE, FRANCIS GEORGE, M.D., 84, Wimpole street, W.
1884 PEPPER, AUGUSTUS JOSEPH, M.B., C.M., 13, Wimpole street, W.
1900 PERKINS, JOSEPH JOHN, M.B., 41, Wimpole street, Cavendish square, W.
1899 PERNET, GEORGE, 152, Harley street, W.
1888 PERRY, Sir EDWIN COOPER, M.D., Superintendent's House, Guy's Hospital, S.E.

Elected

1902 PHEAR, ARTHUR G., M.D., 47, Weymouth street, W.

1878 PHILIPPS, SUTHERLAND REES, M.D., St. Ann's heath, Virginia Water, Chertsey.

1878 PHILLIPS, JOHN WALTER, 30, Stanley street West, Melbourne, Victoria.

1893 PINKERTON, ROBERT A., M.A., M.D., 15, South Norwood hill, S.E.

1884 PITT, GEORGE NEWTON, M.D., 15, Portland place, W. (M.G.C. 1889-97. C. 1890-2, 1896-9. S. 1894-6. V.-P. 1899-1901.)

1876 PITTS, BERNARD, M.A., M.C., 109, Harley street, W. (C. 1888-90.)

1899 PLIMMER, HENRY GEORGE, 16, Cheyne walk, Chelsea, S.W. (C. Com. Sect. B, 1901-3.)

1883 POLAND, JOHN, 2, Mansfield street, Cavendish square, W.

1882 POLLARD, BILTON, M.B., B.S., 24, Harley street, W. (C. 1895-7.)

1850 POLLOCK, JAMES EDWARD, M.D., 37, Collingham place, W. (C. 1862-4. V.-P. 1879-81.)

1879 POTTER, HENRY PERCY, M.D., St. Mary Abbotts Infirmary, Marloes road, Kensington, W.

1866 POWELL, Sir RICHARD DOUGLAS, Bart., K.C.V.O., M.D., 62, Wimpole street, W. (C. 1873-5, 1881-3. S. 1877-9. V.-P. 1887-8.)

1884 POWER, D'ARCY, M.A., M.B., 10A, Chandos street, W. (C. 1891-3. 1899-1902. Com. Sect. A, 1901-2. M.G.C. 1897-1900. S. 1897-9.)

1865 POWER, HENRY, Bagdale Hall, Whitby. (C. 1876-7.)

1900 POYNTON, FREDERICK JOHN, M.D., 19, Portman street, W.

1887 PRATT, WILLIAM SUTTON, M.D., Penrhos House, Rugby.

1902 PRICE, F. W., M.B., 77, Wimpole street, W.

1884 PRICE, JOHN A. P., M.D., 124, Castle street, Reading.

1900 PRICE-JONES, CECIL, M.B., 7, Claremont road, Surbiton, Surrey.

1888 PRIMROSE, ALEXANDER, M.B., C.M., 100, College street, Toronto, Canada.

1895 PURVIS, WILLIAM PRIOR, M.D., 2, Avenue place, Southampton.

1865 PYE-SMITH, PHILIP HENRY, M.D., F.R.S. (TREASURER), 48, Brook street, W. (C. 1874-7. V.-P. 1890-1. T. 1903—.)

1897 RANKIN, GUTHRIE, M.D., 4, Chesham street, S.W.

1890 Ransom, WILLIAM BRAMWELL, M.D., The Pavement, Nottingham.

1891 RATCLIFFE, JOSEPH RILEY, M.B., C.M., Wake green, Moseley.

1887 RAVEN, THOMAS FRANCIS, Broadstairs, Kent.

1870 RAY, EDWARD REYNOLDS, 15A, Upper Brook street, W.

1875 REID, ROBERT WILLIAM, M.D., C.M., 8, Queen's gardens, Aberdeen,

1901 REID, ST. GEORGE CAULFIELD, Brigstock House, Thornton Heath, Surrey.

1901 REISSMANN, CHARLES, M.B., St. Peter's, College Town, Adelaide, S. Australia.

1881 RENNER, WILLIAM, Wilberforce street, Free Town, Sierra Leóne.

1893 RENNIE, GEORGE EDWARD, M.D., College street, Hyde park, Sydney, N.S.W.

1895 RITCHIE, JAMES, M.D., 28, Beaumont street, Oxford. (C. Com. Sect. B, 1903—.)

1901 RIVIERE, CLIVE, M.D., 19, Devonshire street, W.

1865 Roberts, DAVID LLOYD, M.D., 11, St. John's street, Manchester.

1871 ROBERTS, FREDERICK THOMAS, M.D., 102, Harley street, W. (C. 1883-5.)

Elected

1878 ROBERTS, WILLIAM HOWLAND, M.D., Surgeon, Madras Army.

1888 ROBERTSON, ROBERT, M.D., The Bungalow, Ventnor, Isle of Wight.

1885 ROBINSON, ARTHUR HENRY, M.D., St. Mary's Infirmary, Highgate hill, N.

1882 ROBINSON, TOM, M.D., 9, Princes street, Cavendish square, W.

1904 ROBSON, A. W. MAYO, 8, Park crescent, Portland place, W.

1888 ROLLESTON, HUMPHRY DAVY, M.A., M.D. 55, Upper Brook street, Grosvenor square, W. (C. 1894-7. 1900-1902. Com. Sect. A, 1901-2. M.G.C. 1895-1900. S. 1898-1900.)

1904 ROSE, FRANK ATCHERLEY, M.B., 42, Devonshire street, Portland place, W.

1858 ROSE, HENRY COOPER, M.D., 16, Warwick road, Maida hill, N.W. (C. 1873-4.)

1875 ROSSITER, GEORGE FREDERICK, M.B., Cairo Lodge, Weston-super-Mare.

1877 ROTH, BERNARD, 38, Harley street, W., and "Wayside," 1, Preston park avenue, Brighton.

1888 ROUGHTON, EDMUND WILKINSON, M.D., 38, Queen Anne street, W.

1891 ROUILLARD, LAURENT ANTOINE JOHN, M.B., Durban, Natal.

1901 ROWLAND, SYDNEY, M.A., Jenner Institute of Preventive Medicine, S.W.

1899 ROWLANDS, ROBERT P., Guy's Hospital, S.E.

1891 RÜFFER, MARC ARMAND, M.D., The Quarantine Board, Alexandria.

1897 RUNDLE, HENRY, 13, Clarance parade, Southsea.

1900 RUSSELL, A. E., M.D., 9, Wimpole street, Cavendish square, W.

1895 RUSSELL, JAMES SAMUEL RISIEN, M.D., 44, Wimpole street, Cavendish square, W.

1891 RUSSELL, WILLIAM, M.D., 3, Walker street, Edinburgh.

1903 SALAMAN, RADCLIFFE N., M.B., Frognal End, Frognal gardens, Hampstead, N.W.

1854 SANDERSON, Sir JOHN BURDON, Bart., M.D., D.C.L., F.R.S. (PRESIDENT), 64, Banbury road, Oxford. (P. 1902—. M.G.C. 1869-76. C. 1864-7. V.-P. 1873-4.)

1897 SANTI, PHILIP R. W. DE, 15, Stratford place, W.

1902 SARGENT, PERCY WILLIAM GEORGE, M.B., B.C., St. Thomas's Hospital, S.E.

1886 SAUNDBY, ROBERT, M.D., 140B, Great Charles street, Birmingham.

1871 SAUNDERS, CHARLES EDWARD, M.D., Sussex County Lunatic Asylum, Haywards Heath.

1901 SAUNDERS, E. A., M.B., 49, Harley street, W.

1890 SAUNDERS, FREDERICK WILLIAM, M.B., B.C., Chieveley House, Newbury.

1873 SAVAGE, GEORGE HENRY, M.D., 3, Henrietta street, Cavendish square, W. (C. 1881-3.)

1882 SAVILL, THOMAS DIXON, M.D., 60, Upper Berkeley street, W.

1902 SCHÖLBERG, H. A., M.B., University College of South Wales and Monmouthshire, Cardiff.

1891 SCHORSTEIN, GUSTAVE ISIDORE, M.B., B.Ch., 11, Portland place, W.

1901 SCOTT, Hon. G. H., M.B., B.C., Mertoun House, St. Boswells, N.B.

Elected

1902 SCOTT, S. G., M.A., M.B., Yorkshire College, Department of Medicine, Thoresby place, Leeds.

1899 SELIGMANN, CHARLES G., M.B., c/o H. C. Jones, M.D., Bear street, Barnstaple.

1903 SELOUS, C. F., M.B., St. Thomas's Hospital, Albert Embankment, S.E.

1877 SEMON, Sir FELIX, C.V.O., M.D., 39, Wimpole street, W. (C. 1885-7.)

1894 SEQUEIRA, JAMES HARRY, M.D., 63, Harley street, Cavendish square, W.

1872 SERGEANT, EDWARD, D.P.H., Lancashire County Council, Public Health Department, County Offices, Preston.

1876 SHARKEY, SEYMOUR J., M.D., 22, Harley street. W. (M.G.C. 1884-1895. C. 1884-6. V.-P. 1895-7.)

1880 SHATTOCK, SAMUEL G. (HON. GENERAL SECRETARY), 4, Crescent road, The Downs, Wimbledon, S.W. (M.G.C. 1884-1900. C. 1885-7, 1893-6. S. 1890-2, 1902—. V.-P. 1896-8. E. 1900—.)

1898 SHAW, HAROLD BATTY, M.D., 7, Devonshire street, W. (C. Com. Sect. A, 1903—.)

1885 SHAW, LAURISTON ELGIE, M.D., 64, Harley street. W.

1886 **SHERRINGTON**, CHARLES SCOTT, M.D., F.R.S., University College, Liverpool. (C. 1894-7.)

1856 **SHILLITOE**, BUXTON, 2, Frederick's place, E.C.

1875 SIDDALL, JOSEPH BOWER, M.D., C.M., Conybeare, Northam, Bideford.

1880 SILCOCK, A. QUARRY, M.D., B.S., 52, Harley street, W. (C. 1888-90.)

1901 SINGER, HAROLD DOUGLAS, M.D., McCagne Buildings, Omaha, Neb., U.S.A.

1892 SLATER, CHARLES, M.B., St. George's Hospital, S.W.

1887 SMALLPEICE, WILLIAM DONALD, 10, Chester square, S.W.

1879 SMITH, E. NOBLE, 24, Queen Anne street, W.

1887 **SMITH**, FREDERICK JOHN, M.D., 138, Harley street, W.

1894 SMITH, GUY BELLINGHAM, M.B., B.S., 24, St. Thomas's street, S.E.

1900 SMITH, J. LORRAIN, M.D., The Medical School, Leeds.

1873 SMITH, RICHARD T., M.D., 117, Haverstock hill, N.W.

1883 SMITH, ROBERT PERCY, M.D., 36, Queen Anne street, W.

1869 SMITH, ROBERT SHINGLETON, M.D., Deepholm, Clifton Park, Bristol.

1866 SMITH, WILLIAM, Melbourne, Australia.

1870 SNOW, WILLIAM VICARY, M.D., Richmond Gardens, Bournemouth.

1888 SOLLY, ERNEST, M.B., Strathlea, Harrogate, Yorks.

1887 SPENCER, WALTER GEORGE, M.S., 35, Brook street, W. (M.G.C. 1894-1900. C. 1896-9.)

1899 SPRIGGS, EDMUND IVENS, M.D., 24, St. Thomas's street, S.E.

1861 SQUIRE, ALEXANDER BALMANNO, M.B., 24, Weymouth street, W.

1890 STABB, EWEN CARTHEW, 57, Queen Anne street, W.

1901 STAINER, E., M.B., 60, Wimpole street, W.

1895 STARLING, ERNEST HENRY, M.D., F.R.S., 8, Park square West, Regent's Park, N.W. (C. Com. Sect. C, 1901—.)

1896 STEPHENS, J. W. W., M.D. Address uncommunicated.

1899 STEWARD, FRANCIS J., M.S., 24, St. Thomas's street, S.E.

1900 STEWART, PURVES, M.D., 7, Harley street, W.

1891 STILES, HAROLD JALLAND, M.B., C.M., 5, Castle terrace, Edinburgh.

Elected

1897 STILL, GEORGE F., M.D. (HON. SECRETARY, SECT. A), 114, Harley street, W. (C. Com. Sect. A, 1901-3. Sec. Sect. A, 1903—.)

1879 STIRLING, EDWARD CHARLES, C.M.G., M.D., F.R.S., Adelaide, South Australia [care of Messrs. Elder & Co., 7, St. Helen's place, E.C.].

1884 STONHAM, CHARLES, 4, Harley street, W. (C. 1893-6.)

1896 STRANGEWAYS, T. P., St. John's College, Cambridge.

1902 STRICKLAND-GOODALL, J., M.D., 30, Vanbrugh hill, Blackheath, S.E.

1903 STRONG, WALTER M., "Helstonleigh," Champion park, Denmark hill, S.E.

1875 STURGE, W. A., M.D., 29, Boulevard Dubouchage, Nice.

1867 SWAIN, WILLIAM PAUL, 17, The Crescent, Plymouth.

1881 SYMONDS, CHARTERS JAMES, M.S., 58, Portland place, W. (M.G.C. 1884-91. C. 1886-8. V.-P. 1899-1901.)

1886 TARGETT, JAMES HENRY, M.B., M.S., 19, Upper Wimpole street, W. (M.G.C. 1894-1900. C. 1894-5, 1897-1900. V.-P. 1900-1902. S. 1895-7.)

1870 TAY, WAREN, 4, Finsbury square, E.C. (C. 1881-2.)

1871 **TAYLOR**, FREDERICK, M.D., 20, Wimpole street, W. (M.G.C. 1879-89. C. 1879-81. V.-P. 1897-9.)

1885 TAYLOR, HENRY H., 10, Brunswick place, Hove, Sussex.

1892 TAYLOR, JAMES, M.D., 49, Welbeck street, W.

1902 THIELE, FRANCIS HUGO, M.D., 7, Hampstead lane, Highgate, N.

1891 THOMSON, HENRY ALEXIS, M.D., 39, Drumsheugh gardens, Edinburgh.

1884 THOMSON, JOHN, M.D., C.M., 14, Coates crescent, Edinburgh.

1901 THOMSON-WALKER, J. W., M.B., 8, Cavendish place, W.

1892 **Thorburn**, WILLIAM, B.S., 2, St. Peter's square, and Rusholme Lodge, Rusholme, Manchester.

1872 THORNTON, WILLIAM PUGIN, 35, St. George's place, Canterbury.

1900 THURSFIELD, HUGH, M.D., 45, Weymouth street, W.

1880 TIRARD, NESTOR ISIDORE, M.D., 74, Harley street, W.

1884 TIVY, WILLIAM JAMES, 8, Lansdowne place, Clifton, Bristol.

1901 TODD, CHARLES, M.D., Queensberry Lodge, Elstice, Herts.

1897 TOOGOOD, F. SHERMAN, M.D., The Infirmary, 282, High street, Lewisham, S.E.

1882 TOOTH, HOWARD HENRY, C.M.G., M.D., 34, Harley street, W. (C. 1892-4. M.G.C. 1895-1900.)

1886 TOTSUKA, KANKAI, Tokio, Japan.

1872 **TOWNSEND**, THOMAS SUTTON, 68, Queen's gate, S.W.

1899 TREDGOLD, ALFRED F., London County Asylum, Woodford Bridge, Essex.

1888 TREVELYAN, EDMOND F., M.D., 40, Park square, Leeds.

1902 TREVOR, ROBERT SALUSBURY, M.B., 21, Fitzgeorge avenue, West Kensington, W.

1903 TRITSCH, ISIDOR, Lawn House, Hampstead Heath, N.W.

1851 TROTTER, JOHN W., 4, St. Peter's terrace, York. (C. 1865-9.)

1904 TROTTER, WILFRED BATTEN LEWIS, M.S., 49, Park avenue, Willesden green, N.W.

1895 TROUTBECK, HENRY, M.B., B.C., 151, Ashley gardens, S.W.

Elected

1859 **TRUMAN**, Edwin Thomas, 23, Old Burlington street, W.
1888 Tubby, Alfred Herbert, M.S., 25, Weymouth street, Portland place, W.
1867 Tuckwell, Henry Matthews, M.D., 64, High street, Oxford.
1858 Tudor, John, Dorchester, Dorset.
1863 Turner, James Smith, 12, George street, Hanover square, W.
1893 Turney, Horace George, M.D., M.Ch., 68, Portland place, W.
1858 **TURTLE**, Frederick, M.D., Kirkmead, Woodford, Essex.
1880 Tyson, William Joseph, M.D., 10, Langhorne gardens, Folkestone.

1867 Venning, Edgcombe, 30, Cadogan place, S.W.
1889 Voelcker, Arthur Francis, M.D., B.S., 101, Harley street, W. (C. 1895-7.)

1867 **WAGSTAFFE**, William Warwick, B.A., Purleigh, St. John's hill, Sevenoaks. (C. 1874, 1878-80. M.G.C. 1874-82. S. 1875-7.)
1885 Wakley, Thomas, jun., 16, Hyde park gate, S.W.
1902 Walker, E. W. Ainley, M.D., University College, Oxford.
1893 Walker, Norman Purvis, M.D., 7, Manor place, Edinburgh.
1901 Wallace, Cuthbert Sidney, 26, Upper Wimpole street, W.
1881 Waller, Bryan Charles, M.D., Masongill House, Cowan bridge, Kirkby-Lonsdale.
1890 Wallis, Frederick Charles, M.B., B.C., 107, Harley street, W. (C. 1898-1901.)
1888 Walsham, Hugh, M.A., M.D., B.C., 114, Harley street, W.
1859 Walters, John, M.B., Reigate, Surrey.
1892 Ward, Allan Ogier, M.D.Edin., 73, Cheapside, E.C.
1903 Ward, Edward, M.B., B.C., 21, Park place, Leeds.
1892 Waring, Holbert Jacob, M.B., M.S., 37, Wimpole street, W.
1901 Warner, Allan, M.D., Isolation Hospital, Leicester.
1891 Waterhouse, Herbert Furnivall, M.D., C.M., 81, Wimpole street, W.
1903 Waters, W. A. P., M.D., 99, Holywell, Oxford.
1890 Webb, Charles Frere, M.D., New street House, Basingstoke.
1894 **WEBER**, Frederick Parkes, M.D., 19, Harley street, W.
1858 **WEBER**, Sir Hermann, M.D., 10, Grosvenor street, W. (C. 1867-70. V.-P. 1878-80.)
1864 Welch, Thomas Davies, M.D. (Travelling).
1894 Wells, Sydney Russell, M.D., 24, Somerset street, Portman square, W.
1892 Wesbrook, Frank F., M.D., The University of Minnesota, Minneapolis, U.S.A.
1877 West, Samuel, M.D., 15, Wimpole street, W. (C.1884-6, 1891-3. S. 1889-90. V.-P. 1896-7.)
1891 Wheaton, Samuel Walton, M.D., 10, Restall avenue, Streatham hill, S.W.
1869 Whipple, John H. C., M.D., Royal Army Medical Corps.
1877 White, Charles Haydon, 4, East Circus street, Park row, Nottingham.

Elected

1894 WHITE, CHARLES POWELL, M.B., Pathological Laboratory, St. Thomas's Hospital, Albert Embankment, S.E. (C. Com. Sect. A, 1903—.)

1891 WHITE, GILBERT B. MOWER, M.B., B.S., 112, Harley street, W.

1881 WHITE, WILLIAM HALE, M.D., 65, Harley street, W. (C. 1888-90.)

1886 WHITE, WILLIAM HENRY, M.D., 43, Weymouth street, W.

1868 **Whitehead**, WALTER, 17, Market street, Manchester.

1897 WHITFIELD, ARTHUR, M.D., 21, Bentinck street, Manchester square, W.

1869 WILKIN, JOHN F., M.D., M.C., Rose Ash House, South Molton, N. Devon.

1871 WILKINSON, J. SEBASTIAN. Address uncommunicated.

1879 WILLCOCKS, FREDERICK, M.D., 14, Mandeville place, W.

1869 WILLIAMS, ALBERT, M.D. (Travelling).

1858 **Williams**, CHARLES, 48, Prince of Wales road, Norwich.

1866 WILLIAMS, CHARLES THEODORE, M.D., 2, Upper Brook street, W. (C. 1875-8.)

1881 WILLIAMS, DAWSON, M.D., B.S., 2, Agar street, Strand, W.C. (C. 1893-6.)

1881 WILLIAMS, W. ROGER, Beaufort House, Clifton Down, Clifton.

1900 WILLIAMSON, OLIVER K., M.B., B.C., 55, Upper Berkeley street, W.

1863 WILLIS, FRANCIS, M.D., Asheville, N. Carolina, U.S.A.

1889 WILSON, ALBERT, M.D., 1, Belsize park, N.W.

1888 WILSON, CLAUDE, M.D., C.M., Church road, Tunbridge Wells.

1859 WILSON, EDWARD THOMAS, M.B., Montpelier terrace, Cheltenham.

1891 WILSON, THEODORE STACEY, M.D., C.M., 27, Wheeley's road, Edgbaston, Birmingham.

1861 **Windsor**, THOMAS, Medical Library, Boston, Mass., U.S.A. [care of B. F. Stevens and Brown, 4, Trafalgar square, W.].

1889 WINGRAVE, V. HAROLD WYATT, 11, Devonshire street, Portland place, W.

1874 WISEMAN, JOHN GREAVES, Stranraer, St. Peter's Road, St. Margaret's-on-Thames.

1883 WOODCOCK, JOHN ROSTRON, Darlington Court, North road, Bath.

1883 WOODHEAD, GERMAN SIMS, M.D., 6, Scrope terrace, Cambridge. (C. 1891-3. V.-P. 1898—1900. M.G.C. 1899—1900.)

1879 WOODWARD, G. P. M., M.D., Deputy Surgeon General; Sydney, New South Wales.

1884 WORTS, EDWIN, 6, Trinity street, Colchester.

1903 WRIGHT, ALMROTH EDWARD, M.D., 7, Lower Seymour street, Portman square, W. (C. Com. Sect. B, 1903—.)

1890 WYNNE, EDWARD T., M.B., Gladstone, Queensland.

1884 WYNTER, WALTER ESSEX, M.D., 30, Upper Berkeley street, W.

1872 YOUNG, HENRY, M.B., Monte Video, South America.

1901 YOUNG, HENRY WILLIAM PENNEFATHER, "Dursley," Norbury, S.W.

ANNUAL REPORT OF COUNCIL,

1903–4.

PRESENTED AT THE ANNUAL MEETING, MAY 17TH, 1904

YOUR Council have to report that during the present session twenty-one new members have been admitted to the Society, that thirteen members have resigned, and that there have been ten losses by death.

The death-roll includes Dr. E. L. Birkett, Dr. A. Brown, Dr. A. Davidson, Mr. T. R. Jessop, Dr. R. King, Sir William Kynsey, Mr. G. Lawson, Mr. P. B. Mason, Sir Henry Thompson (formerly one of the vice-presidents), Mr. J. K. Thornton.

The total number of members is now 681, of whom 255 are non-resident.

The "Laboratory" meetings have been held at King's College, the Lister Institute, the Royal Army Medical College, and the Medical School of Guy's Hospital. To the Pathological Directors of these institutions the Council offers its best thanks.

In July, 1903, an out-of-London meeting was held, on the President's invitation, at the Laboratories, Oxford. A large number of members availed themselves of the invitation, the meeting being in every way a notable success.

REPORT OF THE TREASURER.

Members of the Society will remember that last year above £158 was expended on the General Index of Volumes XXXVIII to L. It is fortunate that this year we have no such extra-

ordinary payments to meet, and are therefore able to maintain the somewhat shrunken capital of the Society without further diminution.

Nevertheless, we are left at the close of the present financial year with a balance against us at our Bank of £125 2*s*. 5*d*.

Three years ago, in 1901, the subscriptions were 360 and the entrance fees 19. In 1902 we received 329 subscriptions and 32 entrance fees. Last year the numbers were 378 subscriptions and 24 entrance fees. This year they are 350 subscriptions and 22 entrance fees. There is therefore no progressive or serious diminution of our numbers, but they have not increased as they should.

The sale of our 'Transactions' was about the same as last year—about £49 compared with nearly £50.

But the dividends on our invested capital have fallen from £28 17*s*. 0*d*. to £20 7*s*. 8*d*.

On the other side of the balance-sheet, the expense of our meetings this year was more than in 1892-3, viz. £132 9*s*. 6*d*., instead of £120 9*s*. 6*d*.

It is clear that measures must be taken to increase our income or to diminish our expenses, or both.

The intrinsic value of our 'Transactions' is certainly not diminished, and the beauty and finish of the engravings have increased. But we need either a considerable increase of our numbers or a considerable diminution of our expenditure. There are several ways of attaining the latter which are engaging the anxious consideration of the Council. The former object can only be attained by the active help of all our members in securing a large accession to our numbers.

The total income of the Society during the past year has been £468 16*s*. 1*d*., the total expenditure £593 18*s*. 6*d*., leaving a deficit of £125 2*s*. 5*d*.

The amount of Stock now held by the Society in Consols is £854 6*s*. 3*d*.

Statement of Income and Expenditure for the last Two Years.

1902—1903.

Income.	£	s.	d.
Subscriptions	393	15	0
Entrance Fees and Composition Fees	40	19	0
'Transactions'	40	19	5
Agenda Fees	1	2	6
Dividends	23	13	11
	£500	9	10

Expenditure.	£	s.	d.
Meetings	120	9	6
'Transactions'	386	6	8
Secretariat and Treasury	61	8	3
Subscription to Virchow Memorial Fund	10	10	0
Power of Attorney	0	11	6
Bank Charges	0	13	9
Petty Cash	7	5	11
	£587	5	7

1903—1904.

Income.	£	s.	d.
Subscriptions	367	10	0
Entrance Fees and Composition Fees	28	7	0
'Transactions'	52	1	2
Agenda Fees	0	10	0
Dividends	20	7	8
	£468	15	10

Expenditure.	£	s.	d.
Meetings	132	9	6
'Transactions'	313	13	6
Secretariat and Treasury	67	11	6
Bank Charges	1	15	9
Petty Cash	6	18	1
	£522	8	4

THE PATHOLOGICAL SOCIETY OF LONDON.

Statement of Receipts and Payments from 16th May, 1902, to 13th May, 1904.

RECEIPTS.

	£	s.	d.	£	s.	d.
Petty Cash in hand, 16th May, 1903				0	0	3
350 Subscriptions at £1 1*s.*				367	10	0
22 Entrance Fees at £1 1*s.*	23	2	0			
1 Life Composition Fee	5	5	0			
				28	7	0
Transactions—						
Sale of 'Transactions'	48	18	2			
Contribution towards Plate	3	3	0			
				52	1	2
4 Fees for Agenda Notices at 2*s.* 6*d.*				0	10	0
Dividends on Consols				20	7	8
				468	16	1
Balance due to Bank				125	2	5
				£593	18	6

PAYMENTS.

	£	s.	d.	£	s.	d.
Balance due to Bank—16th May, 1903				69	3	0
Meetings:						
Rent of Rooms	73	10	0			
Refreshments and Attendance at Meetings	23	8	6			
Microscopes	29	6	0			
Epidiascope	5	4	0			
Reporting Meeting	1	1	0			
				132	9	6
'Transactions':						
Printing, Binding, etc., for Vol. LIV	215	3	8			
Illustrations " "	84	11	10			
Illustrations for Vol. LV "	13	18	0			
				313	13	6
Secretarial and Treasury:						
General Printing and Stationery	28	16	6			
Council Notices	2	0	0			
Secretarial Assistance	15	15	0			
Collection of Subscriptions	15	15	0			
Mr. Clarke's Fee	5	5	0			
				67	11	6
Bank Charges				1	15	9
Petty Cash Expenditure				6	18	1
				591	11	4
Petty Cash in hand				2	7	2
				£593	18	6

Audited and approved, 16th May, 1904.

SIDNEY COUPLAND, M.D., *Treasurer.*
S. G. SHATTOCK, *Hon. Secretary.*

S. N. BRUCE, LOUIS JENNER, } *Auditors.*

LIST OF COMMUNICATIONS

MADE TO THE SOCIETY DURING THE SESSION 1903-4.

		PAGE
1. Congenital cretinism in calves	C. G. SELIGMANN	1
2. Pedunculated chondroma of the knee-joint	R. JOHNSON	20
3. Congenital sacro-coccygeal tumour	H. J. CURTIS	22
4. Plexiform neuroma of orbit	W. C. ROCKLIFFE and J. H. PARSONS	27
5. New method of counting corpuscles of the blood	W. M. STRONG and C. G. SELIGMANN	39
6. Agglutination in cases of dysentery	R. T. HEWLETT	51
7. Estimation of bile salts	O. GRÜNBAUM	55
8. Thyroidal carcinoma	H. A. LEDIARD	60
9. Angioma arteriale racemosum	J. H. DRYSDALE	66
10. A new pathogenic anaërobe (*Bacillus carnis*)	E. KLEIN, F.R.S.	74
11. Examination of specimens of enlarged prostate	S. G. SHATTOCK	76
12. On the preparation of nutrose-agar	J. W. H. EYRE	91
13. A case of emphysematous gangrene caused by the Colon bacillus	LEONARD S. DUDGEON and PERCY W. G. SARGENT	107
14. The pelvic organs from a case of epithelioma treated by Dr. Otto Schmidt's serum	R. N. SALAMAN	119
15. A method for the detection of the *Bacillus enteritidis sporogenes* in water	R. T. HEWLETT	123
16. On the relation of *Staphylococcus pyogenes aureus* to rheumatic fever	F. J. POYNTON and W. V. SHAW	126
17 case of pyocyaneus pyæmia following otitis media	T. J. HORDER	140
18. A survey of the recorded cases of hæmatoporphyrinuria not due to sulphonal	ARCHIBALD E. GARROD	142

PAGE

19. A contribution to the pathology of the thymus gland
LEONARD S. DUDGEON 151
20. Cystic disease of the liver and kidney C. B. BLACKBURN 203
21. An anatomical criticism of the procedure known as total prostatectomy CUTHBERT S. WALLACE 255
22. The glomerular lesions of diffuse (parenchymatous) nephritis
W. P. HERRINGHAM and J. H. THURSFIELD 283
23. A case of leukanæmia with great hyperplasia of the spleen and prævertebral hæmolymph glands, and with increase of connective tissue in the bone marrow
F. PARKES WEBER 288
24. Sarcoma of the stomach RADCLIFFE N. SALAMAN 296
25. Calcifying chondrosarcoma of the breast
CHARLES A. MORTON 327
26. An unusual form of obstruction of the colon
CHARLES A. MORTON 329
27. A case of dermoid tumour of the brain
E. FARQUHAR BUZZARD 330
28. Sarcoma of the pancreas associated with pseudo-lipæmia
J. FAWCETT and A. E. BOYCOTT 332
29. A case of primary sarcoma of the liver in an infant
E. P. BAUMANN and J. G. FORBES 336
30. An experimental inquiry concerning epidemic or bacillary dysentery R. H. FIRTH 340
31. On arterial sclerosis, especially in regard to arterial hypermyotrophy and the other morbid changes which occur in the muscular tunic of the arteries
THOMAS D. SAVILL [and other speakers] 375
32. Cytology of malignant tumours C. E. WALKER 449

REPORTS OF COMMITTEES.

PAGE

Report upon Mr. C. A. Morton's specimen of calcifying chondrosarcoma of the breast [H. M. Fletcher, C. P. White] 327

LIST OF PLATES.

		TO FACE PAGE
I.	Carcinoma of thyroid. (H. A. Lediard)	64
II, III.	Bacteriology of rheumatic fever. (F. J. Poynton and W. V. Shaw)	138
IV.	Pathology of the thymus. (L. S. Dudgeon)	202
V.	Glomerular lesions in diffuse nephritis. (W. P. Herringham and J. H. Thursfield)	287
VI.	Sarcoma of the stomach. (R. N. Salaman)	312
VII, VIII.	Epidemic or bacillary dysentery. (R. H. Firth)	358
IX.	Cytology of malignant growths. (C. E. Walker)	454

LIST OF FIGURES IN THE TEXT.

		PAGE
1—6. Congenital cretinism in calves.	(C. G. Seligmann)	4—14
7. Sacro-coccygeal tumour	(H. J. Curtis)	24
8—10. Plexiform neuroma of orbit	(W. C. Rockliffe and J. H. Parsons)	31—34
11—14. Method of corpuscle-counting	(W. M. Strong and C. G. Seligmann)	42—46
15. Estimation of bile salts	(O. Grünbaum)	56
16. Carcinoma of thyroid	(H. A. Lediard)	62
17—19. Angioma of brain	(J. H. Drysdale)	67—71
20—22. Enlarged prostate	(S. G. Shattock)	84—89
23—25. Bacteriology of rheumatic fever	(F. J. Poynton and W. V. Shaw)	135—137
26—32. Pathology of the thymus	(L. S. Dudgeon)	163—190
33—35. Cystic disease of the liver and kidney	(C. B. Blackburn)	207—210
36—59. Prostatectomy	(C. S. Wallace)	256—282
60—62. Leukanæmia	(F. P. Weber)	292—294
63—67. Sarcoma of the stomach	(R. W. Salaman)	298—308
68—81. Arterial sclerosis	(T. D. Savill)	379—400
82. Cytology of malignant tumours	(C. E. Walker)	455

REPORT.

SESSION 1903–4.

---

1. *Congenital cretinism in calves.*

By C. G. Seligmann.

Summarium.

De cretinismo ingenito apud vitulos.

Maxime frequenter apparet cretinismus ingenitus apud prolem boum, varietatis Dexter-Kerry.

Hic morbus aliter raro reperitur, paucis modo exemplis a Müller, Eberth, Gurlt descriptis.

Hujus varietatis (quæ in regionibus meridianis Hiberniæ indigena est) pecudes sanæ brevitate membrorum conspicuæ sunt.

Proles morbo affecta aspectum cretinismi proprium monstrat; basis cranii maxime brevis est; caput, brachycephalicum; nasus recedit; lingua ex ore exstat.

Ossa membrorum omnia brevissima sunt, sed nullo modo imperfecte calcificata.

De glandulâ thyroidea dicere opportet structuram ejus penitiorem a normâ discedere.

Epithelium aut nullo ordine, aut in ordinibus ramosis sine lumine ac sine substantiâ colloidea dispositum est.

Extractum glandulæ recentis, glycerino factum, nihil physiologice efficit quum in animalium venas introducitur; i. e. nulla pressionis diminutio in systemâ vasculosa consequitur, ut efficit extractum e glandulâ vituli normalis atque recens nati ejusdem varietatis (Dexter-Kerry).

Non invenitur bronchocele in eis regionibus in quibus hæc varietas indigena est.

Shattock sententiam proponit, hanc varietatem boum, forsitan, de stirpe pathologica ortam esse,—pecudes hujus varietatis paracretinosas esse,—glandulam thyroideam, etsi adultis singulis sufficit, non supplere posse secretionis additamentum si fetus ab hac parte desit.

Quum conjungata sit placentæ œdema cum cretinismo in his vitulis, *illud* haberi potest *hujus* causa adjuvans.

Hic morbus, enim, placentæ (etsi œdematis fetalis extensio esse potest) secretionis maternæ aditum prohiberet ad fetum in quo lesio glandulæ thyroideæ orta sit.

Si placenta integra esset, secretio thyroidea materna, ut credi potest, inopiam suppleret, quoniam experimentum monstrat nihil morbi in cane pregnante oriri a quo glandula thyroidea fere tota ablata est; defectus, enim, suppletur catulorum glandulis auctis.[1]

Since the Dexter-Kerry breed of cattle has become popular in this country it has been noted by breeders that in every herd a variable, but often by no means insignificant number of calves are born which exhibit an extremely marked and constant type of deformity. Such monsters are generally born prematurely. From their most striking characteristics, viz. a short rounded head, depressed nostrils, and projecting mandible, combined

[1] Halsted, 'Johns Hopkins Hospital Reports,' vol. i, 1896; Edmunds, 'Transactions of the Pathological Society of London,' vol. li, p. 221.

with extreme shortness of the limbs, there has been derived the special term "bull-dog calves," under which name this type of deformity seems to be generally recognised by breeders.

In this paper evidence will be adduced to show that these monsters are, in fact, cretins, but before passing to anatomical and physiological details it seems worth while to consider the conditions under which these cretins arise. In this country, as far as I have been able to learn, "bull-dog calves" occur only among the pure Dexter-Kerry breed, and perhaps very rarely among half-bred Dexters. I have been unable to ascertain whether such monsters occur among the Dexters of Kerry, where the breed appears to have arisen; probably they do, since Dexters have only been fashionable in this country for some ten or fifteen years, and likely bulls without pedigree are still imported for stud purposes.

The English Dexter Society was founded in 1892, its herd book dating from 1899, while the Royal Dublin Society's herd book came into existence some ten years or more previously. It has been necessary to state this point with precision, since it seems to negative the idea entertained by certain breeders that the occurrence of bull-dog calves is due to a large amount of inbreeding having taken place, at any rate within recent years.

In regard to other countries and breeds I have not found any record in literature, except two instances described and figured by Müller [1] and Eberth [2] respectively.

Eberth, who wrote in 1878, considered that his monster was a cretin, and referred to this class certain monstrous calves very briefly described by Gurlt,[3] who makes no mention of their *provenance*. This appears to practically exhaust the literature on the subject, but a stuffed specimen is to be seen in the Natural History Museum, South Kensington, and the College of Surgeons possesses a complete skeleton of a typical calf cretin (Teratological series 183 A).

The general appearance and character of normal members of the breed will be appreciated from the chief points of the breed as given in the herd book, and from the photograph of a prize

[1] Müller, H., 'Wurzburger med. Zeitschrift,' Bd. i, 1860.

[2] Eberth, C. J., 'Die fötale Rachitis und ihre Beziehungen zum Cretinismus,' Leipzig, 1878.

[3] Gurlt, E. F., 'Ueber thierische Missgeburten,' p. 13, Berlin, 1877.

cow, for the use of which I am indebted to Mr. J. Sidney Snelgrove, whom I take this opportunity of thanking for his valuable help and advice, both of which have been freely placed at my disposal.

"Bulls and cows should not exceed 900 and 800 lbs. live weight respectively, when in breeding condition. Head short and broad, with great width between the eyes, and tapering gracefully towards muzzle, which should be large, with wide distended nostrils. Eyes bright, prominent. . . . Neck

FIG. 1.

A normal Dexter-Kerry cow, showing the notable shortness of the limbs.

EXPLICATIO FIGURÆ.

Vacca normalis, varietatis Dexter-Kerry, cujus varietatis propria est brevitas insignis membrorum.

short, deep, and thick, and well set into the shoulders, which, when viewed from the front, should be wide, . . . the breast coming well forward. Horns: these should be short and moderately thick, springing well from the head, with an inward and slightly upward curve. Body: shoulders of medium thickness, full, and well filled in behind, hips wide, quarters thick and deep and well sprung, . . . legs short (especially from knee to fetlock), strong, and well placed under body, which should be as close to the ground as possible."[1]

[1] 'The English Kerry and Dexter Herd Book,' 1900, vol. i, p. xv.

Before describing the chief anatomical and physiological peculiarities of the monsters under consideration, and giving in detail the evidence which proves that they are really cretins, it seems advisable to briefly refer to the environment of the herds from which specimens were sent me, and to the natural and clinical history of the cretins themselves and of their parents.

With regard to the origin of the breed, the following is taken from the introduction to the English Herd Book: [1]

"Its origin lies in obscurity, but the mountainous and comparatively inaccessible situations which they (the Dexter cattle) occupy seems to point them out . . . as an aboriginal breed; . . . at any rate, all that we know for certain is that they are indigenous to the south and south-western districts of Ireland, where they have been bred by the small farmers for many years; in fact, we may go further, and say that they are the only true native breed that can be claimed as its own by that island."

Another, and probably more correct view, attributes the origin of the breed to a Mr. Dexter about the middle of the eighteenth century, but whether as the result of selection or a cross between the pure Kerry and another breed, perhaps the shorthorn, is uncertain. I have consulted a well-known and successful breeder of Dexters, who tells me that he believes the breed arose by selection, since the Kerry shorthorn cross produces an animal larger than the Kerry. Further, he has seen a pure-bred bull the offspring of a Kerry cow, well known as a prize-winner, "which had quite short legs, and in general appearance had many characteristics of the Dexter." Similar cases where the produce was a cow have come under my informant's notice. Again, as regards coloration, Dexters are either black or red, while the Kerry is typically black, but I have been assured that cows of the latter breed sometimes produce red calves.

With one exception all the specimens examined have come from two herds, which I will call A and B. Both these herds have produced prize-winners, and both have been constantly reinforced with fresh blood, so that it can be definitely stated that both are to be regarded as typical of the breed, while in neither has any marked degree of in-breeding taken place.

[1] Loc. cit., p. xi.

The home of herd A is situated in the Wealden district, deep in the Hastings sands, closely underlying which are the Purbeck beds. Lying about 120 miles to the west of this, and situated at the junction of oolite limestone and Oxford clay, is the farm which supports herd B. To the west is oolite, with outliers of Oxford clay; to the east is the main mass of the Oxford clay, beneath which there is oolite limestone. The one monster above alluded to as having a different *provenance* came from a herd situated very near to and on the same formation as herd A.

Another herd of Dexters, formerly existing on the chalk in East Anglia, has also produced "bull-dog calves," though no record has been kept of their number.

Kerry, the home of the breed, consists of a Carboniferous limestone basin in a great part filled up by coal measures. At the periphery of the district masses of old red sandstone and metamorphic rock crop out from beneath the limestone.

The number of cretins produced in a herd appears to vary from year to year. In herd A, which in 1901 produced seven cretins (35 per cent.) in twenty births, fourteen cretins have been produced among fifty-five calves in about seven years (25·4 per cent.). Herd B has in three years produced twenty-seven calves, five of which were cretins (18·5 per cent.). Not enough figures are available to assert whether there is or is not a tendency in special families to produce cretins, and cows which have produced cretinous offspring may subsequently give birth to normal calves. Certain individuals do, however, seem to produce a large number of these monsters: thus in herd A one bull born in the herd out of a dam who had three calves by three bulls, none of which were cretins, sired eight calves, four of which were cretins. In the same herd a cow—the daughter of a mother which had four calves by three bulls, all of which were normal—had two calves by different bulls, both of which were cretins. Herd B at present consists of twelve cows, which, as above stated, have produced twenty-seven calves, five of which were cretins: six of these cows have had three normal calves each; two have had one calf each, not cretins; two have had two calves each, one of which, in both instances, was a cretin; one has had two calves, both cretins, the other one calf, a cretin. Nineteen of the twenty-seven calves, including all five cretins, were sired by three bulls. The first of these, bred

in England, sired nine calves and got two cretins; the next bred in the herd sired four calves, two of which were cretins; while the third, bred in Ireland, sired six calves, and got one cretin.

Eberth notes that his case was born at full term, and was the ninth calf of a twelve-year-old cow, which had lived for the past nine years in a roomy stall, and had already produced eight healthy calves.

While inquiring into the family history of these cretins it became evident that the pregnancy of a cow about to produce a cretin differed in certain respects from that of a cow in calf with a normal fœtus. The full period of gestation for a Dexter cow is about forty weeks, or, more accurately, 284 days. Rarely it may extend to forty-one or forty-two weeks. Bull-dog monsters, *i.e.* cretins, are usually dropped about the sixth, seventh, or eighth month, but in almost every case, some time before this, usually about the fourth or fifth month, the cow's belly begins to swell, and in time becomes enormously distended. Before the cretin is born, sometimes at the beginning of labour, sometimes as much as three months before, the cow loses a large quantity of "water," and her size decreases. When this occurs months or weeks before labour, a further abnormal increase in size associated with accumulation of fluid may take place; the latter is then got rid of as a watery discharge, and the process may even be repeated a third time.

The fluid lost, sometimes described as "clear," was at times called "muddy coloured," but to the lay eye was not usually obviously blood-stained. It is not, however, invariable for a Dexter cow with a distended belly to produce a cretin, though such is usually the case. Mr. Snelgrove has seen cows with extremely distended bellies produce normal calves.

Further, in cows producing cretins the lochia are described as being more abundant and lasting longer than usual, so that a blood-stained discharge may last for from one to two weeks, instead of almost ceasing in as many days or existing only as a slight serous flow for a short time longer. The afterbirth. instead of coming away entire in from half an hour to four hours, as is normally the case, is got rid of slowly and in fragments, the process often lasting two to three days, or even longer. The breaking up of the placenta may proceed so far that it may be difficult to recognise its existence. One of my

informants, a fairly intelligent cowman, volunteered the information that with some "bull-dog" calves there appeared to be no after-birth.

The association of cretin births with placental disease suggested by these statements was fully borne out by the condition of the placentæ, which showed marked pathological changes, which will be described in detail later. Meanwhile the clinical history of one cretinous pregnancy, which was noted with unusual care by a highly competent observer, is here given.

A heifer born in February, 1901, in herd A was served by a prize bull on July 29th, 1902. Nothing abnormal was noticed till the middle of December, when her belly appeared considerably larger than it should have been at that period of pregnancy. My informant did not again see the cow until January, 1903, when the swelling had disappeared. At the beginning of February the swelling was again very obvious, and was accompanied by a discharge described as slimy. About the middle of the month a large quantity of blood-stained fluid came away, and the swelling considerably decreased. There was little alteration in her condition until March 13th, when a profuse watery discharge, described as streaming from her and lasting for about six hours, occurred. A veterinary surgeon was then called in, and he, after some trouble, effected delivery, "gallons" more of watery fluid being expelled immediately after the calf was born.

The general appearance of a cretinous Dexter calf is as follows:—In all the specimens examined the vertebral column was short and hyper-extended. The trunk was short, stout, and appeared bloated, the last probably being in part the result of the shortened spine. To the same cause may be attributed the gap always present in the anterior abdominal wall, through which a peritoneal pouch, containing coils of intestine and sometimes a portion of the liver, protruded. The skin was thick and coarse, bearing a plentiful crop of hair, which did not appear coarser or longer than usual. The subcutaneous tissue was invariably extremely œdematous. The head, at first sight not very unlike that of a bull-dog, presented the appearance of extreme brachycephaly, the rounded forehead bulging over the extremely depressed nose, beyond which the short, broad snout scarcely projected, thus exaggerating the apparent length of

the lower jaw, which in every instance was normally developed.

The abnormally long and fleshy tongue protruded from the half-open mouth, the lips hanging down in front of the chin. The palate was always cleft. The epiglottis was bifid in every case, and the trachea, small and often irregularly narrowed and flattened to an extreme degree.

The neck in all these cretins was extremely short and stout; the chest small and ill-developed. The thymus appeared normal and covered the heart, which showed no obvious defects. The lungs were of a fair size; in no case was there any appearance of there having been any attempt at respiration. The abdominal

FIG. 2.

A cretinous calf, showing the bull-dog appearance of the head, the protruding tongue, and the extreme shortness of the limbs. The hind limb lies a considerable way above the ground, in consequence of the ill-development of the spinal column and the protrusion of the abdominal viscera. The head is raised on a block.

EXPLICATIO FIGURÆ.

Vitulus cretinosus (varietatis Dexter-Kerry). Brevitas insignis membrorum monstratur, atque capitis deformitas morbi propria. Lingua tumida ex ore exstat.

viscera, which, as already stated, protruded irregularly through a defect in the anterior abdominal wall, showed nothing specially noteworthy on superficial examination; in one example the kidneys seemed small. The fat throughout the body generally seemed unusually firm, and at the sides of the neck and upper

part of the thorax formed large, almost tumour-like masses; indeed, the fat seemed to be the only form of connective tissue in the body not softer than usual and not more or less infiltrated with serum. The condition of the thyroids and their microscopical appearance will be separately described; the lymphatic glands in the neck appeared enlarged—possibly this enlargement was more apparent than real, owing to the general œdema in which they shared. All four limbs were extremely reduced in size, about half their length being constituted by the soft but apparently fully developed hoof. The muscles generally were pale and flabby, and contained an excess of fluid, as did the serous sacs, and, in a lesser degree, the tissues generally.

The bones of the limbs, including those of the shoulder and pelvic girdles, are all extraordinarily stunted, and, owing to the thickness of the badly formed and abnormally soft cartilaginous epiphyses, their length is even less than the external appearance of the dwarfed limbs would seem to indicate. The whole fore-limb of one specimen, including the scapula and hoof, measured only 152 mm., of which the latter accounted for 34·5 mm., while the humerus measured only 13 mm. The periosteum everywhere was well developed, perhaps even thickened. The lines separating the epiphyses from the diaphyses were, generally speaking, somewhat but not markedly irregular in outline.

In the skull the most obvious changes are shortening of the cranio-facial axis, and consequent retrocession of the bones of the face. The size of the lower jaw is not diminished.

The bones of the skull generally are thicker than normal and extremely hard, and the sutures are to a considerable extent obliterated. In the specimen at the College of Surgeons (Teratological Series 183A), however, as well as in one in the Museum of St. Thomas's Hospital, this is not the case: here the bones of the vault are thin, appear expanded, and fail to approach each other in the neighbourhood of the anterior fontanelle, where a large gap bordered by thinned bone exists, so that the appearance of the vault of these skulls suggests that they are, at the same time, cretinous and hydrocephalic.

Eberth mentions excess of fluid in the lateral ventricles of his calf's brain. In none of the three brains removed for the purpose of studying the pituitary body, and roughly examined, was

FIG. 3.

One of the fore-limbs of a cretinous Dexter-Kerry calf. All the bones are exceedingly short. A sagittal section has been made through the upper end of the humerus into the shoulder-joint; the higher three fourths of the section consist of the epiphysial cartilage.
Above the opened shoulder-joint is shown the scapula.

EXPLICATIO FIGURÆ.

Unum e membris vituli cretinosi (varietatis Dexter-Kerry). Ossia omnia brevitatis sunt insignis.
Sectio sagittalis per extremitatem superiorem humeri facta est.

FIG. 4.

A sagittal section of the skull of a cretinous calf (Dexter-Kerry), showing the shortening of the basis cranii, the projection of the frontal region, and recession of the nose.

EXPLICATIO FIGURÆ.

Sectio sagittalis cranii vituli cretinosi (varietatis Dexter-Kerry). Monstrantur brevitas insignis basis, prominentia notabilis frontis, atque nasi recessio.

FIG. 5.

The same skull viewed from the outer aspect.

EXPLICATIO FIGURÆ.
Cranium idem ab extrà conspectum.

there any obvious excess of fluid, either in the ventricles or as a part of the generalised œdema.

Eberth notes that the thyroid of his cretin was enlarged and rich in blood. The latter part of this statement holds good in all the cretinous thyroids I have examined; in addition they were invariably soft, and much infiltrated with serum. As regards their size, I do not think they were substantially enlarged;

FIG. 6.

A microscopic section of the thyroid gland of one of the cretinous calves examined. The epithelium is packed without any order in the gland spaces, which hold, moreover, no colloid. (Low magnification.)

EXPLICATIO FIGURÆ.

Sectio microscopica glandulæ thyroideæ a vitulo cretinoso (var. Dexter-Kerry) ablatæ. Epithelium modo confuso sine lumine ac sine substantiâ colloidea dispositum est.

certainly they were not so when compared with the thyroids of two newly born calves, one of which was a Dexter. A difference in shape between the normal and cretinous thyroids was, however, constant. In the former the glands were of the usual bilobed form, with a well-developed isthmus; in the latter the thyroid was represented by a couple of more or less rounded, œdematous, dark purple-coloured masses, one on each side of

the trachea, the isthmus being absent or irregularly or slightly developed.

Microscopically the thyroid glands of these cretins present certain well-marked changes. The cells are only partially or not at all arranged in vesicles; more commonly they form irregular masses or branching columns, with or more frequently without a lumen. Colloid is commonly absent, more rarely it is represented by an irregularly vacuolated substance present in a few vesicles only. The vascularity of the gland is much increased, an irregular capillary network which ramifies throughout the gland substance forming a prominent feature of the sections, and containing in its meshes the cell groups above alluded to.

The results of histological examination of the thyroids, showing as already stated complete or almost complete absence of colloid, were checked by experiments, in which 50 per cent. glycerine extracts of the fresh cretinous glands were injected into the jugular veins of animals, and the blood-pressure observed. Due precautions were taken to fully extract the glands. Immediately on removal from the animal they were cut small, about their own volume of 50 per cent. glycerine added, and the whole repeatedly ground in a mortar with sand which, between grindings and overnight, was kept in an ice safe. Finally, before filtration of the turbid extract with the aid of a vacuum pump, the mortar containing the mixture was kept at room temperature for two to three hours, during which time the mixture was frequently ground.

As a result of such intra-venous injections no fall of blood-pressure, or a very slight one, took place; this contrasted with the result produced by similar extract made from the thyroid of a normal newly born Dexter-Kerry calf.

Sections of the pituitary bodies of three of the calves were examined and compared with the pituitaries of two normal newly born calves. In all these, *i.e.* in both normal and cretinous calves, the pituitaries appeared of an equal size, while histologically no difference could be traced in either the anterior or posterior lobes of the body.

In two instances in which it was possible to examine the placentæ there were obvious changes in their appearance, such as might have been expected from the clinical history already

given. The specimens, which were in excellent condition when received, were removed manually from two cows which had shown the characteristic signs of being pregnant with a cretin. In these two animals labour was so prolonged that a veterinary surgeon was called in. The latter apparently performed some form of embryotomy in both cases, and at the same time removed the placentæ, which, with the remains of the fœtus, were immediately forwarded to me in spirit and water. Both placentæ were extremely œdematous; the greater number of the cotyledons which studded their surface showed various degrees of atrophy. In some this was so extreme that the cotyledons were represented only by slightly roughened circular areas, studding which were insignificant remains of villous processes. In other cotyledons the villi, though obvious, were smaller and scantier than is normally the case; while in only a few did the development of intricate papillary processes approach the normal. In both placentæ besides the general œdema there were numerous areas where fluid had collected in pockets, leading to the development of a series of sessile cyst-like masses (the largest about the size of a Tangerine orange) on the fœtal surface of the placenta. In the cleansings of one of the cows there were numerous small pieces of hard calcified material about the size of a hempseed. Microscopically the tissue closely resembles that of the so-called nasal myxoma,—that is, it consists of an extremely delicate net containing few connective-tissue cells, the meshes of which in the recent state were filled with a serous fluid. A certain number of vessels traverse this tissue, the walls of the larger of which show a similar œdematous condition. In one of the vessels the wall shows a semilunar thickening, apparently necrotic, but as yet uncalcified.

Of the causes determining fœtal or congenital cretinism little is known. As in the commoner non-congenital form of cretinism, the condition may occur endemically under certain unknown circumstances; while a sporadic form may also be recognised as in Eberth's case, and the instances brought forward by Shattock in 1881.[1]

Unlike the endemic (acquired) cretinism of Switzerland and

[1] 'Trans. Path. Soc.,' vol. xxxii, p. 369.

the Austrian Alps, the condition described in this paper is not, as far as I have been able to ascertain, associated with an abnormally high frequency of goitre in the districts from which my specimens came, and my inquiries made it clear that no goitrous or other enlargement of the throat occurred in the herds into which the cretins were born. A further difference between these and the Swiss cretins is that although both may be termed endemic, my examples were all drawn from one particular breed of cattle, occurring in the midst of herds of other breeds, among whom it may be definitely stated no cretins were born. The presence of a water-supply from limestone strata has, as is well known, been thought to be accountable for the occurrence of goitre, and possibly a similar hypothesis might be advanced to account for the occurrence of the calf cretins. From the geological notes given in describing the environment of herds A and B, the percolation of the water-supply through limestone to a greater or lesser degree is almost a certainty in both cases. The limited racial occurrence of the cretins, however, seems to negative the idea that this may be a determining factor.

As regards the presence of human goitre and cretinism in the areas which have produced calf cretins, Berry states that "over the extensive region of the chalk goitre appears to prevail to a very slight extent, but tolerably uniformly." Further, he believes that "the disease (goitre) is distributed tolerably uniformly, although not very thickly over the whole of the central (Hastings sand) area of the Weald;" while he dissents from the commonly accepted view that goitre does not occur upon the oolites, except in Yorkshire, having found it "tolerably common upon certain members of the oolite series."

In this country goitre is undoubtedly common in certain Carboniferous limestone regions, *e. g.* Derbyshire, and this is substantially the formation of which Kerry, the home of the breed, consists. From the above remarks on distribution it would appear that goitre is widely but sparsely distributed over practically the whole of the Secondary deposits of the south of England, with nowhere any very marked area of maximum intensity.

The actual cause of the cretinous condition of these calves cannot at present be explained.

Mr. Shattock has suggested to me that the peculiarities of the Dexter-Kerry herd may possibly rest upon a pathological ancestry; that the herd, in fact, is itself subcretinoid or paracretinous; that the thyroid, though sufficient for the individual requirements of the adult, is incapable of furnishing an additional output of secretion should the offspring happen to be defective in the same respect, *i. e.* that any want on the side of the fœtus is not made good from the side of the mother.

Some such hypothesis seems to him to harmonise best with the remarkable frequency with which cretinous calves are thrown by the breed in question; and he points out that the vagaries in the results are not greater than those accompanying the transmission of parental characters in general.

That the normal animals of the Dexter-Kerry type, which, on this suggestion, transmit the tendency, are not themselves cretinous, seems clear from the undoubted comeliness and briskness of even the most highly bred prize-winners, *i. e.* animals specially approved for their small size and short legs. Again, Dexter cows are excellent milkers, nor do they show any tendency to sterility, as might be expected in a semi-cretinous breed. As far as I have been able to ascertain, goitres or thyroid abnormalities do not occur,—at any rate, I have been unable to hear of anything of this nature occurring in members of the breed constantly under observation in this country.

That the cretinism is constantly associated with placental disease there can be no doubt, and that the latter is in some way connected with the condition of the calf may be suggested, since it is reasonable to suppose that the thyroid material circulating in the maternal blood would prevent the development of the cretinous condition were the circulation maintained in the normal manner. It is well known that improvement during pregnancy may occur in myxœdema, which can only be explained by fœtal thyroid secretion reaching and acting on the maternal tissues. Again, athyroidea does not occur in pregnant bitches in which nearly the whole of the thyroid has been removed, the explanation of which appears in the fact that the thyroids of their pups show compensatory overgrowth.

These observations do not explain, however, the typically cretinous lesion of the thyroids in these calves, since the diseased condition of the placenta, though it prevent the trans-

mission of the maternal secretion, may be itself an extension of the waterlogged state of the fœtus, and similarly dependent upon the lesion of the thyroid gland.

Whatever hypothesis be provisionally adopted, these calves may perhaps fall into line with a class of cases with which, at first sight, they do not seem closely connected ætiologically. I refer to those instances of cretinism, endemic or sporadic, in which cretinous changes begin within the first few months succeeding birth without the intervention of any acute fever or other accident to which the condition might be attributed. Here I would suggest we are possibly dealing with a condition of potential fœtal cretinism, *i.e.* the thyroid of the fœtus *in utero* may not be normally performing its secretory function, which need not, however, necessarily be supposed to be in total abeyance. As long as the fœtus remains directly connected with the maternal circulation, it receives—the placenta being healthy—a sufficiency of thyroid secretion for its use. After birth this is not so, and the changes which clinically and histologically comprise cretinism appear and develop. Such an hypothesis seems to explain the first of the four cases recorded by Fagge,[1] in whom nothing amiss was noticed during early infancy, although after a time it was observed that the child would sit down and remain silent and motionless for hours together, while stunting and the characteristic physiognomy of cretinism subsequently developed.

Conclusions.

(1) Congenital cretinism is common in a special breed of cattle, the Dexter-Kerry, to which in this country it is almost, if not entirely, limited.

(2) Such cretins show the characteristic gross lesions, and the histological changes in a marked degree, including those first described by Edmunds in the thyroid of human cretins.

(3) The condition cannot be ascribed to inbreeding, but clinically is invariably associated with placental disease in the parent cow; and where it has been possible to examine the placentæ from cretin births, marked and constant changes have been found.

[1] 'Med.-Chir. Trans.,' vol. liv, 1871, p. 155.

(4) No satisfactory explanation can at present be given of the occurrence of cretinism in the Dexter breed only. As for its association with a constant form of placental disease, the latter may be considered as an indirect or secondary factor in its production by preventing the access of the maternal thyroid secretion to the fœtus in which the thyroid lesion characteristic of cretinism has arisen. *May 5th*, 1902.

---

2. *Pedunculated chondroma of the knee-joint.*

By Raymond Johnson.

The specimen (Univ. Coll. Museum, No. 999 A) consists of a small piece of the synovial membrane of the knee-joint, to which a pedunculated chondroma is attached. The chondroma forms an irregularly rounded disc, 3 cm. in diameter, and about 1 cm. in thickness. One aspect is convex and the other flat, and at all parts the surface is beset with small cartilaginous nodules. At its upper border the chondroma becomes narrowed into a short flattened pedicle, by which it is attached to the synovial membrane. In the latter, around the attachment of the pedicle, are numerous small white nodules from 1 to 2 mm. in diameter, which, on microscopic examination, prove to be small masses of hyaline cartilage.

The specimen was removed by operation from the knee-joint of a man aged 40, an engine-driver on the Midland Railway. In June, 1900, whilst stepping from his engine he slipped and wrenched his right knee. The joint soon afterwards became painful, and in about six weeks began to swell. Some weeks later he applied for treatment at University College Hospital, and the knee was then distended with fluid. The effusion slowly subsided with rest and fixation of the joint, and then a hard, slightly movable body was felt in the outer part of the joint over the external condyle. Six months after the injury the chondroma, together with the portion of the synovial membrane to which it was attached, was removed.

When examined nearly three years later the movements of

the affected joint were accompanied by a fine crepitation not present in the opposite knee, and the edge of the inner tuberosity of the tibia was distinctly more prominent than in the other limb.

The origin of certain cartilaginous bodies found in joints in a growth of cartilage in the synovial membrane may be regarded as an established fact, whilst the explanation of such cartilage formation is assumed to be that cartilage cells are known to exist normally in the synovial villi or secondary fringes of Rainey.

The interest of this specimen is that it demonstrates so clearly this mode of formation of a cartilaginous body in the knee-joint, for in the substance of the synovial membrane in the neighbourhood of the attachment of the body are numerous nodules of hyaline cartilage, which were certainly even more numerous than the specimen shows, for they extend up to the cut edge of the synovial membrane.

The history of the case makes it difficult to believe that the formation of the cartilaginous body was not in some way causally related to the injury to the joint, and I can only suppose that the latter determined the cartilage growth in the synovial membrane, or brought into activity a growth which was already in progress. The slight signs of an affection of the joint, which are still present nearly three years after the operation, suggest that the cartilage formation may have been an early manifestation of a very insidious form of osteo-arthritis.

In the Fortieth volume of the 'Transactions' Mr. Shattock described a pedunculated chondroma of the knee-joint, and discusses the origin of the cartilage elements present in the synovial villi. He says, "The presence, then, of cartilage elements in the synovial fringes of the joints is, I submit, to be explained by regarding those elements as relics of the cartilaginous basis about the primitive sites of joint formation, and as the same mode of formation does not obtain in the case of ordinary bursæ and tendon sheaths, so there are no such residues from which chondromata may arise." To the last part of this statement, in so far as it applies to tendon sheaths, I am able to bring forward an exception—a cartilaginous tumour removed from a tendon sheath in the hand.

The tumour is lobulated, and nearly 2·5 cm. in its greatest diameter. It consists of small lobules of cartilage bound to-

gether by a fibrous capsule. The matrix of the cartilage is slightly fibrillated. The tumour was removed by the late Mr. Marcus Beck. It formed a swelling in the palm of the hand of a young woman, which was thought to be a ganglion. At the operation the cartilaginous tumour was enucleated from the upper part of the digital tendon sheath of the index finger; it appeared to be unattached. I can find no record of a similar specimen, and am unable to suggest its mode of origin.

October 20th, 1903.

---

3. *Congenital sacro-coccygeal tumour.*

By H. J. Curtis.

The patient was a girl twelve months old, and was admitted in July, 1903, into the North-Eastern Hospital for Children, Hackney Road, for a swelling over the sacrum to the right of the mesial vertical furrow separating the buttocks—that is to say, just at the inner border of the right buttock, where it formed a slight prominence, rounded, and the size of the tip of the thumb, the skin here being more porous than elsewhere, and exhibiting a small thin tuft of fair hair. Immediately beneath, a smooth, well-defined, laterally compressed, ovoid tumour, about the size and shape of a chestnut, could be felt passing down to the right border of the lower part of the sacrum and coccyx. Roughly the measurements appeared to be about one inch from above down, three quarters to seven eighths of an inch from before back, and about half an inch from side to side. The tumour could be freely moved from side to side, but not from above down. It could be moved as if rotating on a vertically placed hinge formed by the deep attachment to the edge of the sacrum.

Unfortunately no rectal examination was made, but at the operation it was evident that digital exploration in this way would have easily detected the deepest and largest part of the tumour lying in immediate contact with the back of the rectum,

between it and the hollow of the lowest segments of the sacrum and coccyx.

The child presented no other anomaly, and there was nothing of interest in the family history.

Operation.—The tumour was removed through an elliptical incision, the inner border, more vertical than the other, lying along the mesial vertical fold separating the buttocks. The tumour externally was concealed by or composed of fat. This fatty mass was isolated from its surroundings, and found to pass down by the side of the right edge of the sacrum and the adjacent coccyx, so that the greater portion of it lay on the ventral aspect of these bones. It was traced right down to the translucent posterior aspect of the rectum, which was thus clearly visible. But no direct connection with the bowel could be traced. This is a point of some importance from the developmental point of view.

Excision of the tumour was effected easily and the wound completely sutured, and though its lower angle was within half an inch of the anus, thanks to careful nursing, primary union was obtained.

The child, when seen two months later (September, 1903), was in good health, with the wound soundly healed.

Description of the parts removed.—The chestnut-shaped mass removed is covered superficially by skin, from the raised and rounded centre of which a few fine, fair hairs (some three quarters of an inch long) project. Below the centre is also seen a dark spot, formed by a small depression—the post-anal dimple. This is also seen in the sectional view. The lateral surfaces of the somewhat wedge-shaped tumour consist chiefly of fat, a few small, thin-walled cysts, varying in size from a lentil to a pea, being visible on one side. One of these, the size of a large pea, was punctured during the operation, evacuating a few drops of a clear, almost colourless, viscid fluid.

A sagittal section of the tumour presents the appearance depicted in the accompanying figure, drawn of natural size. The cut surface appears to consist chiefly of three large cysts, with numerous minute ones, less visible, embedded in fatty and white fibrous tissue, the fibrous trabeculæ spreading out from a centrally placed band in all directions—deeply, superficially, and laterally,—so as to separate into lobules the stroma, which for

the most part appears to be fatty in nature. Towards the skin surface the stroma in places is more translucent and of faintly greyish-pink tint, especially immediately beneath the post-anal dimple. The more dense fibrous tissue contains in its meshes minute cysts and a few blood-vessels. The cysts contain clear viscid fluid, the consistency of thick syrup.

The cyst wall is smooth, and of pearly grey tint. The wall, in the case of the largest cysts, is opaque white, and about one thirty-second of an inch thick.

FIG. 7.

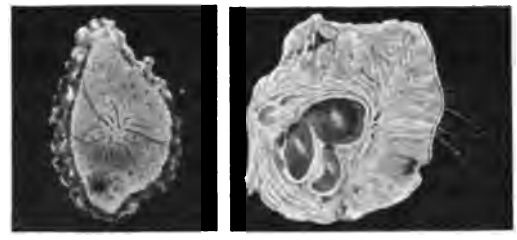

The left-hand figure shows the external swelling due to the tumour; the skin bears a thin tuft of hair.
The right-hand figure represents a sagittal section of the tumour, as described in the text.
The drawings are of the natural size.

Microscopically the cysts are seen to be lined with a single layer of large, fully developed columnar epithelium, of very uniform size, marked off from the surrounding tissue by a uniform and well-defined line—the so-called "basement membrane." The mucoid material still remaining in many of the cysts presents the appearance of a delicate reticulum, as if composed of fibrin, and it contains desquamated columnar or cuboidal cells.

Opening into such cysts are in places seen well-developed tubules lined by a single layer of large cylindrical cells. Tubules or duct-like passages, cut longitudinally or transversely, are seen in various parts of the field. Numerous bundles of non-striated muscle-fibres, fully developed, and cut in their length and crosswise, are seen, having no definite relation with the tubules.

One or two areas of hyaline cartilage are also visible, and in one place near the surface is a large area of epithelial and

epithelioid cells massed together without intervening stroma. This epithelial element is interesting, as it may be (as suggested to me by Mr. A. G. R. Foulerton) the remnant of the undifferentiated embryonic tissue from which the tumour itself originated.

Nature and origin of the tumour.—In discussing the nature and origin of the tumour, it may be useful to recall the fact that in very early embryonic life the primitive alimentary canal (derived chiefly from the hypoblast) communicates, by means of the neurenteric canal, with the central canal of the spinal cord; and later on the proctodæum, a pouch-like depression of epiblast, grows in from the surface to unite with the primitive bowel. This junction is effected in front of the neurenteric canal. The part of the primitive bowel between the entrance into it of the proctodæum and the neurenteric canal is now called the post-anal gut. The post-anal gut subsequently disappearing, is believed to be represented by the rudimentary glandular structure situated at the tip of the coccyx, known after birth as the coccygeal body (Bland-Sutton). This is believed to be the origin of tumours such as that now reported. They were formerly described as congenital cystic sarcomata, and by Bland-Sutton were termed thyroid dermoids. The cysts are lined with epithelium, either cubical or columnar in shape, and either a single layer of columnar epithelium as in the present case, or one layer of columnar cells set upon flatter cubical cells. Sometimes the cysts contain intra-cystic processes.

"Middeldorpf[1] was the first to associate clearly a congenital sacro-coccygeal tumour with the post-anal gut, his specimen being removed from the neighbourhood of the anus of a girl one year old,"[2] as in the case of the tumour now reported. Bland-Sutton had, however, come to the same conclusion before the publication of Middeldorpf's paper.

Alexander Mackay[3] successfully removed two such tumours in female infants aged respectively two and a half and three months, at Huelva, Spain.

Like Middeldorpf's case the tumour in the present instance

[1] 'Virchow's Archiv,' Bd. ci, p. 37.
[2] Bland-Sutton, 'Tumours,' pp. 318, 319.
[3] Ibid.

contained connective tissue, mucous membrane with characteristic follicles, submucous tissue, longitudinal and circular layers of muscle-fibres; in other words, it clearly represented a portion of bowel.

In one case reported by Dr. Charles Markus,[1] of Winberg, Orange River Colony, the tumour before removal was contractile, and actively contracted for a considerable time when the striated muscle present was gently stimulated.

Tumours of this variety are frequently of large size. There is another kind of tumour, post-rectal dermoids, found in the same situation as that now reported, namely, between the rectum and the hollow of the sacrum and coccyx. They are said by Bland-Sutton to be very rare, and not to form such large projecting masses as do the others sometimes, but famous cases of post-rectal dermoids are quoted by the same writer, weighing from 3 to 14½ lbs.

Yet another variety of dermoids in this region, called rectal dermoids, form pedunculated tumours within the rectum, from which long tufts of hair arise, and being extruded *per anum*, cause a great deal of annoyance.

Like the post-rectal variety, the rectal dermoids sometimes contain teeth; hair, glands, fatty and fibrous tissue, however, constitute the bulk of the tumour. The presence of bone and brain substance has been recorded. In three cases the ages respectively were nine, sixteen, and twenty-five years, all being females.

The presence of teeth here is interesting. They are possibly derived from a portion of the proctodæum, which thus imitates its analogue at the upper end of the alimentary tract, the stomodæum, the invagination of the blastoderm which forms the mouth, and so the teeth. *October* 20*th*, 1903.

[1] "Ueber ein Fall von angeborener Sakralgeschwulst, etc.," 'Inaugural Dissertation,' Freiburg-i.-Br., 1898.

4. *Plexiform neuroma of the orbit.*

By W. C. Rockliffe and J. Herbert Parsons.

(*Clinical account and autopsy by* Dr. Rockliffe.)

Helena H—, aged 22 months, attended the Hull Royal Infirmary under the care of Dr. Rockliffe, July 2nd, 1899.

The patient was shown at the Ophthalmological Meeting as a card specimen, October 19th, 1899, entitled "Congenital Pulsating Exophthalmos."

She is one of a family of eight, all apparently healthy, and no instruments were used at birth. There is no history of injury.

The child probably had purulent ophthalmia, which yielded to treatment in five weeks, when the mother remarked the swelling of the lids remained, and that the right globe was prominent, since which the proptosis has increased; otherwise the child has been in good health.

On examination of the right eye there were found swelling of upper and lower lids; slight ectropion of the outer extremity of upper lid, with distended veins. The proptosis was inward and downwards, and the eye moved freely in every direction; no chemosis, slight conjunctivitis. No solid growth, bruit, pulsation, fluctuation, tenderness, or pain, but a soft elastic growth could be felt deep in the orbit. Vision apparently normal. Left eye normal.

Under chloroform.—The globe pulsated synchronously with the systole, and a moniliform tumour was felt deep in the orbit. The pulsation was partially controlled by pressure on the carotid; but no bruit could be detected. The above condition varied; at times the swelling diminished considerably, and there was no visible pulsation, while at others it was most marked; but under an anæsthetic the pulsation was pronounced in the eye, but not always in the growth.

During the previous fortnight the child had lost flesh, but otherwise was healthy and devoid of pain.

The advisability of electrolysis, ligaturing the carotid, or

excision was discussed, resulting in operative interference being postponed.

The tumour continued to enlarge, with increased venous congestion of the lids, nevertheless the child was in perfect health.

June 5th, 1902.—The skull appeared to be enlarging and the posterior fontanelle reopening, with distinct pulsation. There was no sickness or headache, and the child regularly attended school. Although the prognosis was doubtful, owing to the health remaining perfect, interference was further postponed, notwithstanding the orbital contents being on the cheek, and the cornea on the level of the alæ of the nose, and both lids everted.

November 3rd, 1902.—Ulceration of cornea from exposure. The lids were also more thickened and completely everted, with tendency to bleed. The growth was much larger, extending over the eyebrow, and pressing on and flattening the right alæ, it almost completely blocking the right nostril, from which exuded a continuous viscid mucous stream. The posterior cranial bones appeared to be further separated; otherwise the child was well, healthy, and intelligent.

In January, 1903, the cornea had sloughed, with prolapse of iris, and still a constant running from right nostril continued. Veins of forehead were much enlarged. Girth of head 21¼ inches. The growth extended about half an inch below the angle of the mouth, and measured from the left inner canthus across the nasal bones and brow to right temporal region 2¾ inches; downwards to cilia 2 inches, and projected 1½ inches in front of the superior maxilla. At the parents' request an operation was decided upon.

On January 16th, 1903, chloroform being administered, Mr. E. H. Howlett placed a ligature round the right carotid, and on slightly tightening it the face and head at once became pale, and the tumour softer and reduced in size. The skin and fascia of lids were first divided on a director, the ligaments and periosteum surrounding the orbit being separated. The contents were cleared out with curved scissors, during which, at the inner side over the nasal bones, there was a sudden rush of dark-coloured fluid, supposed by those present to be stained cerebro-spinal fluid. The whole of the superior orbital ridge was sharp

and rough, and from immediately behind this the orbital plate of the frontal bone was missing, together with the remaining bones of the orbit.

The tumour was with difficulty separated from the dura mater, and considerable hæmorrhage followed; a strong double ligature being placed round the base, the whole orbital contents were removed, and the orbit plugged with gauze and the carotid tied. During the operation the respiration remained normal, but the pulse entirely stopped, and two and a half pints of saline was transfused intra-venously into the arm, with hypodermic of strychnine. Two hours later secondary hæmorrhage occurred, and the orbit being re-plugged the child rallied, but shortly afterwards fell back moribund.

The tumour was forwarded to Mr. J. H. Parsons, Pathologist, Royal London Ophthalmic Hospital, who reported the case was probably one of plexiform neuroma.

Post-mortem.—Made by Dr. Eve, house physician, Hull Royal Infirmary, who reported.

Skull.—Crown measured 21¼ inches.

The vault was very thin and translucent. The posterior fontanelle was open (size of florin), and there was a second small perforation about 1 mm. in diameter, situated about one inch further up the parietal suture.

Brain.—The right hemisphere was considerably larger than the left, as also were the superficial central blood-vessels on the right side. There was generalised œdema of the arachnoid space. The right ventricle was considerably distended, but otherwise the brain was healthy. In fact, every abnormal feature could be attributed to the enormous distension of the right orbit, encroaching on the cranial cavity, entirely absorbing the bony roof of the orbit, and producing the following distortions:

(A) The pituitary body, optic commissure, and adjoining soft and bony parts were pushed some three quarters of an inch to the left and distorted.

(B) The crista galli and the central dividing crest of the parietal bone were pushed nearly one inch to the left of median line.

(C) The whole of the orbital plate of the frontal, the lesser and greater wings of the sphenoid, and the lacrymal plate of the

ethmoid were missing, and the inner margin of the supra-orbital ridge was serrated.

The roof of the orbit was represented only by thickened dura mater, which had necessarily been bruised and perforated at the operation.

The orbital tumour was, of course, absent, but there was a fibrous mass, ½ × 1 inch, to the right of the pituitary body, which surrounded the origin of the ophthalmic nerve, artery, and vein.

Pathological account and remarks. By J. HERBERT PARSONS.

Contents of right orbit, with lids, received in 10 per cent. formol. The globe is proptosed down and in. There is a large mass above, yellow in section, of firm consistency, but not so hard as cartilage. This invades the upper lid, and fills the upper part of the orbit as far back as the probable position of the optic foramen. The lower part of the orbit is not much involved. The optic nerve passes through intact in its sheath, but the normal S curve is much exaggerated.

The globe and tumour were frozen, and bisected by a sagittal section, which passed between the disc and macula.

Macroscopic examination.—Cornea ulcerated near the centre, bulging slightly, iris adherent. Anterior chamber absent above, where iris is adherent to cornea; shallow and slit-like below. Iris adherent to cornea above from periphery to near pupillary margin; pupil free, constricted. Lens shrunken, *in situ.* Retina œdematous, *in situ.* Choroid *in situ.* Optic disc swollen.

The growth is 25 mm. thick, measured in a direction up and back. It consists of dense fibrous tissue, which is looser near the globe, in the situation of Tenon's capsule. Running through it are several large convoluted nerve-cords, varying in size, the largest being larger than the optic nerve itself.

Microscopic examination.—Cornea: epithelium irregular, shows development of true papillæ over whole area and general tendency to epidermal type, but no corneous layer has yet been formed; Bowman's membrane destroyed throughout; anterior layers of substantia propria densely infiltrated with round cells; vascularised; posterior laminæ intact, œdematous, and slightly infiltrated; Descemet's membrane and endothelium intact, except

where iris is adherent. The perforation is filled with a mass of granulation tissue, containing uveal pigment, and covered by ill-developed epithelium. Anterior chamber: both angles blocked by adhesion of iris to cornea at the periphery. Iris infiltrated and degenerated, especially where adherent to cornea; it is wholly disorganised in the situation of the corneal perforation. Ciliary body atrophic. Retina degenerated; the layers are readily recognisable, including the rods and cones, but there is some infiltration of the nerve-fibre layer, especially

FIG. 8.

Showing the contents of the orbit removed by operation.
A. The globe of the eye.
B. The enlarged optic nerve.
The rest of the mass consists of nerves thickened and tortuous from fibromatosis.

around the vessels, and some degeneration of ganglion cells. Choroid congested and moderately infiltrated. Optic disc swollen, and much infiltrated upon the surface. Optic nerve shows some infiltration along the trabeculæ, but little degeneration; the intervaginal space is dilated, the arachnoid being infiltrated and swollen, showing also proliferation of the endothelium.

The growth consists of coiled and convoluted nerves of the most various sizes, surrounded by dense fibrous tissue, which infiltrates the orbital tissues, fading off imperceptibly into the orbital fat, etc. Portions of the tumour were mordanted in chrome-alum solution, stained with Kultschitzky's acid hæma-

toxylin, and differentiated in the same author's solution of potassium ferricyanide in lithium carbonate. It was then seen that the nerve-cords consisted almost entirely of enormously hypertrophied sheaths, the nerve-fibres being intact or, as seemed undoubted in some cases, degenerated. The proliferation affects the endo- and perineurium most, the epineurium least. The ciliary nerves are affected before their entry into the eye, but not afterwards in this case.

A few curious bulbs were found, resembling end-organs. They were situated not near the surface, but deep in the

FIG. 9.

Showing the structures suggestive of end-organs described in the text. × 120.

tissues; they were found in only a few sections, and could not be discovered in the sections stained by the Weigert method. They consisted of a thin laminated capsule, with numerous nuclei between the layers. The body within this, stained with eosin, appeared to be convoluted, as shown by fine wavy lines, was separated slightly from the capsule (? an artefact), possessed a few nuclei limited to the periphery, and in one or two places dark bodies like nuclei more deeply situated. The latter recall

the bodies described by Shattock in the terminals of nervi nervorum. I am not prepared to say definitely what these curious bulbs are. There can be little doubt that they are nerve endings. They are not superficial conjunctival ones; hence they must be either nerve endings of nervi nervorum or of tendons, since they do not at all resemble those of muscle. As regards the first, they are neither situated in the epineurium (cf. Horsley)[1] nor within the perineurium (Shattock).[2] True end-bulbs have been observed in tendons, but are not the most common form of termination. It is unfortunate that they were absent from the Weigert sections examined. A few bodies rather like them were found in the thickened nerve-sheaths, but they were far less definite. It is interesting to remember that somewhat similar bodies led Shattock to specially examine multiple neuro-fibromata and molluscum fibrosum for them.

The upper lid was enormously swollen, the increase in tissue being principally upon the posterior or conjunctival side, resulting in marked ectropion. This increase of growth consisted of the same masses of convoluted nerves, covered by inflamed conjunctiva; the nerves were generally smaller than the orbital ones. The other tissues of the lid exhibited mere œdema and congestion, great dilatation of the subdermal lymphatics being a marked feature.

Plexiform neuroma (Verneuil [1]), cirsoid neuroma (Bruns [2]), or elephantiasis neuromatodes of the lids is very rare; in the orbit it is still rarer.

Billroth (3) in 1863 described such a tumour of the right upper lid spreading to the temporal region in a boy of six; in 1869 he (4) described another, in a young man of eighteen, which was congenital, as large as the fist, and involving the left upper lid and temple.

Bruns (2) reported three cases; one in a man aged twenty-eight, and the others in two brothers, in both of whom there was general neuromatosis, with multiple neuromata of the vagi in one.

Genersich (5) in 1870 reported the case of two brothers. In one there were multiple neuromata of the 3rd, 4th, 5th, 7th,

[1] Horsley, 'Proc. of the Med.-Chir. Soc.,' 1884.
[2] Shattock, 'Trans. Path. Soc.,' xliv, p. 151.

9th, 11th, and 12th nerves; in the other a swelling occurred, after an injury, in the right side of the forehead, involving the eyebrow.

Marchand (6) in 1877 described a plexiform neuroma of the left upper lid and temple, noticed at the age of six months; there was ptosis.

FIG. 10.

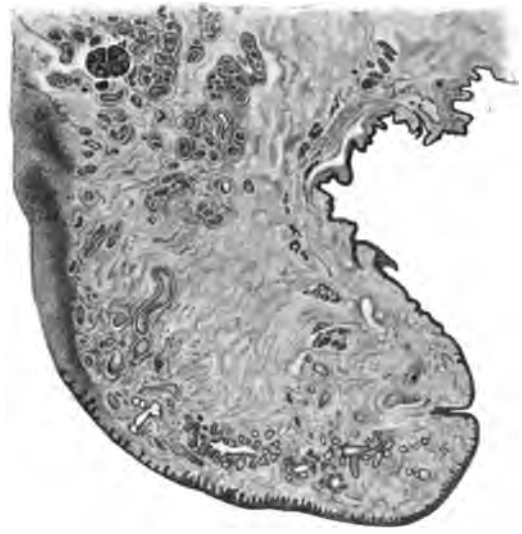

A section of the upper eyelid. It is considerably swollen from œdema, but presents, in addition, many fibromatosed nerves, some single, others (as at the upper part of the figure) in close groups. × 4½.

V. Recklinghausen (7) in 1882 published a book on 'Multiple Fibromata of the Skin, and their Relationship to Multiple Neuromata.' In one case there were multiple neuromata of the frontal and supra-orbital nerves, the 1st, 2nd, 3rd, and 4th cranial nerves being free. In another there was a small nodule at the edge of the left eyelid.

Herczel (8), in 1890, related the following case:

A boy aged 9 had a mother's mark on the left arm, which spread over the whole flexor surface, and had an increasing swelling at the upper part; there was a similar one over the left clavicular fossa. The left pupil was wider than the right,

and the left upper lid swollen; slight ptosis. There was a varicose swelling over the supra-orbital margin of the same side.

De Schweinitz (9), in 1891, reported a neuro-fibroma of the right upper eyelid and adjacent temporal region in a man aged twenty. There was ptosis and thickening of the upper lid. The swelling was noticed at birth, and gradually increased, with development of slight pigmentation of the skin. In the eyelid the epithelium was thickened, the sebaceous glands were hypertrophied, and there was wide dilatation of the lymph spaces. The growth consisted of "concentric whorls of loose, fibrous connective tissue, containing many nuclei, and in their centre medullated nerve-fibres, sometimes intact, and sometimes partially destroyed by fatty degeneration."

Jacqueau (10), in 1896, described a gradually increasing plexiform neuroma of the right upper lid and temporal region, causing ptosis and interference with vision.

Sachsalber (11), in 1897, gave a very exhaustive account of a case of plexiform neuroma of the orbit, with secondary buphthalmos, in a child of seven, the growth dating from birth. The whole of the left side of the face was enlarged, the bones being also involved. Defects in the outer wall of the orbit could be felt. The skin over the tumour showed the thickening of elephantiasis. The growth was made up of coils of enlarged and varicose nerves, lying in a mass of fibrous tissue.

Bruns (12) also recorded a case involving the orbit.

Katz (13), in 1898, carefully described a plexiform neuroma of the right upper lid and orbit in a girl of twelve, who was apparently healthy until three years old, when she fell down twelve stairs, injuring the right side of her head. A swelling appeared in the right lid and gradually grew.

Emmanuel (14), in 1901, discusses the relationship between optic-nerve tumours and elephantiasis neuromatodes, and their resemblance to the fibromatosis of elephantiasis has been previously insisted on by Byers (15).

Snéguirew (16), in 1900, reports a neuro-fibroma of the skin of the eyelid and head in a woman of twenty-four. It was situated, as usual, on the side of the forehead (L.), and involved the upper lid and cheek, extending back to the ear. The microscopical appearances with hæmatoxylin and eosin, and with Pal, were typical. There was no basement membrane to the ducts of

the sweat-glands; the other glands were normal. Many nerve-fibres without sheaths were free in the connective tissue, which confirms an observation of v. Recklinghausen's. The latter's views are also confirmed by Kriege (17) and Unna (18).

The whole subject has been discussed in a monograph on 'Neuroma and Neuro-fibromatosis,' by Alexis Thomson (1900). Many other cases (sixty-two in all) of plexiform neuroma are recorded there, affecting many parts of the body, but implication of the orbit is conspicuous by its absence. The author points out the intimate relationship between the following conditions:

(1) Multiple neuro-fibromata (generalised neuro-fibromatosis).

(2) Plexiform neuro-fibroma (plexiform neuro-fibromatosis).

(3) Molluscum fibrosum (cutaneous neuro-fibromatosis).

(4) Elephantiasis neuromatosa.

(5) Pigmentation of the skin associated with neuro-fibromatosis.

(6) "Secondary malignant neuroma" (Garré, 21), being the sarcomatous transformation of one or other form of neuro-fibromatosis.

It may be noted that in twenty-six of the recorded cases of molluscum fibrosum the lesion was combined with tumours of the nerve-trunks in twenty-two, with pigmentation of the skin in sixteen, with plexiform neuro-fibroma in six, and with elephantiasis neuromatosa in two cases. Molluscum fibrosum may also be associated with pigmented and other moles of the skin.

In regard to the general histology and distribution of plexiform neuro-fibroma, the plexiform arrangement of the nerves can be made out by simple dissection. Long continuous nerve-cords with moniliform enlargements of various sizes and shapes can thus be easily isolated from the surrounding loose, œdematous connective tissue.

Sections of such tumours, stained by hæmatoxylin and eosin, demonstrate the general relationships of the nerves; but special staining methods, particularly Weigert's medullary-sheath stain and its modifications (Pal, Kultschitzky, etc.), are necessary to demonstrate the condition of the nerve-fibres and sheaths. In specimens hardened in Müller's and other chrome solutions this is easy, but most specimens are now hardened first in formol. With these the only essential is that they shall not first be treated with alcohol. Formol-hardened tissues should be laid

for a few days in one of the bichromate-chrome-alum solutions (*e.g.* Ford Robertson's); celloidin sections will then show the Weigert reaction well. I have myself found Kultschitzky's method quite satisfactory. Ehrlich's and the Biondi-Heidenhain triple staining solutions, as well as Finotti's method, give good results (Sachsalber).

The histological characters of plexiform neuromata were thoroughly investigated by Ziegler and Baumgarten in Bruns' specimens, and their observations have been confirmed by Goldmann, but various explanations have been adduced. V. Recklinghausen regards the origin of the fibromatosis as the sheaths of the vessels, and especially of the nerves; Kriege and others the sheaths of the cutaneous nerves; Lahmann and others the sheaths of the sweat-glands and hair-follicles; Jordan and Finotti the sheaths of the vessels. Finotti says that "the primary disease is in the nerves, and that this affection of the nerves causes trophic disturbances, as the result of which proliferation of the connective tissue of the sheaths of the vessels and fibromatosis of the skin and subcutaneous tissues ensue."

The nerve-fibres themselves are often intact, although displaced and dissociated; on the other hand, they are also said sometimes to degenerate, and even disappear (Baumgarten). In the specimen which I have examined there certainly appears to be some degeneration. Goldmann and Alexis Thomson regard this as altogether exceptional. The most important change found is the proliferation of connective tissue within the primary bundles of nerve-fibres; but whilst some bundles escape altogether, others are much affected. Central and peripheral bundles are affected indiscriminately. Longitudinal sections show areas of normal nerve running into bands of wavy dissociated fibres, the degree and distribution of hyperplasia and dissociation determining the amount of deviation and curvature of the nerve. Nearly all authors agree that the endoneurium is most affected, the perineurium much less or not at all, whilst the epineurium is more compact, and is free from the normal fat-cells. The tissue is œdematous, with numerous lymphocytes and other cells, some about twice the size of a red corpuscle, with a small round nucleus and finely granular protoplasm; these may be proliferated endothelial cells (Finotti). The tissue is well supplied with blood-vessels.

Some authors consider that motor nerves only are affected (Sachsalber), but this is certainly erroneous. It is equally erroneous that only sensory nerves are involved. Out of forty-five cases, for example, of generalised neuro-fibromatosis examined by Alexis Thomson, cranial nerves were affected in about two thirds, and none of these were exempt, the vagus (twenty-nine) and trigeminal (twelve) being most commonly involved.

"The spinal and peripheral nerves would appear to be invariably affected" (Alexis Thomson). On account of the special character of the olfactory and optic nerves, as being outgrowths of the brain, true neuroma in these cases demands more thorough investigation, and may well be doubted. The sympathetic system seems specially subject to the disease.

Plexiform neuro-fibromatosis, in fifty-six collected cases, affected the temple, forehead, and upper eyelid in eighteen cases, and the posterior part of the neck and behind the auricle in fourteen cases (Alexis Thomson). It was associated with multiple neuromata in twelve of Bruns' cases, and in thirteen out of twenty collected by Alexis Thomson. It was associated with molluscum fibrosum in about the same proportion of cases.

References.

1. *Verneuil.*—'Arch. gén. de Méd.,' xviii, 1886.
2. *Bruns.*—'Virchow's Archiv,' l, p. 80, 1870.
3. *Billroth.*—'Archiv f. klin. Chirurgie,' iv, p. 547, 1863.
4. *Billroth.*—Ibid., xi, p. 232, 1869.
5. *Genersich.*—'Virchow's Arch.,' xlix, 1870.
6. *Marchand.*—Ibid., lxx, 1877.
7. *V. Recklinghausen.*—'U. die mult. Fibrome der Haut u. ihre Beziehung z. d. mult. Neuromen,' Berlin, 1882.
8. *Herczel.*—'Ziegler's Beiträge,' viii, p. 38, 1890.
9. *De Schweinitz.*—'Trans. Amer. Ophth. Soc.,' xxvii, p. 48, 1891.
10. *Jacqueau.*—'Gaz. hebd.,' 27 févr., 1896.
11. *Sachsalber.*—'Deutschmann's Beiträge,' Heft 27, p. 523, 1897.
12. *Bruns.*—Bruns' 'Beiträge z. klin. Chir.,' viii.
13. *Katz.*—'Arch. f. Ophth.,' xlv, p. 153, 1898.
14. *Emmanuel.*—Ibid., liii, p. 129, 1901.
15. *Parsons.*—'Trans. Ophth. Soc. U. K.,' xxiii, p. 116, 1903.
16. *Snéguirew.*—'Archiv. d'Opht.,' xx, p. 375, 1900.
17. *Kriege.*—'Virchow's Arch.,' cviii, 1887.
18. *Unna.*—In 'Orth's Pathologie,' Berlin, 1894.
20. *Alexis Thomson.*—'Neuroma and Neuro-fibromatosis,' Edinburgh, 1900.

21. *Garré.*—Bruns' 'Beiträge z. klin. Chir.,' ix.
22. *Goldmann.*—Ibid., x.
23. *Lahmann.*—'Virchow's Arch.,' ci.
24. *Jordan.*—'Ziegler's Beiträge,' xviii.
25. *Finotti.*—'Virchow's Arch.,' cxliii.
26. *Snell and Treacher Collins.*—'Trans. Ophth. Soc.,' xxiii, p. 157, 1903.

May 19th, 1903.

---

5. *A new method of counting the corpuscles of the blood.*

By W. Mersh Strong and C. G. Seligmann.

The following method of counting the white and red cells of the blood has been worked out primarily with a view to obtaining permanent preparations from which white and red cell counts can be made at any subsequent period. We also aimed at dispensing with the use of a ruled counting chamber, thus eliminating a considerable source of error due to variations in the depth of the cell.[1] We believe that our method will be of especial use in the tropics, where it may be necessary or advisable to examine the blood collected at the same time from a number of patients, and where skilled assistance is not available.

In principle our method consists in diluting a measured quantity of blood with a measured quantity of a fixing solution with which there is combined a suitable stain. After a few minutes, to allow of fixing and sufficient staining of the corpuscles, a measured drop of the mixture is allowed to evaporate to dryness on a slide, when a cover-glass is applied over the resultant film in the usual manner. We find balsam the best medium for mounting, and if the slides are to be kept for any length of time acid-free balsam dissolved in thiophene-free benzine should be used, as otherwise there is a tendency for the dye used for staining the white cells to become faint with age. A number of experiments were made in which various stains

[1] Two Zeiss slides which had been in use in the clinical laboratory, St. Thomas's Hospital, for about three years, and in which the ruled lines were everywhere perfectly clear and sharply defined, gave results which were fairly consistently 10 per cent. higher than those obtained by our method and by two new Zeiss slides. This would be accounted for if the depth had increased by only 0·01 mm.

were tried. Many of these gave tolerable results, especially polychrome methylene blue and picro-nigrosin, but it was finally determined that the most satisfactory results were obtained by using solutions of methyl violet and eosin for the white and red cell counts respectively.

Details of Method.

The finger or lobe of the ear, cleaned in the usual manner, is pricked, and 5 c.cm. of blood sucked into a Hawksley pipette of the usual pattern. This is then blown out into a suitable vessel (we have found a small weighing bottle most convenient) containing 495 c.c. of the first diluting fluid, consisting of—

Sodium chloride	**0·15**	**grm.**
Methyl violet	**0·012**	**grm.**
Formalin (commercial)	**1·5**	**c.c.**
Distilled water to	**100·0**	**c.c.**

This is the composition of the actual mixture used for counting the white cells, but as the practical value of our method would be greatly diminished were it frequently necessary to weigh out 0·012 grm. of methyl violet and an even smaller quantity of eosin, we proceeded to make a number of stock solutions which, when mixed in sample proportions, gave a solution of the same composition. These are the solutions of salt, formalin, and methyl violet mentioned below. As a matter of fact we found that the actual fluids used for diluting the blood kept perfectly well for about three weeks, provided they were not exposed to light and contained neutral formalin.

The solution used as a staining diluent to count the white cells, and which corresponds in composition with the formula given above, consists of a mixture of 12·5 c.c. of a 3 per cent. solution of NaCl, 12·5 of a 6 per cent. formalin (commercial), both in filtered distilled water, 495 c.mm. of a 1·3 per cent. solution of methyl violet, the whole made up to 50 c.c. with distilled water. A similar solution is used as a diluent for the red cell count, except that 495 c.mm. of a 0·8 per cent. solution of eosin (Grubler, w.g.) is substituted for the same quantity of methyl violet solution.

In practice we have given up using stock solutions, and now

make use of tabloids[1] containing the requisite amount of dye and salt, which, when dissolved in water, require only the addition of formalin. We take this opportunity of thanking Mr. Edmund White, Pharmacist to St. Thomas's Hospital, for making these tabloids for us, each of which contains 0·25 gramme pure sodium chloride combined with 0·004 gramme methyl violet or 0·0025 gramme of eosin. To make the diluent solutions all that is necessary is to dissolve one tabloid in 30 c.c. of clean distilled water and add 0·5 c.c. formalin, filtering the solutions so obtained through a not too large filter-paper, so that the strength of the dye in solution may not be appreciably weakened by the absorbing power of the paper.

White Cell Count.

The mixture of blood and methyl violet diluting fluid is well stirred and 5 c.mm. are drawn into a pipette and carefully blown on to a slide, so as to form a drop some 10 mm. to 12 mm. in diameter. Care must be taken to avoid leaving an appreciable quantity of fluid at the end of the pipette. Another possibility is that bubbles of air may be forced into the drop while blowing it on to the slide. A little practice is all that is required to avoid this, but should it occur the slides need not be rejected unless the bubbles burst, and scatter minute droplets of the mixture beyond the periphery of the main drop.

Since the ordinary Hawksley 5-c.mm. pipettes are graduated to contain but not to deliver 5 c.mm., special pipettes must be used or a correction applied. Special pipettes[2] have been made

[1] Messrs. Parke, Davis, and Co. have made a number of these tabloids for us, which are in every way satisfactory. It is probably important that the sodium chloride used should be free from magnesium chloride on account of the hygroscopic properties of the latter. The formalin used must be neutral, and should before use have stood over $CaCO_3$ or MgO, and have been adequately filtered—that is, through two thicknesses of filter-paper. Messrs. Griffin have put up for us a number of bulbs, each containing 0·5 c.c. of formalin so prepared, which have kept well. For preference the bulbs should be of non-actinic glass, and should contain but little air above the fluid. The small weighing bottles referred to above are stocked by Messrs. Allen and Hanbury.

[2] These are of the ordinary pattern, but graduated to deliver 5 c.mm. contained between a mark on the pipette's stem and its point. A pipette graduated so as to deliver 5 c.mm. when the meniscus of contained fluid passes from one mark on its stem to another seems to offer certain advantages, and we are experimenting in this direction.

for us by Mr. Hawksley, and these no doubt should be used for preference, but as the result of a large number of calibrations done by one of us (W. M. S.), we find that for all practical purposes it is sufficient if we made a delivery mark on the Hawksley 5-c.mm. pipette, such that the total new length of the graduated part of the tube becomes one-sixteenth greater than

FIG. 11.

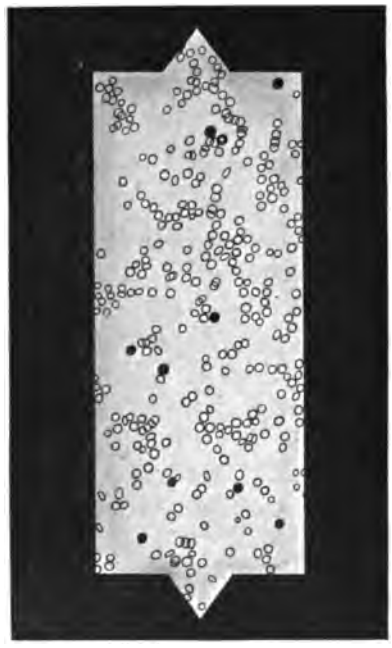

Film showing white cells deeply stained among unstained red cells. From a case with 20,640 leucocytes per c.mm. = 1032 leucocytes in film.

its length when graduated in the ordinary way to contain 5 c.mm. This increase in length probably varies a little with pipettes of different lengths; but in the case of a pipette of ordinary length of from 5 to 6 cm. from point to containing mark, one sixteenth is an allowance quite accurate enough.

The actual count of the white cells is done with one sixth inch objective. On examining the film consisting of a dried drop of the mixture of blood and diluent already described, red cor-

puscles are seen plentifully distributed all over the preparation. Among these the white cells form fairly conspicuous objects stained of a violet-blue colour, and easily differentiated from the red cells among which they lie (Fig. 11).

Crystals of salt will be seen scattered throughout the preparation.[1] At the edges of the drop the crystals are more numerous, and generally there is a slight deposit of dye producing a coloured edge. Here also the red corpuscles may be slightly stained.

A lightly stained red cell is to be distinguished from a white cell by its concentric staining, and especially by its non-refrac-

FIG. 12.

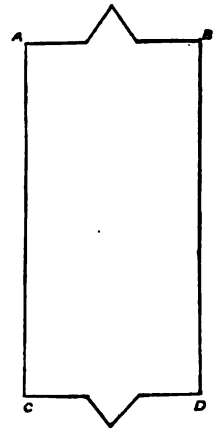

tive appearance. Even if a red cell is deeply stained it differs in tint and appearance from a leucocyte, so that usually there is no difficulty in determining whether a given corpuscle is a stained red or white cell.

In a satisfactory slide there should be no, or at least no appreciable number of stained red cells. If the mixed formalin and methyl violet stand for some time exposed to light the red cells readily begin to stain, doubtless owing to the formalin being partly oxidised to formic acid; and if the blood diluted with the methyl-violet solution be allowed to stand for some hours the red cells tend to stain. We have, however, obtained

[1] If the dried-up drop be mounted in oil of fennel with an index of refraction close to that of salt, the crystals of the latter become nearly invisible.

quite countable slides when the mixed blood and diluent have stood as much as two days before drying a drop of the mixture on a slide. At the other extreme as short a time as less than five minutes has been found to give a practicable stain.

For the actual count of the corpuscles an ordinary eye-piece with the usual circular diaphragm may be used, but an oblong field is more convenient. Best of all is an oblong diaphragm with two small notches cut in its opposite sides (Fig. 12). The

FIG. 13.

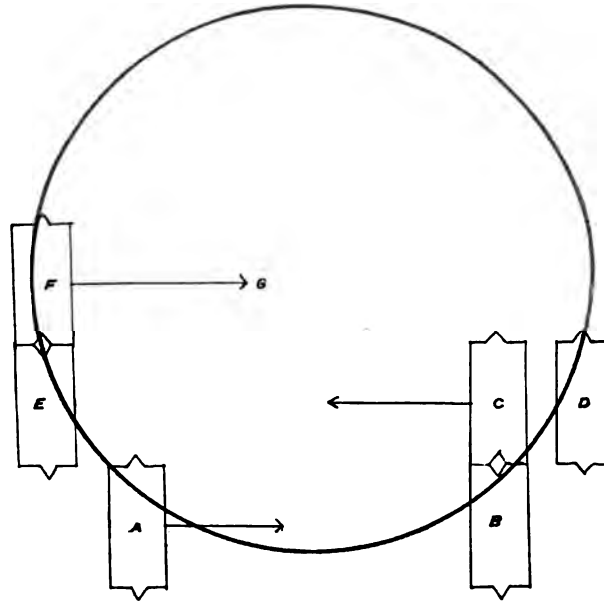

notches allow a doubtful corpuscle just on the edge of the field to be freely inspected. A field of this shape is readily procured by slipping a piece of paper cut to the right shape into the eye-piece of the microscope, or a blackened metal disc with a diaphragm of similar shape may be used.[1]

The first thing to do is to adjust the eye-piece so that one screw of the mechanical stage moves the corpuscles parallel to the notched sides (Fig. 12, A, B, C, and D) of the field. The slide is then moved until we see the apparent lower edge of the drop, as in Fig. 13, where A represents the first position of the field.

[1] Made for us by Messrs. Swift and Son.

By moving the horizontal screw of the mechanical stage the field moves to the position B, and all the (stained) white corpuscles seen are counted. This will be the most difficult line to count, since we shall be on an edge of the drop the whole time, and if the latter is not fairly circular in outline the existence of bays in its periphery may give rise to some confusion. When the field arrives at the position B the vertical screw of the mechanical stage is turned until the field takes up the position C. By turning the horizontal screw again the field comes to the position D. During the passage of the field from B to D the corpuscles are not counted. The field is now moved from D to E across the drop, and the cells seen are again counted, then from E to F without counting cells, then from F to G, and so on while cells are counted. These movements are continued until the whole of the drop has been worked over. The general principle of the above manœuvre is very simple—namely, each part of the drop must be counted once, and once only.

The time taken in counting a slide varies somewhat; we usually take about twenty to thirty minutes, beginners may take longer. A slide was counted satisfactorily in thirty-two minutes by a new observer, although it was his first experience of this method.

In making the first dilution the blood is ordinarily diluted a hundredfold, and the total number of white cells in 5 c.mm. are counted; hence the number of white cells per c.mm. is $100 \div 5 = 20$ times the number of white cells counted. In a count of a specimen of blood containing 10,000 white cells per c.mm., we should therefore count 500 cells, and since a high degree of accuracy in blood-counts is neither required nor attained by any method, a fair margin of error is permissible without introducing a really important inaccuracy in our result. For instance, if we were to leave out 50 cells in the above count, we should get as a result 9000 white cells instead of 10,000. In actual practice the error of counting a slide is far smaller than this.

Red Cell Count.

For this, the first (methyl-violet) dilution of the blood is well stirred, and 5 c.mm. are sucked into an ordinary (containing) pipette, and blown into a weighing bottle containing 995 c.mm.

of the eosin solution. The exact strength of the eosin solution is of no great importance, since within limits appreciably different strengths of eosin give equally satisfactory results; indeed, it is possible to count the red cells without any special staining at all by making the second dilution into the methyl-violet solution. After a few minutes to allow the red corpuscles to stain,

FIG. 14.



Film showing stained red cells. From a case with 6,684,000 red corpuscles per c.mm. = 1671 red corpuscles in film.

5 c.mm. of this dilution of the blood are transferred to a slide with a delivery pipette in the same way, and with the same precautions as in doing a white count. The drop is dried, and the film so obtained mounted under a cover-glass in Canada balsam.

When examined with a one sixth inch objective, the drop will be found to be bounded by a ring of precipitated amorphous eosin. Salt crystals will also be seen, especially near the edges, and scattered all over the drop stained red cells will be seen

(Fig. 14). These are counted in the same way as the white cells.

As already stated, the first (white cell) dilution made is ordinarily 1 in 100. For the second, a further dilution of 1 in 200 of this is made, so that the final dilution is 1 in 20,000. Since the total number of corpuscles in the drop, that is in 5 c.mm., are counted, the number of red cells per c.mm. is 20,000 ÷ 5 = 4000 times the number counted on the slide. In the case of a normal red count of 5,000,000 per cm., 5,000,000 ÷ 4000 = 1250 red cells would be counted, and even were an error of 50 cells made, the result would be out by only 200,000 cells per c.mm. The error of counting with ordinary care is never so large as this.

During the red count violet-stained cells are at times seen which without doubt are leucocytes. But we believe that, as a rule, the latter are stained red and are usually counted in with the red cells. In an ordinary count this is of little importance, since the number of white cells is incomparably smaller than that of the red. In a leukæmic count this might not be so. In this case we should count the total number of cells, both red and white, when counting the second dilution. Multiplying this by 4000, we should get the total cells, that is both red and white, in the blood, and we should then subtract the number of white cells per c.mm. as previously found. The result would be the number of red cells per c.mm.

Applicability of the New Method to Very High and Very Low Blood Counts.

While a dilution of 1 in 100 is usually convenient for the white count, yet occasionally—as in leukæmic cases—it may be desirable to further dilute the blood. We have done this by means of a pipette graduated to contain 55 c.mm. Then, on mixing 55 c.mm. of the first solution (1 in 100) with 495 cm. of methyl-violet solution, we obtain a total dilution of 1 in 1000, which should enable the leucocytes of any blood to be counted, however numerous they were.

With the ordinary first dilution of 1 in 100 we have counted as few as 1300 white cells per c.mm., with a total count on the

slide of 65 cells, and at the other extreme as many as 22,240 white cells per c.mm., with 1120 cells on the slide. A 40,000 count would give 2000 cells per slide. For any number above this it would probably be convenient to further dilute the blood ten times as above suggested. It should then be possible to conveniently count any number from about 20,000 to 400,000 white cells per c.mm. In the first instance 100, in the second 2000 cells would be counted in the film. With the ordinary red dilution of 1 in 20,000 we have counted as many as 7,306,000 red cells per c.mm., and as few as 840,000 cells per c.mm. In the first case 1829 cells were counted per slide, in the second case 210. Hence the above dilution appears to be convenient for all red counts, though for low counts a second dilution of 1 in 50 (instead of 1 in 200) may lead to more accurate counting.

Comparison of Results obtained by the New Method and with the Zeiss Hæmocytometer.

It remains for us to demonstrate the accuracy of the new method. With this end in view we cite a number of white cell counts made on the same specimen of diluted blood by three different methods.

Table I.

No.	Count by square field.	Count of total number in 5 c.mm. on a Zeiss slide.	Count of total number in 5 c.mm. dried on ordinary slide (new method).	Comparison.		
				A—B.	A—C.	B—C.
	A.	B.	C.			
1	5800	6000	5560	−200	+240	+440
2	3750	3560	3880	+190	−130	−320
3	1710	1540	1480	+170	+230	+ 60
4	7350	7340	7320	+ 10	+ 30	+ 20
5	6930	6540	6400	+390	+530	+140

The numbers in Column A were obtained as follows:—5 c.mm. of a $\frac{1}{100}$ dilution of the blood was taken in a 5-c.mm. delivery pipette, and blown into the counting chamber of a Zeiss hæmocytometer. The 5 c.mm. can just be contained in the

chamber of this apparatus when the special cover-glass is pressed on. The cover-glass was applied in the usual way, and care taken to obtain good Newton's rings. Failing good rings, a fresh specimen was mounted. Ehrlich's adjustable square eyepiece was used, and the size of the field so adjusted as to contain sixteen of the small ruled squares on the Zeiss slide. This square field was moved over as much as possible of the whole slide, while the number of white cells in each field and the number of fields traversed were noted. Then, knowing the dilution of the blood, the area of a small square ($\frac{1}{400}$ square millimetre), the depth of the cell ($\frac{1}{10}$ mm.), the number of fields and the total number of white cells counted, the number of white cells per cubic millimetre in the blood is readily calculated. The numbers so obtained are given in Column A.

Next, the total number of white cells in the whole of the 5 c.mm. on the slide was counted by going over the whole of the Zeiss slide. Then since the dilution of the blood is 1 in 100, and the total number of white cells in 5 c.mm. of this dilution is known, the number of leucocytes per c.mm. is $100 \div 5 = 20$ times the total number of white cells enumerated. The number of white cells per c.mm. obtained in this way is given in Column B.

Five cubic millimetre drops of the same dilution were taken in a delivery pipette, blown on to ordinary slides, dried, and mounted in Canada balsam. One slide was selected, and the total number of white cells in it were then counted as previously described, and the number per cubic millimetre was calculated. The results so obtained are given in Column C.

We wish to lay stress on the fact that these, as well as the red cell counts given later, are consecutive, not selected counts.

The general agreement of Column A and B may be taken to mean that the depth of the cell and graduation of the pipette are accurate, or at least that any errors present nearly balance each other. The general agreement of Columns B and C shows that appreciably the same number of corpuscles are counted in a 5-mm. drop, whether the drop is dried or not. If any appreciable number of white cells lose their stain on drying or became disintegrated, the numbers in Column C would be appreciably smaller than those in Column B. Considering numbers 1, 3, 4, and 5, it will be noticed that Column C is

always less than Column B. On working it out this amount is, however, only 3 per cent. Taking the algebraical percentage value of B—C for all five lines, Column B works out only 1·4 per cent. less than Column C.

This, we consider, conclusively proves that no appreciable loss of corpuscles takes place on drying the slide. The average dried slide which we obtain now is, moreover, distinctly better than the slides counted here, since we now avoid the effect of light on the mixed methyl violet and formalin solution.

With a view to demonstrate the accuracy of the new method for the red cell count, we cite five consecutive counts of different specimens of blood.

Table II gives a comparison between counts by the new method and by the Zeiss hæmocytometer method.

TABLE II.

No.	Count on Zeiss slide.	Count of dried drop.	A—B.	Percentage of error.
	A.	B.		
1	6,825,000	6,712,000	+113,000	+1·7
2	2,430,000	2,406,000	+ 24,000	+1·0
3	4,662,000	4,728,000	− 66,000	−1·4
4	3,737,000	3,584,000	+153,000	+4·9
5	4,450,000	4,324,000	+126,000	+2·9

In Column A are the number of red cells per c.mm. as found by counting in the ordinary way on a Zeiss slide. A dilution of 1 in 200 in the methyl violet diluting fluid was used for this purpose, eight large squares, each consisting of sixteen small squares, being counted.

For Column B 5 c.mm. of the first dilution were taken and mixed with 495 c.mm. of the eosin solution. This gives a final dilution of 1 in 20,000. From this dilution drops were blown on to slides from one of the specially graduated 5-c.mm. pipettes. These were dried and mounted in Canada balsam. One slide was selected and counted. Since the dilution was 1 in 20,000, and the total red cells in 5 c.mm. were counted, the total count multiplied by 20,000 ÷ 5 = 4000 gives the number

of red cells per c.mm. The numbers so obtained are given in Column B.

It will be seen that Columns A and B are approximately the same. On working out the difference Column B is found on the average to be 1·1 per cent. less than A. This may be taken as proving that few or no red cells are lost while the drop is drying.

May 15th, 1903.

---

6. *Some preliminary observations upon the agglutination reaction in cases of dysentery.*

By R. T. Hewlett.

(From the Department of General Pathology and Bacteriology, King's College, London.)

Since the introduction of the agglutination reaction many observers have tested the agglutinative power of the blood in cases of dysentery upon the various dysentery bacilli that have been isolated. Kruse, Shiga, and Flexner have paid especial attention to this reaction. Shiga claims that the bacillus isolated by him in the bacillary dysentery of Japan is agglutinated by the patients' blood, and Flexner makes the same statement with regard to his bacillus isolated in the Philippines.

Foulerton [1] found that four cases of dysentery contracted in the tropics gave complete agglutination reactions with Flexner's bacillus in dilutions of from 1 in 40 to 1 in 100. Three cases of disease arising in England and presenting the symptoms of acute colitis similarly reacted. Fifteen cases of typhoid and other diseases gave no reaction with these dilutions, but one or two gave a reaction when the dilution was low, viz. 1 in 10.

Vedder and Duval [2] came to the conclusion that the cause of acute dysentery, whether sporadic, institutional, or epidemic is the *B. dysenteriæ*, Shiga. They were able to isolate the *Bacillus dysenteriæ* from these different forms of dysentery, and the *B. dysenteriæ* was agglutinated by the blood of the patients in the

[1] 'Centr. f. Bakt.,' xxxi, 1902, "Originale," p. 205.

[2] 'Journ. of Exper. Med.,' vi, No. 2, 1902, p. 181.

various forms of the disease. From a study of the bacilli isolated by themselves, and compared with the strains of Shiga, Kruse, Flexner, and Strong, they came to the conclusion that with slight variations all these bacilli were identical.

Rosenthal,[1] testing thirty cases of dysentery in Moscow, found the agglutination reaction absent during the first week, marked from the tenth to the twelfth days, and diminishing after four or five weeks. In several fatal cases it was weak or absent.

Rogers,[2] working in India, has on several occasions isolated a bacillus conforming to the *B. dysenteriæ* type from cases of dysentery. The agglutination reaction was obtained in fifteen cases with his own bacillus, and also with a Shiga strain, the reaction being obtained in a dilution of up to 1 in 40, and in some cases 1 in 100. Rogers adds that six of these cases failed to react with a Flexner strain obtained from Europe. This last point is of interest in connection with my own earlier observations.

Vaillard and Dopter[3] investigated an epidemic of dysentery at Vincennes, and isolated a bacillus identical with that obtained by the above-named authors—that is, it was the *B. dysenteriæ* of Shiga and Flexner. They found the agglutination reaction to be well marked in their patients in dilutions of from 1 in 20 to 1 in 300.

Wollstein[4] examined a series of cases of infantile diarrhœa at the New York Foundling Hospital. Of the cases (39 out of 114), in which the stools contained both blood and mucus the *B. dysenteriæ* was found in all. The blood of these patients agglutinated the bacillus in twenty-one out of thirty-three cases. She remarks that the reaction was obtained with the bacillus isolated by herself, and also with the Harris (Manila) bacillus (which seems to be the Flexner strain), but never with the Shiga strain.

In my own work at first a culture of the Flexner bacillus obtained from the Jenner (now Lister) Institute was employed, but this was soon abandoned for one kindly sent to me direct by Professor Flexner. With this bacillus the results obtained were

[1] 'Deutsche med. Wochenschr.,' Feb. 5th, 1903.
[2] 'Ind. Med. Gazette,' Feb., 1903, p. 53.
[3] 'Ann. de l'Inst. Pasteur,' xvii, 1903, p. 463.
[4] 'Journ. of Med. Research,' x, No. 1, 1903, p. 11.

most disappointing, and in a few instances contradictory or obviously incorrect.

Eleven cases of dysentery were tested. None of these reacted, *i.e.* gave agglutination with one exception. In the exception plenty of the amœbæ coli were present in the stools. Several normal bloods, and bloods from cases of pneumonia (four), acute rheumatism, mild simple diarrhœa, severe simple diarrhœa, enteric fever (four), advanced phthisis (two) did not react. But in two cases of acute phthisis, and in one of Malta fever the reaction was obtained. It is true that owing to failure to obtain the reaction in well-marked cases of dysentery, low dilutions, viz. 1 in 20 to 1 in 30, were employed, and the reactions that were obtained in these non-dysenteric cases were probably due to this factor.

Nevertheless the fact remains that with dilutions of 1 in 20 to 1 in 30 several well-marked cases of dysentery failed to give the reaction, and the only case of dysentery that did react was one of the amœbic type. (It is, of course, possible that this was a double infection. A reaction has been obtained occasionally by Strong and Musgrave in amœbic dysentery, but is usually absent in this variety.) In a paper on the reaction of certain water bacteria with dysentery immune serum Bergey [1] remarks that the agglutination reaction could not be relied upon as a means of differentiating *B. dysenteriæ* from organisms that more or less closely resemble it unless the limits of agglutinating power of a particular serum be known, and found that the normal serum of the horse, rabbit, and dog contains agglutinins for a large number of organisms.

The following cases of asylums' dysentery (ulcerative colitis) were tested. All these bloods were from the Derby County Asylum, and were kindly sent by Dr. Richard Legge.

1. A female aged 61, ninth day of the disease.
2. A male, fourth day of disease.
3. A female, fifth day of disease. Described as a very typical case.
4. A male aged 21, suffering from imbecility. A typical case.
5. A male aged 52, suffering from chronic mania. A typical case.

[1] 'Journ. of Med. Research,' x, No. 1, 1903, p. 21.

None of these gave the reaction.

These results being so disappointing I wrote to Professor Flexner on the matter, and he very kindly again sent me cultures of the dysentery bacillus, one labelled 'Shiga' (Japan), presumably a sub-culture of the 'Shiga' strain, the other labelled 'Flexner' (Manila), and presumably isolated by Professor Flexner. With the last named, the *B. dysenteriæ* (Flexner), I have obtained much more promising results than before. The following are the cases I have tested up to date.

1. Dysentery; no amœbæ; marked clumping in dilution of 1 in 50 within one hour.

2. Dysentery; no amœbæ; ditto.

3. Dysentery; no amœbæ; feeble clumping with 1 : 50 dilution.

4. Dysentery; amœbæ present; no trace of agglutination.

5. Dysentery; chronic and probably amœbic; no trace of agglutination.

As regards asylums' dysentery, I have so far been able to test only two cases:

1. From the Surrey County Asylum. No details given. Marked clumping in a dilution of 1 in 50 within the hour.

2. From the Derby County Asylum. Female aged 72. Illness of fortnight's duration; typical. Has had previous attacks. Marked clumping in a dilution of 1 in 50, and distinct clumping in a dilution of 1 in 100 within the hour.

As stated, these results have been obtained with the Flexner strain of the *B. dysenteriæ*. I find also that this bacillus agglutinates with normal (*e. g.* my own) blood in a dilution of 1 in 20, but hardly in one of 1 in 30, so that it is necessary to work with dilutions greater than this (1 in 30).

As regards the Shiga strain of the *B. dysenteriæ* none of the bloods that I have tried agglutinates it even in dilutions of 1 in 20, neither my own blood nor the dysentery bloods that agglutinated the Flexner strain well. This coincides with the results obtained by Wollstein (*loc. cit.*) already quoted.

As regards these two strains of the *B. dysenteriæ* there is, morphologically and culturally, very little difference. I think the Flexner strain tends to be a trifle larger than the Shiga strain, and to be more active in the production of acid; although the ultimate result may be the same (I have not yet compared

the total amount of acid produced), the production of acid seems to be more rapid in the Flexner than the Shiga. These are the only differences to be noted between the two strains. Yet there is this profound difference in agglutinative properties.

More work will have to be done before we are in a position to decide the value of the agglutination test in dysentery, and the specificity of the *B. dysenteriæ*. *November 17th*, 1903.

---

7. *The estimation of bile salts.*

By Otto Grünbaum.

The tests for bile salts mentioned in text-books are three in number, and are ascribed to Pettenkofer, Oliver, and Matthew Hay.

The first is carried out by adding furfur aldehyde to the urine, and on gently warming a purplish-red colour develops; since this reaction needs the solution to contain one part per thousand of bile salts, it rarely if ever demonstrates their presence in urine.

Oliver's test consists in the addition of an acid solution of albumoses to diluted urine, the formation of a precipitate indicates the presence of bile salts.

Matthew Hay noted that the surface tension of urine containing bile salts was abnormally small, and that this diminution could be demonstrated by sprinkling flowers of sulphur upon the surface. Flowers of sulphur are not wetted by normal urine and do not sink, but sink immediately if the urine contains more than ·01 per cent. of bile salts. This test is very delicate, one part of bile salts in 100,000 of urine causing the flowers of sulphur to sink if allowed to stand for some time. This method permits of a rough estimation of the quantity of bile salts in solution by diluting until the flowers of sulphur only just sink immediately upon coming into contact with the urine. That the method does not permit of accuracy is obvious when the meaning of "just sink immediately" is duly considered. If another and more accurate method of measuring surface tension were

adopted a more accurate estimation of bile salts might be attained.

There are some number of methods of estimating the surface tension of a fluid. One of the most rapid depends upon the height a fluid will rise in a capillary tube; unfortunately the extreme difficulty of rendering capillary tubes chemically clean precludes this method.

The pressure necessary to form a drop at the end of a capillary tube depends upon the surface tension of the fluid; this method has been adopted by Whatmough[1] with signal success, but requires apparatus too complex for use in the wards of a hospital.

It occurred to me that the size of a drop would depend mainly upon the nature of the surface from which it fell, the surface tension, and the density of the fluid. If the drop be allowed to form slowly the viscosity of the fluid is not a factor in deciding the size of the drop. The two essential points in the method are—(1) The measurement of the drop; (2) A constant surface from which the drop is to fall. The drop might be weighed, but this would necessitate the use of an accurate balance and consume time. It was therefore found to be more convenient to measure the size of the drop by noting how many fell from the end of a pipette of known capacity on slowly emptying it.

The search after a suitable surface from which the drops might fall was fraught with much waste of time. Glass was tried, but the problem of keeping the surface clean was not solved. The surface of platinum and iridio platinum was found to alter, and the pipettes had to be repeatedly standardised. Threads of linen, cotton, and asbestos, tubes of paraffin were all tried without success.

At the suggestion of Professor H. Jackson I tried drawn quartz, a substance which fulfills all requirements. I had pipettes of 2 c.c. capacity fitted with fine hollow silicate needles, and noted the number of drops which fell from the needles on slowly emptying them.

The number of drops which fall from the standard pipette is 20 per cubic centimetre; this standard I could not adopt because it is essential that the drops be small, otherwise the

[1] 'Zeitschrift für Physikaliche Chemie,' 1902.

FIG. 15.

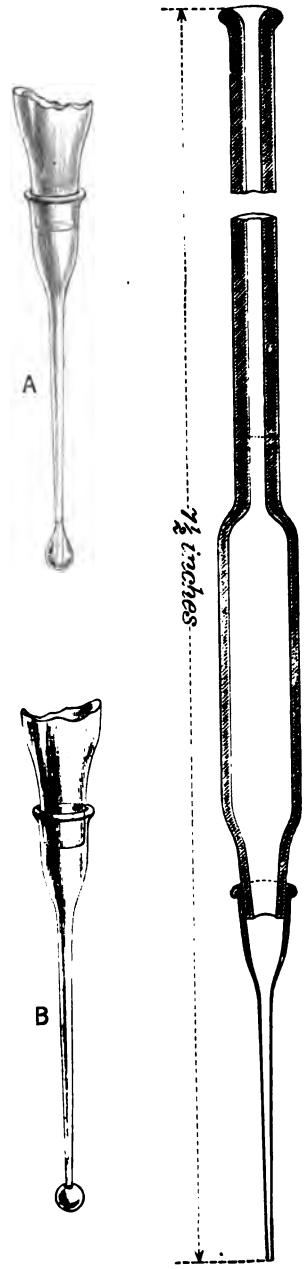

The pipette described in the text, with the silicate needle fitted to it. The actual length of the whole is 7½ inches.

A. The manner in which the drop falls if the needle is clean.
B. The manner in which the drop falls if the needle is greasy.

delicacy of the method is not great. The needle should be so fine that between 50 and 60 drops of water fall per cubic centimetre.

When the end of the needle is clean the drops fall as in A, Fig. 15, whilst if greasy, as in B, any intermediate stage may be assumed if the surface be not quite clean, it is therefore necessary to observe carefully that the drops form correctly and symmetrically. If this is not the case the end of the pipette must be boiled in a solution of sodium hydrate, and then well rinsed with water. It is true that the silicate needles may be cleaned by heating in the blowpipe without any fear of their melting, but it is unwise to adopt this method because in time it leads to their disintegration, which is shown by their losing their transparency, and when examined microscopically their surface presents a tesellated appearance, not unlike pavement epithelium. The drops must be allowed to fall slowly, not more than 40 in a minute. If the needle be long a small hand bellows may be attached to the pipette and gentle pressure exerted.

Temperature has a slight effect, and therefore it is necessary to work at a constant temperature.

Each pipette is standardised by noting the number of drops formed when using solutions containing a known quantity of bile salts; this permits the plotting of a curve for reference when estimating bile salts in urines under investigation.

With pipette (A) the following numbers were obtained when using sodium glycocholate, the purity of which has not been investigated.

Urine, 1010 sp. g., Temp. 60 F., containing	Number of drops.	Urine, 1010 sp. g., Temp. 60 F., containing	Number of drops.
·000 per cent.	123	·02 ,,	154
·001 ,,	125	·04 ,,	166
·002 ,,	127	·05 ,,	170
·004 ,,	132	·08 ,,	180
·008 ,,	140	·1 ,,	183
·01 ,,	144	·2 ,,	196

which leads to the curve given in the following chart.

The next question to arise is, do substances, other than bile salts, cause a fall in surface tension?

Beddard and Pembrey[1] showed that soap, acetone, alcohol, ether, and chloroform diminish surface tension, but they are not present in urine in sufficient quantities to lead to an appreciable error.

I took a large number of urines from cases suffering from nephritis, diabetes, etc., and found that when diluted to 1010 sp. g. and filtered they formed 123 drops on falling from pipette A.

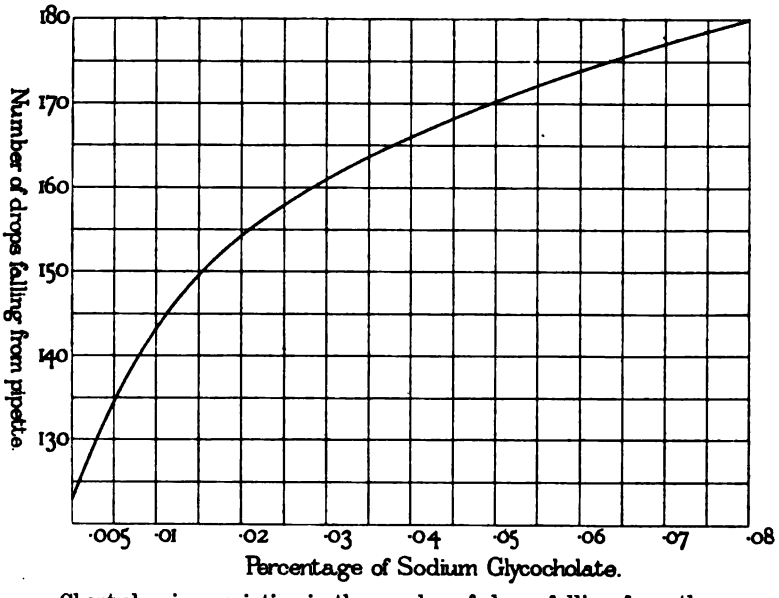

Chart showing variation in the number of drops falling from the pipette in correspondence with variation in the percentage of sodium glycocholate in urine.

The method of estimating is—

1. Filter.
2. Dilute to specific gravity of 1010.
3. Work at temperature at which pipette was standardised.
4. Note number of drops on slowly emptying pipette.
5. Note on curve the percentage of bile salt corresponding to that number.

This is but a preliminary communication; I trust to be able, at no far future date to record the results of investigations on the excretion of bile salts in various diseases, which we are pursuing at the London Hospital. *November 17th,* 1903.

[1] 'Brit. Med. Journ.,' 1902.

8. *Carcinoma of thyroid; metastasis in calvaria.*

By H. A. Lediard.

(With Plate I.)

It has fallen to my lot to operate upon a large number of cases of enlargement of the thyroid, for the district I practise in favours the production of goitre. I have, however, never met with a thyroid enlargement of apparently innocent nature which has shown any malignancy until now. Thus out of fifty operations on thirty-nine females and eleven males no secondary growths were manifest.

Rare as this malignancy may be, yet three examples may be found in the 'Transactions' of this Society, viz. one each by Henry Morris, Mr. Haward, and the late Joseph Coats. In all these three cases the skull was perforated by a tumour identical in structure with goitre tissue, and the skull tumour was secondary to a goitre, and in some cases the secondary growths had attacked other bones besides the cranium. In my case any further extension was checked by the result of surgical operation.

In Mr. Haward's case the bronchocele had existed for twenty-one years; in Coats's case the goitre was of sixteen years standing, and in my case the goitre had been recognised for years. Thus the most curious circumstance in the life-history of a goitre is that it may remain benign for a great length of time and then acquire malignancy and occasion secondary growths in the bones, selecting the cranium by preference.

In my case the primary goitre exhibits fibrous and calcarious degeneration, and, with this, is actively-growing gland-like carcinoma.

On March 14th, 1903, a female aged 42, was admitted into the Cumberland Infirmary on account of a tumour over the left frontal region, which had been incised under the belief that a sebaceous cyst was present.

The tumour was first noticed twelve months previously when it was the size of a nut, and gradually enlarged, but the increase had been rapid during the six weeks prior to admission to

hospital. Headaches, vertigo, and occasional vomiting were experienced before the tumour appeared, but not after. The neck had been thick for years, but she could not recollect the first onset. There were no tumours in the family, and she had not received any injury to the head.

The tumour occupied the left frontal region one and a half inches above the centre of the left supra-orbital ridge, and was the size of half an orange. There was also a moderately-sized bilateral goitre, which was not creating any dyspnœa.

On dealing with the skull growth it was found to spring from the bone, and that a large perforation with elevated and ragged edges existed at the base of the tumour. Much hæmorrhage being met with the tumour was rapidly removed below the level of the skull and the edges of the perforation trimmed with bone forceps.

I was under the impression that the tumour, owing to its pulsation, was connected with the subjacient brain, but this did not prove to be the case. For a week it seemed not impossible for recovery to take place, but a high run of temperature was noted, and death occurred on April 1st, or seventeen days after admission. Permission for a complete examination was denied, but I have here the skull-cap, the brain and dura mater, together with the goitre and sections of the skull tumour and the goitre.

Examination of the surface of the brain shows indentation at the site of the tumour, but no softening, and the dura mater at the same place is intact. Upon the outer surface of the dura mater is a flat new growth in the shape of a disc, some two inches in diameter. It was from this area that the tumour was removed during life.

Examination of the skull-cap shows a circular aperture in the left half of the frontal bone which measures about two and a quarter inches in diameter. Its posterior edge nearly reaches the coronal suture, and its inner edge abuts on the median line of the skull. The cranium is about three eighths of an inch in thickness at the site of perforation, and the margin is slightly bevelled at the expense of the outer table, as well as indented by the application of bone forceps.

Viewed from the anterior the margin of this aperture is bounded by a thin ridge of osteophytic outgrowths which consist of white, friable, spongy bone.

In the thyroid the following changes were seen:—Marked cirrhotic condition of the gland, the cirrhosis causing atrophy of the gland tissue. In localised areas definite necrosis with subsequent calcification. At parts active proliferation and new formation of glandular structure resembling that seen in exophthalmic goitre. Presence in the gland of an infiltrating carcinoma.

FIG. 16.

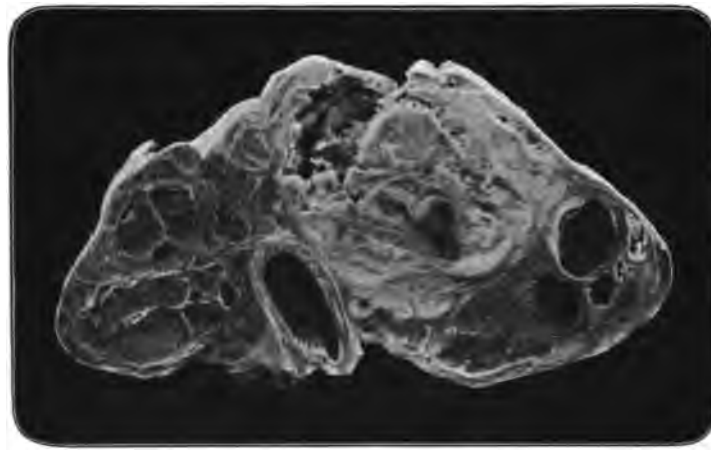

A transverse section of the thyroid, together with the trachea. In the goitrous thyroid is shown the infiltrating carcinoma, distinguishable by its whiter colour.

Microscopic structure of the thyroid gland.

The striking feature presented on examining sections of the gland is the amount of fibrosis throughout the gland.

Areas of apparently healthy gland tissue with tubules filled with colloid material, and other parts showing an active proliferation of the glandular tissue with very little colloid formation.

The thickening of the capsule and the septa is very marked, of a very dense fibrous structure, and contains arteries, veins, and nerves. At some of the more thickened parts calcification has taken place. Apparently a mass of the glandular tissue has been completely cut off from its blood-supply and has then undergone necrosis, followed by a deposit of lime salts into the

dead area. The fibrous bands are running throughout the section in an irregular manner, and cutting the gland tissue into masses of various sizes; much of the gland tissue is seen to have been caught in the fibrous overgrowth, these tubules being compressed and undergoing atrophy, and at some points completely destroyed.

The gland is in a condition of cirrhosis of a chronic nature. In parts of the gland proper many of the tubules contain the colloid secretion, and appear quite normal in size, with a few larger spaces also filled with colloid material. But a large part of the gland is composed of tubular elements with no colloid material in their lumen, and resembles very much the arrangement found in exophthalmic goitre by an active proliferation of the gland tissue, the new tubules being small and lined with cubical epithelium, the larger spaces lined with the same kind of epithelium, some of which show papillary ingrowths, others have their lumen filled with epithelial cells (catarrh), but there is a marked absence of the colloid secretion in these tubules. At one or two points in these proliferating areas one finds necrosis has taken place, in which both the tubules, with their capillaries and connective tissue, are embedded in the degenerative process.

The necrosed area is sharply marked off from the healthy, as seen by the loss of staining in many of the nuclei of the cells of the tubules in the affected part, although the structure of the tissue is still recognisable; it stains, however, more uniformly with the eosin.

At other parts of the proliferating areas are seen masses of altered blood-pigment: some of the masses appear to have been taken up by the connective-tissue cells, and others apparently are lying free in the lymphatic spaces. The pigment probably is the result of an old hæmorrhage.

In section taken from another part of the goitre is seen a rounded nodule, about three eighths of an inch in diameter, embedded in the thyroid tissue, and it appears quite distinctly demarcated from the surrounding thyroid tissue.

On microscopic examination the nodule is found to be a gland-like carcinoma growing in and infiltrating the thyroid.

The tumour is made up of glandular tissue, varying somewhat at different parts of the nodule, accompanied by connective

tissue, which also varies in amount and character; arteries and capillaries are present, but no nerves can be made out.

At the margin of the growth, and sharply separating it at parts from the thyroid, are to be seen thickened fibrous septa of the thyroid, which is being pushed before the growing mass; but at some points the tubules of the growth can be seen infiltrating this dividing line, and resemble tubules, which in structure appear to be a transitional stage between those of the thyroid gland and those typical of the new growth.

All round the periphery of the new growth the active proliferation of the tubules is well seen. They infiltrate and push before them the surrounding thyroid tissue, so that one gets the impression of a distinctly centrifugal growth.

The majority of the tubules of the growth are small, with a single irregular layer of epithelium, with very small lumen, or may be quite indistinct; the larger spaces are more regularly lined with cubical epithelium, and have a sharply defined lumen in which colloid material is present. These tubules are surrounded by a delicate connective tissue, rich in blood capillaries.

At the more central part of the growth are two or three rather large irregular areas of a hyaline fibrous overgrowth, which has greatly destroyed the tubular tissue, so that only a few of the tubules can be recognised, widely separated from one another. The arteries and capillaries are included in this hyaline fibrous tissue.

At one point the fibrous overgrowth is undergoing œdematous softening.

At another point the intertubular connective tissue is being replaced by colloid material forming a uniform matrix in which are embedded, but separated from another, the tubular elements of the growth.

These are secondary degenerative changes in the new growth.

Microscopical structure of the tumour of the skull.

A low power shows the tumour to have a thick fibrous capsule in which are large dilated blood-vessels, and in parts immediately below the capsule are spaces varying in size, with some of the larger ones filled with colloid material. The connective

DESCRIPTION OF PLATE I.

Illustrating Dr. H. A. Lediard's paper on "Carcinoma of the Thyroid." (P. 60.)

FIG. 1.—Showing an area of the simple goitre into which the carcinoma has not penetrated. The spaces are lined with a single layer of cortical epithelium, and are filled with colloid.

FIG. 2.—A portion of the goitre in which fibrosis has occurred, many of the gland spaces being small and atrophied.

FIG. 3.—Metastatic tumours of the calvaria, showing thyroid-like tissue, the gland spaces presenting a lumen holding secretion.

FIG. 4.—Portion of the carcinomatous growth within the goitrous thyroid, the young cell columns developing a lumen.

FIG. 5.—Showing in the upper part the advancing margin of the carcinoma, composed of cell columns with little or no lumen.

FIG. 6.—Portion of the carcinoma more highly magnified.

(From microphotographs.)

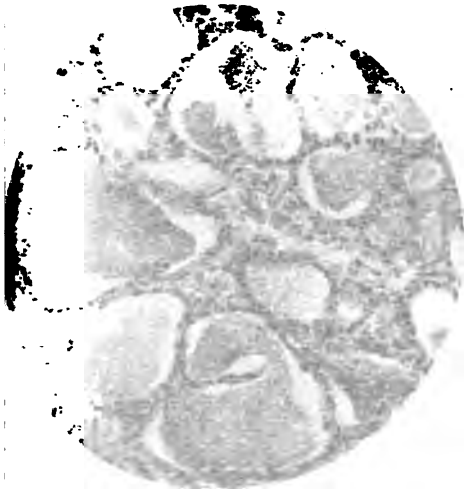

Fig. 1.



Fig. 2.

Fig. 3.



Fig. 4.

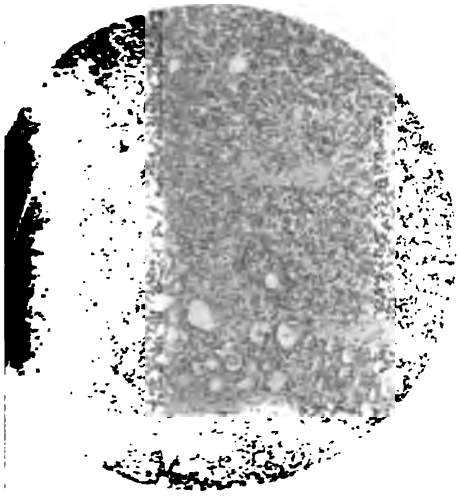

Fig. 5

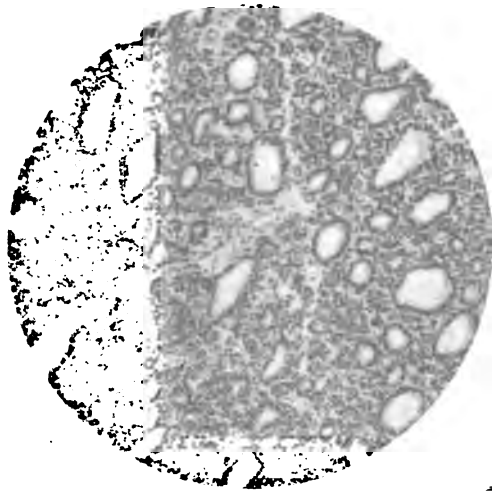

Fig. 6.

PLATE I.

[illegible] Carcinoma of the [illegible]

[illegible] which the carcinoma has [illegible] layer of cortical epithe- [illegible]

[illegible] has occurred, many of the [illegible]

[illegible] showing thyroid-like tissue, the [illegible]

[illegible] within the goitrous thyroid, [illegible]

[illegible] margin of the carcinoma, [illegible]

[illegible] magnified.

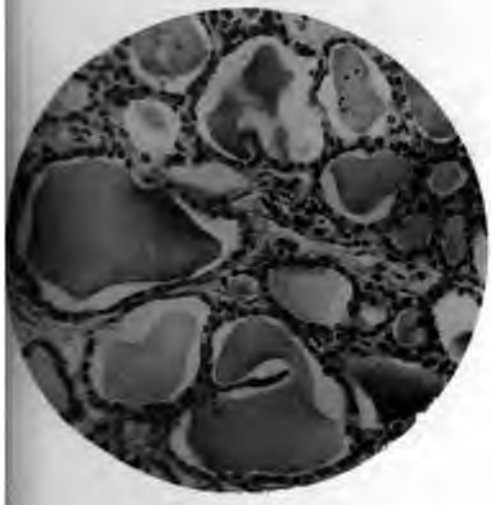

Fig. 1.

Fig. 2.

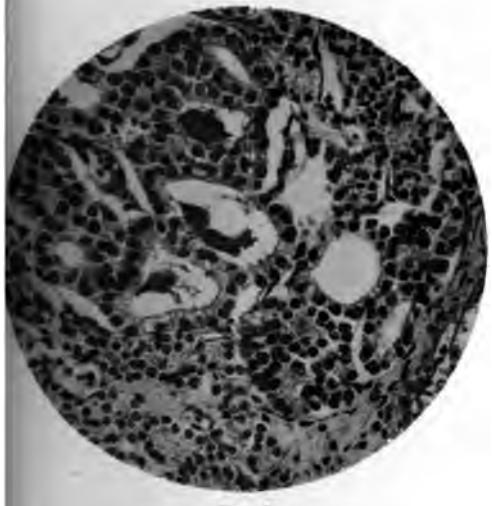

Fig. 3.

Fig. 4.

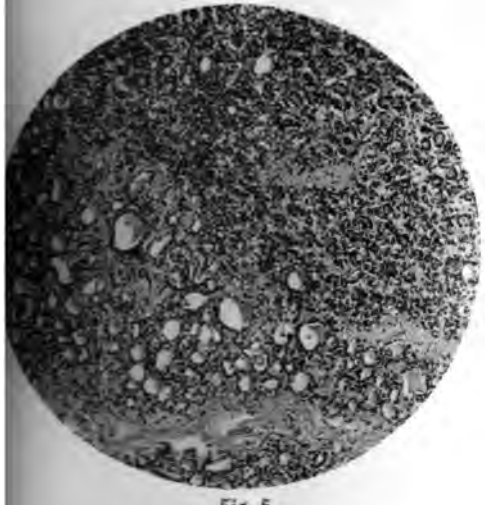

Fig. 5.

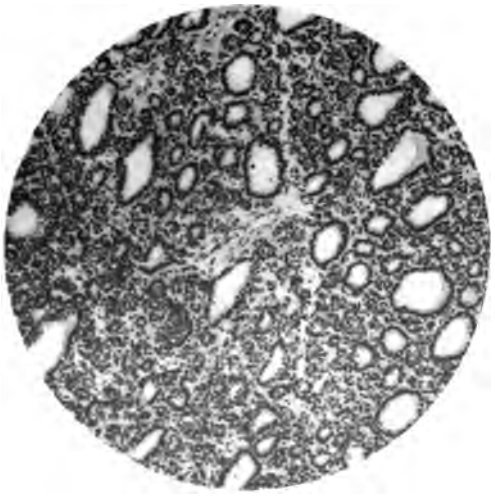

Fig. 6.

tissue between the vesicles is very scanty; this part of the growth closely resembles actively growing goitre tissue.

At other parts the tubules are separated by very cellular tissue resembling sarcoma. Areas at centre show marked necrosis of the tubules (loss of nuclear staining), also hæmorrhage in parts.

A high power shows many polymorphonuclear leucocytes in the vessels of the capsule, and apparently emigrating into the capsule. The spaces seen under the capsule are lined with epithelial cells, with some of the spaces distended with colloid substance, and running between the tubules are thin-walled capillaries with practically no supporting connective tissue; this part shows the characters of rapidly growing goitre tissue. At the cellular or sarcomatous-like part the tubular element of the growth is disorganised by numbers of leucocytes (polymorphonuclear).

The leucocytes have separated the tubules from one another have also penetrated into the lumen, have broken up the epithelium, and apparently absorbed large parts of the new growth.

There are parts which are completely replaced by the leucocytes; only the delicate connective tissue remains, showing the outlines of position of the tubules. The hæmorrhages, which are recent, have taken place both outside and in the necrosed areas; a few of the leucocytes are seen to have penetrated even to the centre of the necrosed area, but they appear little altered.

There has occurred a necrosis of the more central parts of the secondary growth, followed by an acute inflammatory condition, which has largely destroyed the structure of the thyroid tissue.

I have stated that, owing to an error in diagnosis, the tumour of the skull had been incised; the incision was associated with very free hæmorrhage, and the wound was packed.

I saw the patient later on the same day, but am responsible for a delay of forty-eight hours before further operation was attempted.

This delay allowed time for changes in the tumour which have altered its appearance. I allude to such changes as hæmorrhage and evidences of inflammation.* *December 1st,* 1903.

* Mr. James Berry has favoured me with the following reference relating to this subject: R. Jaeger, "Uber Strumametastasen," 'Beiträg zur klin. Chir.,' 1897, xix, pp. 493—526.

9. *Angioma arteriale racemosum; two cases.*

By J. H. Drysdale.

Case 1.—C. A—, male, a clerk aged 17, was admitted to St. Bartholomew's on October 4th, 1902. He was in his usual health on the day of October 2nd. During the night he was seized with abdominal pain, and shortly afterwards became drowsy.

On admission thirty-six hours later he was in a stuporose condition, but could be roused to answer questions. There was a foul discharge from the left ear. Some weakness of the muscles of the left side of the face and diminished movement of the left arm and leg were noticed. The knee-jerk on that side was more active than on the right. There was no optic neuritis.

On 5th and 6th he vomited several times. On October 6th signs of pneumonia appeared at the base of the right lung. On the 7th he vomited a very large quantity of brownish fluid, and died on the 8th October, having remained in the same stuporose condition throughout.

Previous history.—Four years before the patient had a fall on the head. He was unconscious for five or six hours, and confined to bed for five months. Some weakness of the left side remained after the accident, and for the last three years of his life he had been subject to epileptic fits.

At the *post-mortem* examination the lower lobe of the right lung was completely solid, and there was commencing consolidation in the upper and middle lobes of the same side and of the lower lobe on the opposite side.

The stomach was enormously distended, the cardiac end reaching as high as the fourth rib on the left side. The remainder of the organ occupied the whole of the front of the abdominal cavity, its lower margin reaching to within an inch or so of the symphysis pubis. The distension extended for some inches past the pylorus along the duodenum, and ceased abruptly without obvious cause. The remaining portions of the gut were collapsed, and lay partly behind the stomach and partly in the pelvis. The stomach contained a very large quantity of yellow pea-soup-like fluid, which was not frothy.

FIG. 17.

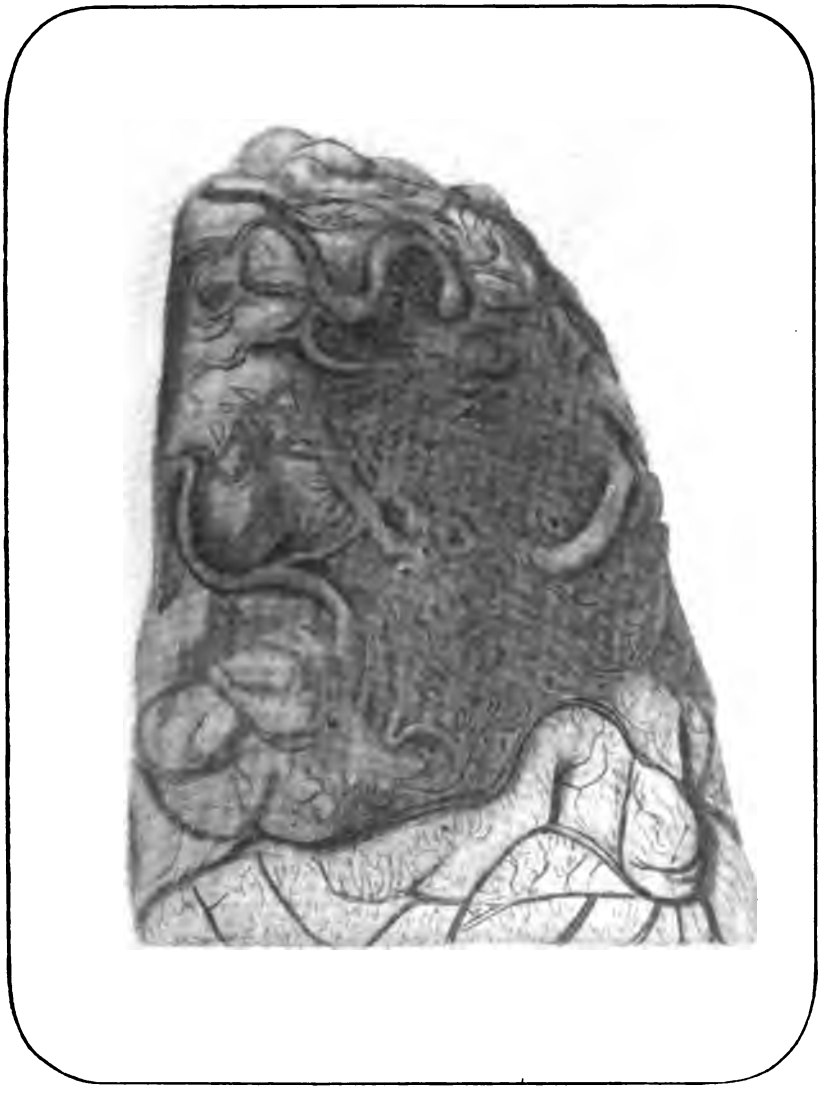

The anterior portion of the right cerebral hemisphere, showing the racemose arterial aneurysm described in the text. Case 2.

The peritoneum was dull and universally injected, but there was no free fluid nor any obvious lymph.

The scalp, the cranial bones, and dura mater were all healthy, as were the various sinuses.

On removing the dura mater from the vertex the whole surface of the brain visible appeared exceedingly congested. Though this appearance, on removal of the brain, was found to be general over the whole surface, yet the condition was much more marked on the right side, particularly over the superior parietal and ascending parietal convolutions externally, and the præcuneus and paracentral convolutions on the median surface. Over this area the vessels, which at the time of the *post-mortem* were regarded as veins, were enormously dilated and tortuous, forming an almost unbroken surface of spongy, blood-containing tissue.

On making, after hardening, a transverse section of the hemisphere at this spot, it was found that the process penetrated in wedge-shaped form deeply into the white matter, and terminated abruptly in a single round dilatation as large as a cherry, which occupied the situation of the lenticular nucleus without obviously encroaching on either the internal or external capsule. The "tumour" looked like a cavernous angeioma. See Figure, p. 69.

The middle cerebral artery on that side was of normal size at its origin, but on entering the Sylvian fissure became greatly and irregularly dilated, and, following its usual course and distribution, acted as the feeder, from this side, of the mass of enlarged vessels seen on the vertex.

Similarly, branches of the anterior cerebral vessels fed the mass of the median surface of the brain.

The arteries of the circle of Willis were of ordinary size, but the cortical branches were everywhere enlarged, so that the morbid tendency was not strictly circumscribed, though much more marked at the spot indicated.

Case 2.—Ethel S—, aged 26, was admitted to St. Bartholomew's Hospital under the care of Dr. Hensley on September 20th, 1903.

Family history.—Nothing of importance elicited.

Previous history.—Scarlet fever ten years ago. Epileptic fits since the age of fourteen. Fits infrequent, about fifteen in all.

History of the present condition.—Patient was in her usual health till 7 p.m. on September 19th. She then "fainted,"

FIG. 18.

A transverse vertical section of the preceding, showing the compact plexus of tortuous arteries in the substance of the brain. Case 1.

vomited, and passed a loose motion, and became unconscious, remaining so for twenty minutes. On recovering she walked upstairs to bed and slept till 11.30 p.m. On awaking she com-

plained of pain in her head, and was seized with a fit, accompanied by jerking movements of the limbs. She became unconscious again, and remained in this condition with slight movements till admission.

Condition on admission.—Semi-unconscious. Jerking movements of the right arm and leg. Paresis of the left side of the face. Respirations 28, pulse 68. Temperature normal. Chest and abdomen natural. The urine contained a cloud of albumen.

September 22nd.—Rigidity of the limbs, more marked on the left side. Temp. 100·8°.

September 23rd.—Less conscious; rigidity on the left side more marked. Temp. 100·6°.

September 24th.—Rigidity less. Deviation of the eyes to the right. Left pupil larger than right. Left leg lax, reflexes absent. Right leg rigid, flexor plantar response; K.-J. active.

September 25th.—Seems rather more conscious. Left facial palsy more marked. Temp. 103°.

September 28th.—Less conscious. Rigidity almost gone. No K.-J. or plantar reflex on either side. Temp. 105°, respirations 40, pulse 102. Profuse sweating. Temperature rose to 105·6°. The pulse became weaker, the respirations more frequent, and the patient died at 10.45.

P.M.—Scalp natural. Cranial bones rather thicker and denser than natural. Dura mater natural, not adherent to brain. Sinuses natural.

Brain.—On right side a large area of greatly enlarged tortuous vessels filled with blood obscured the surface of the brain, filling the sulci and covering the intervening convolutions. The area extended forwards from the Rolandic fissure, and was limited, though not quite strictly to the convex surface of the brain (Figure, p. 67). The right middle cerebral artery, shortly after entering the Sylvian, fissure was greatly and irregularly dilated, more especially as to its anterior branch, and fed the large mass of vessels, one of which was almost as large as an ordinary brachial. Towards the anterior and inner portion there entered one of the anastomosing branches of the anterior cerebral, dilated to a size larger than that of an ordinary radial. A small quantity of effused blood was found at the base of the brain, but this did not extend to the convexity. The anterior cerebral just after its origin divided into three branches, each of which

was as large as the whole artery is normally, and it was at this spot where the hæmorrhage seems to have taken place. A vertical transverse section of the hemisphere passing through

FIG. 19.

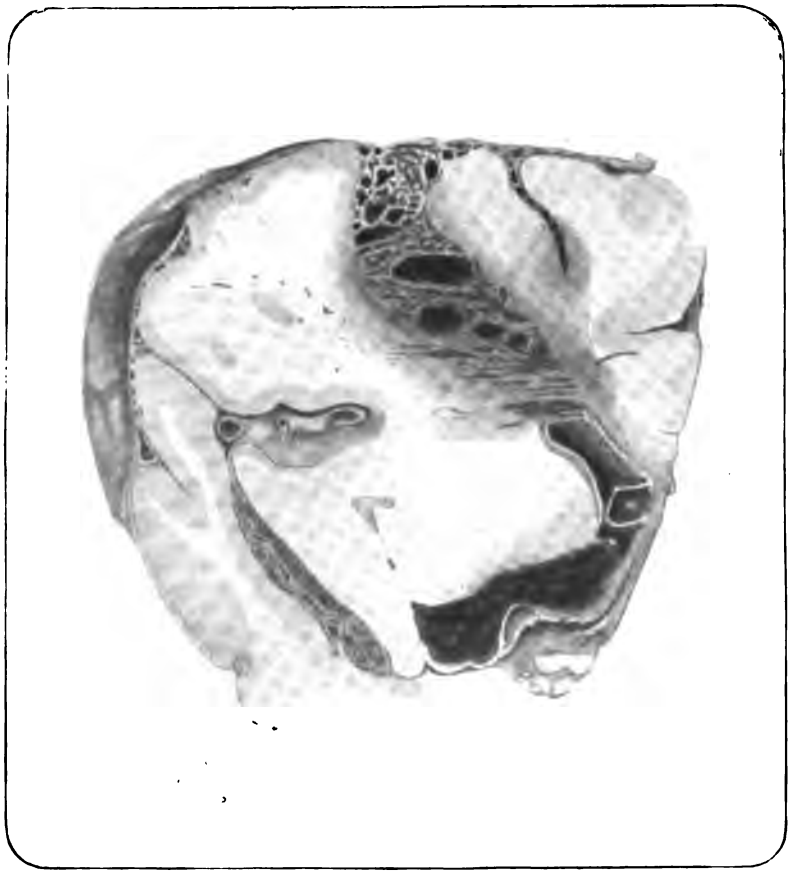

A transverse vertical section of the cerebral hemisphere, passing through the lateral ventricle, and showing the compact plexus of tortuous arteries in the substance of the brain. Case 2.

the anterior part of the lateral ventricle shows a roughly wedge-shaped mass of vessels extending down into the substance of the white matter, and looking on section almost like a cavernous angeioma (Figure 19). A large vessel in the choroid plexus can

be seen cut across, and effused blood can be seen infiltrating the brain tissue between the situation it occupies and the spot where the anterior cerebral has apparently given way. The cavity of the lateral ventricle does not contain any free blood, so that although it is not quite clear where the rupture had taken place, it cannot, I think, have been in the lateral ventricle itself, but rather from the spot already indicated, the blood having tracked inwards into the substance of the brain. The vessels of the other areas of distribution of the cerebral circulation are slightly, but only slightly enlarged. The arteries of the circle of Willis appeared natural.

Some early chronic interstitial nephritis with corresponding hypertrophy of the left ventricle was found. No obvious change elsewhere in the body.

Microscopical examination.—The main mass of either "tumour" is seen to consist of spaces varying greatly in size, and filled with blood. In all the parts examined the blood has remained fluid, no thrombosis or obliteration being discovered. In the more superficial parts these spaces are closely set with only a very small amount of connective tissues intervening. In the deeper portions, towards the lower edge of the mass, the spaces are seen as isolated blood-containing vessels, with a greater or less amount of intervening brain-substance.

The walls of the blood-spaces, whether in the mass or isolated, vary considerably in thickness, even when they have the same diameter. In the main isolated vessels this can be recognised naked eye, in the irregular dilatation and thickenings which occur in their course. The spaces or vessels are lined by endothelium of normal appearance, but the other components of the vessel wall are greatly altered. In some parts all the coats seem to be relatively thinner than natural, though it must be remembered that the cerebral arteries normally have thinner walls than arteries of equal size in other parts of the body. In addition to the diminution in thickness the middle coat contains a considerably smaller number of muscle-fibres and a corresponding increased amount of connective tissue. The elastic fibres, too have in great part disappeared. Indeed, in places the whole thickness of the wall is composed of a very sparsely cellular connective tissue. In other parts the middle coat appears to have undergone proliferation, which, in its turn, has

undergone hyaline degeneration. No fatty or calcareous changes were seen in any of the sections. In a section of one of the enlarged arteries, at some distance from the main mass, the subendothelial tissue has undergone proliferation, causing irregular thickening internal to the elastic lamina, which is in this case well preserved. Here, too, the middle coat and adventitia are little altered. These changes correspond fairly with those found by various observers in cricoid aneurysm in other parts of the body. The changes described differ greatly from one another. In turn one or other or more than one of the coats has shown the main changes, and these have been sometimes hyperplastic, sometimes degenerative.

As to the arterial nature of these tumours there can be no doubt. An examination of a section taken from the main mass, it is true, shows for the most part a structure very unlike that of an ordinary arterial wall, but by dissection of the mass itself it can be shown to consist of a bunch of vessels, exceedingly tortuous, with irregular dilatations, and held together by a small quantity of connective tissue. Isolated vessels, undoubtedly arteries, can be traced directly into the mass, and these arteries on examination show changes similar in character but less in degree. I have not been able to find any record in this country of cases described under this head, and only four others altogether. I think, however, that two specimens have been shown at this Society: one by Mr. Henry Morris, in 1871, which corresponded very closely with one of the specimens I show, which was described as "a congeries of tortuous veins;" and a second by Mr. D'Arcy Power, shown in 1888, and described as "a swelling situated on a vein." This latter specimen, I think, is of interest, as showing what I take to be an early stage of the condition. It was taken from a youth of twenty who died in St. Bartholomew's Hospital from an intra-cerebral hæmorrhage resulting from rupture of some vessel in the tumour. The mass is clearly a closely intertwining bunch of vessels having its origin in the pia mater. It pressed inwards into the substance of the brain without becoming embedded in it. Two other cases, one published by Beadles, described as an "enlargement of veins," and the other by Shoyer, described as a cavernous tumour, are too clearly of this nature. In Germany, Kalischer, Steinheil, Deetz, and Emanuel have recorded cases, and from

America cases by Bremer and Carson, and Starr and McCosh, both operated on for cerebral tumour, may perhaps be included.

The causation of these "tumours" so called is very obscure.

Mr. Henry Morris suggested a congenital origin in his case, and that view has been taken by others.

For certain cases it is no doubt true, for in Kalischer's case, which died at the age of eighteen months, the condition was associated with a congenital telangiectasis of the face, and an opinion was hazarded during life that a similar condition of the cerebral vessels might explain the symptoms observed. For the majority of cases, however, this seems inadequate. The one striking symptom present in all but one, and that the "early" case shown by Mr. D'Arcy Power, was the presence of epileptiform fits, in most cases indistinguishable from "idiopathic" epilepsy, the symptoms of tumour being absent. If we exclude four cases in which for various reasons no history at all was obtained, and further exclude Kalischer's case, we are left with seven cases, and in four of these the fit came on after very severe injury to the head, and in another a scar was found in the scalp when an operation was about to be performed immediately over the seat of the tumour. Of course injury alone is not a sufficient explanation, but I think these cases afford good evidence that injury may be at least the exciting cause, as it has appeared to be in cirsoid aneurysm in other situations. *January 5th*, 1904.

---

10. *A new pathogenic anaërobe*—Bacillus carnis.

By E. Klein, F.R.S.

This microbe was isolated from beef infusion which had been allowed to undergo putrefaction. The microbe is an obligatory anaërobe, and possesses the following characters:

1. *Morphological.*—Slender motile bacilli, average length 1·5—2·5 μ, about 0 6 μ broad, with rounded ends. The motility is due to flagella distributed over the whole of the bacillary body. It stains readily with the ordinary aniline dyes, and is gram-

positive. The microbe forms nearly oval spores, which are always terminal, and when fully formed are rod-shaped, of the length of 2μ; their breadth about $0{\cdot}8\mu$. The spores stain after the usual methods of spore-staining.

2. *Cultural.*—The microbe forms on agar and on serum flat, very translucent, disc-shaped colonies; they are slow in their growth, at first rounded in outline with a slightly raised margin; they gradually develop short knob-like projections from the surface as well as from the margin. Growing on the surface of gelatine the colonies have the character of flat translucent expansions, gradually developing irregular short-branched processes, and resemble then a lichen. In the depth of the gelatine the colonies after some days send out numerous branched threads with knobbed ends. In the gelatine stab from the line of growth moss-like bundles of fine threads extend laterally. The gelatine is not liquefied after several months. Blood-serum is not liquefied, and in glucosed media more or less abundant gas is produced by the growth. The cultures possess no odour. The microbe grows well in milk, but does not cause any alteration in the fluid character of the milk after some weeks. Spores are readily formed at 37° C. in stab agar, and in the condensation water of sloped agar and sloped serum, and in such cultures the microbe can, therefore, preserve its vitality for any length of time.

3. *Experimental.*—Small doses of culture (bacilli or their spores) injected subcutaneously into guinea-pigs and mice cause a rapidly spreading gelatinous infiltration, and death in twenty to thirty-six hours. On *post-mortem* examination the subcutaneous tissue is found infiltrated over extensive areas with sero-sanguineous, odourless, apparently clear fluid, but examined under the microscope it contains abundance of short, slender, motile bacilli; a few hours already after death some bacilli contain the terminal spores. If the fluid is taken up in glass capillary pipettes, which are then sealed at both ends and incubated at 37° C., copious formation of spores takes place in a few days, and permanent material for further work can thereby be preserved. The fully formed spores remain unaffected in their vitality by a temperature of 80° C. for ten to fifteen minutes. A few drops of the fresh subcutaneous fluid suffice to cause rapidly (in twenty to twenty-four hours) a fatal result in another guinea-pig or mouse.

In most instances the peritoneum, stomach, and intestines are inflamed, and show hæmorrhages. The spleen is generally not enlarged, but occasionally shows infarcts; the same is the case with the liver. The blood, as also the spleen, contains the bacilli, but not as abundant as the subcutaneous exudation.

There is no gas present in the subcutaneous tissue or in the internal organs. By the high degree of virulence of its culture, by its morphological and cultural characters, and by the nature of its action on the rodent, the microbe is without doubt different from the pathogenic anaërobes hitherto described, and I propose for it the name of *B. carnis* on account of its derivation. It differs in every respect from the non-pathogenic *B. carnicola* described by Sanfelice ('Zeitschrift für Hygiene und Infections-Krankheiten,' Band xiv, p. 268), and isolated by him (as Anaërobe I) from putrid meat infusion.

January 19th, 1904.

---

11. *An examination of certain of the specimens of enlarged prostate removed by Mr. P. J. Freyer.*

By S. G. Shattock.

De quibusdam exemplis prostatæ perauctæ a P. J. Freyer ablatis, et museo Collegii Regalis Chirurgorum Anglici datis.

Summarium.

Opus chirurgicum quo Freyer utitur constat (breviter dictu) ex cystotomiâ suprapubicâ, post quam mucosa vesicalis eis partibus prostatæ superposita quæ intra vesicam projiciuntur, digito laceratur, et glandula tota enucleata, per læsionem suprapubicam aufertur. (De ablatione tumorum a glandulâ nihil nostrâ interest.) De hac operatione duæ quæstiones propositæ sunt—

(1) Conservatur-ne urethræ pars prostatica?

(2) Aufertur-ne glandula tota?

(1) Quum in memoriam revocemus quam extensa et quam attenuata fit mucosa urethralis in prostatâ augescendâ, apparebit etiam quantum in proposito urethræ conservandæ continetur.

In quibusdam harum operationum glandula prostatica ablata est orbe intacto; in aliis, dilacerata a fronte ut urethræ paries separetur atque conservetur.

Modi primo citati, hoc exemplum proponam (P. J. Freyer, 'British Medical Journal,' February, 1902, Case 8). Hic, postquam prostata enucleata et in vesicam dislocata erat, urethræ paries tactu inventa est catheterem circumdare, ultra glandulæ extremitatem anteriorem.

Hanc urethræ partem, chirurgus opinatus est, esse prostaticam ex quâ destricta erat glandula, sicut globulus e filo. Scrutatio, verumtamen, probat urethræ partem a chirurgo tactam, haud prostaticam esse sed partem membranosam quæ super catheterem protracta et unâ cum glandulâ ablata erat.

In illis casibus in quibus glandula prostatica a fronte dilacerata est antequam in vesicam dislocata, scrutatio demonstrat mucosæ attenuatæ tractus latos ad glandulam intus adhærere, quanquam chirurgus urethram conservare conatus erat.

Hæc observationes demonstrant partem urethræ prostaticam in prostatâ auferendâ non conservari.

(2) Aufertur-ne glandula tota, i. e. unâ cum capsulâ suâ?

Capsulam intelligere oportet esse corticem fibromuscularem glandulæ sine fasciâ rectovesicali ac sine musculo levatore ani. Quæritur utrum glandula prostatica enucleetur e capsulâ, an unâ cum ea auferatur.

Ad hoc judicandum proponam optimum e pluribus exemplis a Freyer museo Collegii datis (P. J. Freyer, 'British Medical Journal,' Aprili 18, 1903, Case 28).

In exemplo proposito chirurgus urethram conservare non conatus erat, et glandula ablata est orbe intacto. Glandulæ hujus sectionem feci transverse ad axem urethræ longiorem.

Scrutatio superficiei perscissæ monstrat texturam glandulæ circumtegi cortice adhærente, circiter 1 mm. crassitudine, quam corticem sectio microscopica ex telâ musculari (levicellulari) constare probat.

A latere profundiori hujus corticis, sive capsulæ, oriuntur fasciculi musculares qui stroma glandulæ formant.

Præter capsulam muscularem, nihil aut fasciæ recto-vesicalis adest aut musculi levatoris ani.

In illis exemplis ubi "capsula" dilacerata est, in glandulâ auferendâ, superficies sic detecta, teres atque tuberosa apparet.

His observationibus monstratur opus a Freyer usum non modo ex enucleatione tumorum constare, sed vere prostatectomiam esse.

Num est hæc prostatectomia tam histologice perfecta quam apparet chirurgice ?

Scrutatio microscopica hic illic ostendit lacunas glandulares epithelio intus contectas in partibus extremis corticis fibromuscularis jacere, atque in lineâ ablationis tam dilacerari ut non dubitari possit quin prostatæ prægrandis lamina attenuata superesset ac in corpore ægri maneret. Histologice, quidem, prostatectomia haud est tota, quamvis chirurgice ita esse videatur.

DURING the spring of the year (1903) Mr. Freyer was good enough to place at my disposal for the museum of the Royal College of Surgeons the whole of the extensive series of the enlarged prostates which he had up to that date removed by operation.

Of these, eleven were selected by myself as illustrating the more important features shown by the specimens in question (which have been described in the seventeenth appendix of the College catalogue), and the opportunity has thus presented itself of critically examining material over which considerable controversy has arisen, and in regard to which widely different opinions have been expressed. It does not fall within my province to discuss what place the operation practised by Mr. Freyer holds in the evolution of prostatectomy. The operations in surgery offer problems which are, in a certain sense, parallel with those of morphology, where form proceeds from form by such gradations as to render it difficult to determine where a strictly new departure arises. Any further discussion of this topic I leave to others.

It is with certain of the anatomical aspects of this subject alone that the following communication deals.

The two questions upon which controversy has arisen concern—(1) the preservation of the prostatic portion of the urethra; (2) the totality of the prostatectomy.

(1) Is the prostatic urethra saved in prostatectomy?

This question has lost much of the interest it once had, since Mr. Freyer at the present time regards the preservation of the urethra as a matter of indifference. We may, however, consider firstly the case where the gland is removed with its circumference entire; and secondly, that in which the gland is parted through the front with the definite purpose of isolating and saving the urethral canal.

Let me take, as an example of the first, the eighth case recorded by Mr. Freyer in the 'British Medical Journal,' February 1st, 1902, a case in which the prostate is wholly removed, with its circumference entire, and in which the urethra was considered by the operator to have been isolated and left behind.

I may first cite the author's account in full, and then describe the specimen itself.

The patient was a man aged 65, who had suffered for ten

years from prostatic symptoms, which had become aggravated during the last two years and a half.

In November, 1901, the frequency reached seven or eight times by day and ten or twelve by night. The residual urine, which was acid, but contained albumen, amounted to six ounces, and bleeding followed the introduction of the catheter. Cystoscopic examination revealed an irregular bulging around the internal urethral aperture, with a projecting middle lobe.

On December 11th, 1901, the bladder was opened suprapubically, and enucleation of the prostate carried out; the gland was completely detached all round, and lay loose in its sheath, with the catheter passing through its axis. "Passing my finger along the upper surface, I endeavoured to separate the lobes along the superior commissure in order to strip the prostate off the urethra, counter-pressure being made by the finger in the rectum, when the whole mass was suddenly propelled into the bladder, so that no trace of prostate could be felt *per rectum*. I then noticed that the catheter was covered by the urethra for about two inches from the triangular ligament."

Hæmorrhage was controlled by hot irrigation. The cavity in which the prostate lay rapidly contracted. The catheter was withdrawn, and no attempt was made to unite the urethra to the neck of the bladder by suture. A supra-pubic drainage-tube was inserted. Recovery was complete. The patient began to pass urine naturally on December 23rd, and the supra-pubic wound was completely closed on January 5th, 1902.

The specimen, after preparation, I have thus described in the College catalogue:

4355 D. An enlarged prostate measuring nearly two and a half inches in extreme transverse diameter, which was removed by operation.

The enlargement of the lateral lobes is symmetrical, and with them there has been removed an enlarged third lobe, grooved in the middle line so as to form a semicircular elevation around the internal urethral aperture. The median portion of this elevation is covered with a flap of mucous membrane, beneath which a piece of white glass has been passed, and black bristles have been run

beneath the thinned mucosa, covering the lateral parts of the same lobe.

The organ is covered with a "capsule," beneath a partially detached lamina of which a piece of blue glass has been placed. At the lowest part of the left lobe the investment has been torn through; the glandular substance so exposed has a smooth, lobulated exterior, showing that the enlargement has followed the usual adenomatous type. Beyond the anterior termination of the gland is a cord-like process, which microscopic examination shows to comprise mucous membrane, invested on one aspect with columnar epithelium. This is continued without interruption into the bore of the gland, and it must be regarded, therefore, as portion of the urethral mucosa on the distal side of the prostate.

Here there appears at first sight an irreconcilable discrepancy between the impression of Mr. Freyer, viz. that the prostatic urethra was saved, and the evidence furnished by the specimen, which proves that it was not. And yet there is a possible explanation, which I venture to submit.

After the isolation of the prostate from its peripheral and vesical connections (the continuity of the prostatic urethra with the membranous still remaining intact), when the operator's finger was passed along the upper surface of the gland, and when the whole mass was suddenly propelled into the bladder, the mucosa of the membranous portion was dragged from its normal position and drawn over that portion of the catheter which had previously lain within the prostate, and this, being felt by the finger whilst the latter was in front of or on the distal side of the gland, was taken by the operator to be the proper prostatic urethra, from over which the glandular mass had been withdrawn, like (as the author graphically says) a bead from off a thread.

The anomalous cord-like appendage connected with the anterior end of the prostate did not escape Mr. Freyer's notice, and to account for its presence he supposed it to represent the pubo-prostatic ligaments.

In another set of cases, however, the capsule has been torn through anteriorly in the middle line, and the anterior commissure between the glandular substance of the lateral lobes parted

up, with the definite object of reaching the urethra within and peeling it off from the interior of the hypertrophied gland, so as to leave it intact and in continuity with the membranous portion. At its vesical end the continuity is, of course, broken, since the mucosa over the intra-vesical eminence of the gland is torn through with the finger as a preliminary procedure to the enucleation. As an illustration I may cite Case 9, reported by Mr. Freyer in the 'British Medical Journal,' July 26th, 1902, in which this attempt had been made, and in which it was thought to have been successfully carried out.

The gland was enucleated on January 15th, 1902, the vesical mucosa over the left lobe being scraped through with the nail of the forefinger, and the lobe then separated from the sheath, below, outside, and above, and lastly, internally from the urethra, which, with the contained catheter, was pushed upwards, the two lateral lobes separating through the anterior commissure. The right lobe was isolated in the same way through the same aperture in the mucous membrane. The whole prostate was finally stripped off the triangular ligament and pushed into the bladder (by the finger in the rectum), whence it was delivered by forceps through the supra-pubic wound.

There was little bleeding, and this was controlled by irrigation with hot boric lotion. The cavity previously occupied by the prostate rapidly contracted, so that after irrigation it could scarcely be made out. A large drainage-tube was inserted into the bladder, and the abdominal wound closed round this by means of silkworm sutures; this tube was removed in forty-eight hours, and the bladder irrigated daily through a large *coudée* catheter.

Recovery was uneventful and complete. The specimen I have thus described in the College catalogue:

4355 F. An enlarged prostate, of which the vesical portion forms a collar around the internal aperture of the urethra.

During its removal the lateral lobes have been separated in front of the canal, the remains of the prostatic portion of the urethra being exposed in the specimen. Except at the lower part, the urethral and vesical mucosa remain on the enlarged gland, the depth of the canal being, as is regularly the case, largely increased.

Black bristles have been inserted in spots beneath the torn edges of the membrane named.

To illustrate this from another case, I may detail the examination of a specimen removed by Mr. A. Pearce Gould, and lately presented by him to the College museum, and to which he kindly allows me to refer. It was from a gentleman sixty-four years of age, unmarried, who in 1893 experienced some difficulty in micturition, which was treated by catheterisation and intra-vesical injections. A severe attack of cystitis ensued. This subsided, but led to an entire dependence upon the catheter.

In May, 1903, he consulted the donor because he had on several occasions passed blood with his urine after exertion, the last time in great quantity. There was no accompanying pain. Urine: sp. gr. 1022, acid, clear, free from albumen and sugar.

On May 21st, 1903, supra-pubic cystotomy was performed, and seven small facetted calculi of uric acid were removed from a very deep post-prostatic pouch. The hypertrophied gland was then enucleated with the forefinger; in the recent state it weighed 7¼ ounces.

The patient made an excellent recovery. The tube was removed on the third day; urine was passed naturally on June 6th, and the patient left town on June 26th, the operation wound being at that date soundly healed.

In October, 1903, he was quite well, and was able to pass urine without difficulty or pain; to hold it all night, and for from four to eight hours in the day.

Here the same definite attempt was made, and by the same plan, to keep the urethra, but with what result the following description will show:

4355 o. A much enlarged prostate, measuring three and a half inches in its longer antero-posterior diameter, which was removed by operation. The left lobe is considerably more enlarged than the right. There is no differentiated median eminence or third lobe, the enlargement forming a semi-circular but asymmetrical projection within the neck of the bladder. In the removal of the gland the muscular "capsule" has been torn through anteriorly, and the

anterior commissure parted up with the aim of isolating and preserving the urethra.

A dissection has been carried out to show how far this has been effected. At the highest part of the specimen on either lobe an extensive flap of the vesical mucosa is displayed, that on the right lobe having been raised upon a rod of white glass, that on the left having been transfixed.

From these flaps the mucosa is prolonged through the bore of the gland almost as far as its lowest limit. In consequence of the increased growth of the glandular tissue the potential capacity of the canal has been widely increased, the urethral mucosa being as a result so thinned as to be hardly traceable.

On the right lobe, proceeding from above downwards, a black bristle has been inserted beneath the edge of the urethral mucosa, which is here so extremely thin that it hardly admits of being raised by the most delicate dissection, but its proper character is shown not only by its direct continuity with the flap of thicker mucosa on the vesical aspect of the lobe, but also by microscopic examination, which reveals a complete mosaic of prominent epithelium over its inner surface. The torn edge of the lowest limit of the thinned urethral mucosa is demonstrated upon two pieces of white glass rod; and microscopic examination of portion of this shows it to be completely lined with a proper urethral epithelium.

Proceeding to the opposite, the left lobe, the smooth thin urethral membrane, which is traceable from the rugose area at the neck of the bladder, has been obliquely torn in the operation; the edge of the membrane beyond the tear is displayed upon two black bristles, and this area will be found continued superiorly into a wrinkled triangular flap, beneath which a rod of white glass has been inserted.

The examination of this specimen, therefore, shows that the chief part of the urethral mucosa remains. The preservation of the urethra was unsuccessful for the simple reason that it was impossible; for over the chief and larger areas of the prostatic lobes the membrane is so attenuated that it can hardly be raised and demonstrated by dissection. How much less, then, could it be detached in its entirety by means of the finger used without any guidance of the eye, through a supra-pubic aperture in the

bladder! In fact, the object aimed at in such circumstances is so incompletely attained that it cannot, properly speaking, be said to have been carried out; such extensive tracts of thinned urethral mucosa does examination disclose adhering to the deepened bore of the gland. Nor is it easy to see what would

FIG. 20.

An enlarged prostate removed by Mr. A. P. Gould in a case where the attempt was made to save the urethra. The thinned urethral mucosa is shown in various positions by means of white glass rod and bristles.

EXPLICATIO FIGURÆ.

Prostata peraucta a A. P. Gould ablata, urethræ conservandæ conatu facto. Diversis in locis mucosa attenuata setis subditis monstratur. (Magnitudinis naturalis.)

be gained by preserving intact so flimsy and capacious a tube, supposing it were possible; for the gland supporting it having been removed, this isolated portion of urethral membrane would necessarily be forced into folds between the triangular ligament and the bladder on the latter dropping forwards, and by its sheer redundance would be in the way rather than of any use.

But to pass on to the second question. Is the whole of the gland removed?

For the investigation of this matter I selected the most cleanly extirpated of the whole of Mr. Freyer's specimens (Case 28 'British Medical Journal,' April 18th, 1903).

The gland was taken from a gentleman aged 63, who had suffered from prostatic symptoms for seven years. Rectal examination proved the prostate to be much enlarged, bilobed, tense, moveable. No calculus was detected on sounding. The patient had been in the habit of passing a catheter from two to four times daily for five years; considerable bleeding took place.

The gland was enucleated on December 8th, 1902. Some urine passed naturally on December 20th, and the whole on December 24th, after which the supra-pubic wound did not reopen.

On January 8th, 1903, he left town, able to pass and retain his urine naturally.

Of this specimen, after hardening, I made a complete transverse section in a plane at right angles to the axis of the urethra, and midway between its upper (vesical) and lower ends. To prevent confusion it is necessary to understand terms in the same sense as Mr. Freyer.[1] By the "sheath" is to be understood the fibrous investment furnished by the recto-vesical fascia; by the "capsule" the fibro-muscular envelope which is directly continuous with the stroma of the gland, but into which the gland tissue does not itself penetrate, and which may be designated the cortex.

The macroscopic description of the preparation in the College catalogue runs as follows:

4355 E. An enlarged prostate removed by operation and afterwards divided through its middle at right angles to the

[1] A clinical lecture delivered at the Medical Graduates' College, London, June 26th, 1901; 'British Medical Journal,' July 20th, 1901.

axis of the urethra, the vesical half being mounted above the other, and each half with the posterior or rectal surface lowermost.

There is no distinct eminence due to the enlargement of a middle lobe, the gland forming a collar-like projection round the vesical aperture of the urethra.

As in the three preceding specimens (Nos. 4355 B, C, D) the organ removed is covered with a transversely fasciculated "capsule." The torn edge of the mucous membrane around the vesical aperture of the urethra is very distinct, and it is prolonged over the apposed surfaces of the enlarged lateral lobes almost as far as the anterior surface of the gland.

At the anterior end the adenomatous character of the enlargement appears in the smoothly rounded, tuberose, or lobulated surface which it presents. The section shows that the increase is due to an overgrowth of gland tissue, which is for the most part arranged in numerous mutually adapted lobules, and encircling which, as a whole, is a continuous cortex or capsule about one millimetre in thickness, and consisting, as told by microscopic examination, of unstriped muscular tissue.

It is at once obvious that what has been carried out in this case is not the mere enucleation of an adenomatous formation. The surface of a prostatic adenoma, like that of other glandular tumours, is smooth, and lowly lobulated or tuberous, and altogether unlike the uniform and transversely fasciculated exterior presented by this specimen. The same holds true of most of the others of Mr. Freyer's donation. The mass is invested with a cortex of fibro-muscular tissue, through the artificial rents and deficiencies in which the underlying smooth and tuberose surface of the enlargement presents itself to view, showing that the condition comes within the common adenomatous category. Mr. Freyer's operation, therefore, is a prostatectomy. But is it as complete a prostatectomy histologically as it is from a surgical standpoint?

Does the line of enucleation absolutely and everywhere pass beyond the limits of the gland tissue? Although this is a theoretical possibility, a critical study of the muscular cortex shows that it is not the case in the specimen under consideration. The debate which has arisen round this question resolves itself

An enlarged prostate removed by Mr. P. J. Freyer (Case 28, 'British Medical Journal,' April 18th, 1903). Nat. size. The circumference is entire and devoid of lobulation, the surface being constituted by a transversely fasciculated "capsule." The torn edge of the vesical mucosa is evident around the end of the catheter. The figure of this specimen in the 'British Medical Journal' (loc. cit.) conveys an erroneous impression in regard to its size, the drawing having been made apparently from the organ as magnified by the vessel in which it was contained.

FIG. 21.

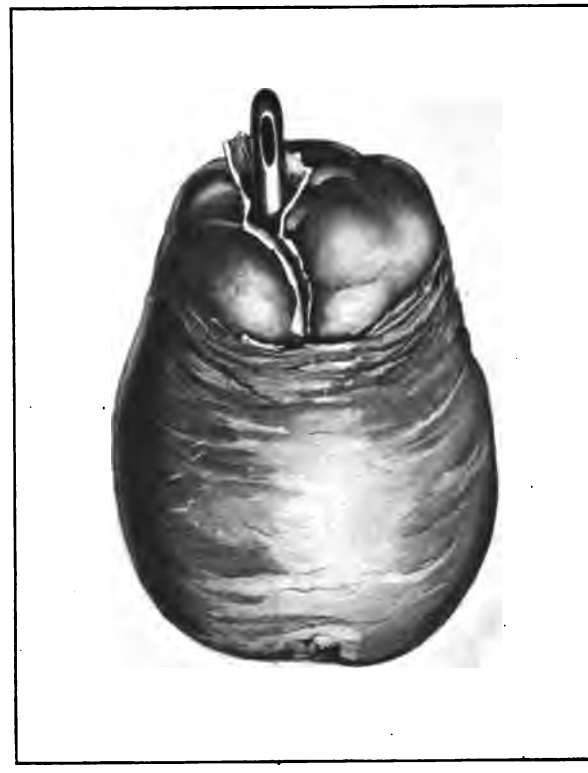

EXPLICATIO FIGURÆ.

Prostata peraucta a P. J. Freyer ablata (magnitudinis naturalis). Nisi apud utramque extremitatem, quo natura adenomatosa tumoris apparet, glandula "capsulâ" sive cortice circumtegitur. Margo lacerata mucosæ vesicalis catheterem circumdat.

into the histological finding with regard to the "capsule." That the "capsule" completely encircles the organ is clear not only on the transversely divided preparation, but equally so from a study of microscopic sections comprising the entire area concerned.

From the deeper side of the fibro-muscular "capsule" there proceeds the fibro-muscular stroma of the gland; on the super-

FIG. 22.

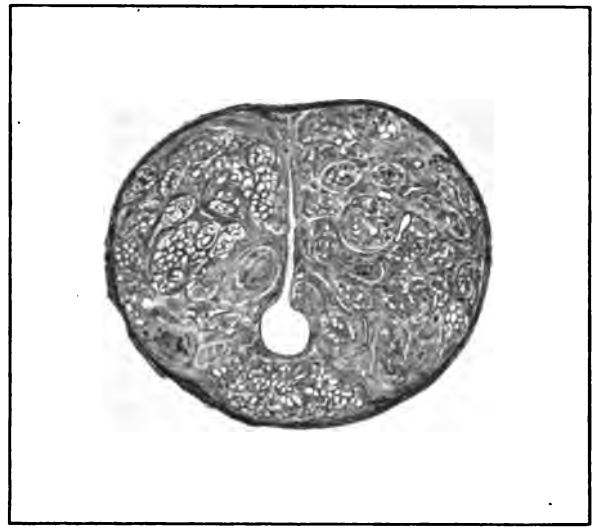

A transverse microscopic section (natural size) of the foregoing specimen, showing a cortex of fibro-muscular tissue completely surrounding the glandular mass, but in which microscopic examination reveals the presence of a few flattened gland recesses, some of which are torn across in the line of enucleation, the prostatectomy being histologically incomplete. The lower part of the urethra has been filled with a catheter during the process of hardening.

EXPLICATIO FIGURÆ.

Sectio microscopica per prostatam præcedentem scissa transverse ad axem urethræ longiorem (magnitudinis naturalis). Monstratur cortex fibromuscularis molem glandularem circumdans in quâ cortice autem scrutatio microscopica paucas lacunas glandulares ostendit; harum aliquæ in lineâ ablationis dilaceratæ sunt. Prostatectomia, itaque, histologice imperfecta est.

ficial or external aspect there is nowhere any trace of a fibrous envelope, and none of muscular tissue of the striated

kind, proving that neither the sheath derived from the recto-vesical fascia nor the levator ani has been reached in the operation.

To enter into a more minute description of sections cut from one of the sides of the mass: concerning the proper glandular tissue it is enough to observe that this is of the acinous or tubulo-acinous type, and that its recesses are lined with columnar epithelium. The spaces, however, are for the most part abnormally dilated, or microcystic, and in such the lining is less prominent,—cubical or flattened. At the surface of the section there is a well-defined zone of uniform thickness, constituted by concentric bundles of unstriped muscle-cells held together by a considerably smaller amount of common connective tissue. Although the bundles of muscle-cells run chiefly in a direction transversely to the long or urethral axis of the gland, there intervene in places narrower and less considerable zones in which the muscle-cells are divided transversely. The muscle-cells admit of ready identification in consequence of their deep red coloration (hæmatoxylin and eosin), the fibre of the associated connective tissue being but faintly tinted. Some of the long wavy muscle-cells, with finely tapering ends and rod-shaped nuclei, are traceable for their entire length, and parallel with such are various lengths of the other cells composing the bundle,—often only the attenuated extremities: some of the cells present irregular swellings in their course—an indication, probably, that they have been fixed whilst in a contracting state.

Although the faintly stained substance between the muscular elements of the bundle appears quite homogeneous, its true fibrous character is evident from the fact that the clefts between the bundles present a regularly wavy border beyond the contractile cells. Elsewhere in the clefts lesser subdivided fibres of the common connective kind are obvious.

It is at the surface of the "capsule" that the admixture of fibrous tissue is most pronounced, its fibre coarsest and the most homogeneous; but muscle-cells are regularly mingled with it to the very surface, the investment being nowhere fibrous but fibro-muscular in the strict terminology. In the deeper part of the capsule the supporting connective tissue is finely fibrillated and of a looser texture, and as such it is prolonged with the mus-

cular tissue into the substance of the gland. For it is to be observed that the capsule on its deep aspect is in no way demarcated off from the fibro-muscular stroma of the gland, the transition of the one into the other being effected solely by the alteration in the trend of the muscle-cells, the bundles of which diverge in curvilinear directions and penetrate between the proper glandular structures.

The use of Unna's acid orceïn reveals a network of exceedingly fine elastic fibrils in the interacinous fibro-muscular tissue. The mesh of the network (which can only be appreciated by $\frac{1}{12}$ immersion) varies in closeness, and does not uniformly penetrate the stroma: in cross-section the elastic element appears as minute points, proving that it is fibrillar and not lamelliform. In the fibro-muscular "capsule" the elastic fibrils run in correspondence with the white bundles and muscle-cells.

For long distances the cortex consists solely of unstriped muscle-fibre, for the most part concentrically disposed, and it seemed at first as though the whole of the prostate had been removed; yet this is not strictly the case.

In the fibro-muscular investment there lie here and there the flattened recesses of gland-tissue; and here and there these are torn across in the very line of ablation. Not only is the glandular epithelium recognisable in the spaces so torn, but in one such there lies a deep brown concretion which places its character beyond doubt. It is clear, therefore, that a layer (thin it may be) of the proper prostatic tissue has been left behind.

In short, the prostatectomy is histologically incomplete, however complete it appears from a surgical standpoint; for the plane of removal does not absolutely and everywhere lie beyond the limits of the glandular tissue. *October 20th*, 1903.

---

11. *On the preparation of nutrose-agar.*

By J. W. H. Eyre, F.R.S.Edin.

Early in 1902 von Drigalski and H. Conradi (1), working in the Infectious Diseases Institute in Berlin, elaborated a novel

agar medium which they claimed afforded greater facilities than had hitherto been enjoyed in the isolation of members of the coli group, especially *Bacillus typhosus*, in that the growth was unchecked upon this medium, but that many intestinal bacteria, other than those of the coli group, and also aërial micro-organisms were more or less inhibited. The instructions for the preparation of their "Lakmus-Laktose-nutrose-agar," given in the original paper, are in the main fairly clear, and may be summarised thus:

Prepare agar mass as follows:

1. Mince 3 lbs. of beef and allow it to stand for twenty-four hours in 2 litres of water.
2. Express the fluid and juice and boil for one hour.
3. Filter, then add to the filtrate 20 grammes Pepton sicc. Witté; 10 grammes salt; 20 grammes nutrose; boil for one hour, and again filter.
4. Add 60 grammes finest bar agar and boil for three hours.
5. Make the agar mass faintly alkaline to litmus, filter, and boil for half an hour.

Make litmus-lactose solution as follows:

1. Take Kubel-Tiemann's litmus solution, 260 c.c., and boil for ten minutes.
2. Add 30 grammes chemically-pure lactose, and boil for fifteen minutes.

Mix the agar mass and the litmus-lactose solution whilst hot, and shake thoroughly; re-establish the alkalinity of the medium mass, then add 4 c.c. of a hot sterile 10 per cent. soda solution, and 20 c.c. of a freshly-prepared 0·01 per cent. watery solution of crystal violet (B. Höchst).

By following these instructions carefully I prepared several batches of the medium and employed it for a short time in routine work. As a medium its appearance was not elegant, whilst as a diagnostic agent—in my hands at least—it left much to be desired. From theoretical considerations, however, it possessed helpful possibilities, but as at the moment I had not the time to inquire into the reasons of my failures I had, reluctantly, to leave it.

Later on in the year Koch, engaged in investigating an epidemic of enteric fever at Trier, employed the medium for the isolation of the *B. typhosus* from the stools of patients, contacts

and apparently healthy individuals, and with the aid of his assistants achieved a marked success. The results obtained were recorded by Professor Koch in a lecture (6) delivered at the Kaiser Wilhelm Academy towards the end of November. Abstracts and reviews of this lecture attracted a certain amount of attention in this country on account of the view expressed by its author, that the strict supervision of water-supplies, etc., should be superseded by the isolation of the typhoid-infected individual (as determined by bacterioscopical examination of his fæces), rather than on account of the novelty of the medium employed, although by the use of this medium it was stated a positive diagnosis of enteric could be obtained within twenty to twenty-four hours. My attention was thus once more directed to the manufacture of this medium, but again with unsatisfactory results. I therefore proceeded to study the method of manufacture in the laboratory of the Infectious Diseases Institute, and here I wish to express my thanks to Professor Kolle, who carefully explained the composition of the medium to me, and afforded me every facility for its preparation.

I soon realised that the medium was not the automatic one its authors suggested. On the contrary it was a distinctly variable medium in composition, reaction, colour, and the macroscopical appearances of organisms growing upon it, and one with which the worker must be as absolutely familiar as is necessary in the case of all other media advocated for the isolation of the *B. typhosus*. Further, the appearances of the various common intestinal bacteria upon this medium must be made the subject of careful differential study before employing the nutrose-agar for the isolation of the *B. typhosus*. Still, it appeared probable that by adopting "standard" methods in its preparation, similar to those I have advocated (2) for many years past for the preparation of other nutrient media, a medium might be elaborated which would be a distinct addition to the armamentarium of the working bacteriologist, and, as a further and distinctly important point, the time employed in making a batch of the medium might be so restricted as to bring it within the compass of a single working day. Consequently, on my return to London, I applied myself to a detailed study of the medium to this end.

The method of preparation, explained to me by Professor

Kolle—a modification by Lentz—was that which I at first employed, and may be briefly described as follows:

Stage I.

1. Take 3 lbs. of lean beef finely minced, and add 2 litres of water.
2. Heat gently for two hours, and then filter off the "Fleisch-wasser."
3. Make up the filtrate to 2 litres, to replace water lost by evaporation.
4. Add sodium chloride 10 grms.
   Witte's peptone 20 „
   nutrose . 10 „
   } and heat for 1 hour in the steam chamber.
5. Filter through Swedish filter-paper.
6. Add 60 grammes of finely chopped "crude" or "bar" agar to the filtrate, and heat for three hours in the steam chamber.
7. Cool to below 60° C., add two eggs well beaten, heat in the steamer for thirty minutes, then filter through papier chardin in the steam chamber.
8. Neutralise by the addition of successive small quantities of normal soda solution, using litmus (in the form of litmus paper) as the indicator, and then render faintly alkaline.
9. Measure the fluid agar-mass. (Usually amounts to 600 c.c. to 1200 c.c.)

Stage II.

Measure out an amount of "Kahlbaum's" litmus solution, equivalent to 13 per cent. of the filtered agar-mass, into a small flask, add 1·3 per cent. of chemically pure lactose, and heat in the steamer for fifteen minutes.

Stage III.

Measure out 1 per cent. of a 1 per 1000 aqueous solution of crystal violet (B. Höchst) into a test-tube, and heat in the steamer for fifteen minutes or boil over the naked flame.

Stage IV.

Mix the hot, sterile, litmus-lactose solution with the hot fluid nutrose-agar and shake vigorously. If necessary re-adjust the reaction of the medium mass until faintly alkaline, as shown by the tint of the litmus. Add 3·5 c.c. of

a sterile normal soda solution per litre; mix thoroughly. Add the crystal-violet solution, and again mix thoroughly; fill into small flasks in quantities of about 100 c.c., and store for future use.

Further sterilisation, it is said, is unnecessary on account of the thorough cooking the medium has undergone during its preparation, and also on account of the germicidal action of the 1 per mille solution of crystal violet, which is present in the proportion of 1 per cent. This statement, needless to say, requires some qualification, and personally I prefer to sterilise in the steamer in the ordinary way, unless I intend using it immediately. Taking this method as my basis I proceeded to examine critically first the medium as a whole, and afterwards each of the ingredients that entered into its composition. (I may mention that I also gave the method detailed by Kamen (5) an exhaustive trial, but soon found, from the inexact methods introduced by this author, that further experiment in this direction could serve no useful purpose.)

I. *Reaction of medium.*

The vital point in the preparation of nutrose-agar, and that to which I first directed my attention, was the estimation of the reaction of the agar mass at the end of the first stage by the methods I have sugggested elsewhere (3). For this purpose I prepared several batches of media, following closely the directions given me, and obtained several other batches from the laboratory assistant in Berlin, and tested them all carefully. The result was, as I anticipated, a variation in reaction from + 4 or + 5 to + 15 (Eyre's scale)—that is, various batches of media required the addition of quantities of normal soda solution varying from about 5 c.c. to 15 c.c. per litre to render them dead neutral to phenolphthalein. The next step was to take a measured portion of the agar mass from each sample, add the 13 per cent. litmus solution and 1·3 per cent. lactose, and carefully readjust the faintly alkaline reaction—measuring exactly the quantity of soda solution necessary to effect this. A corresponding quantity of $\frac{n}{1}$ sodic hydrate, plus the further 0·35 per cent. directed to be added in the fourth stage, was then mixed

with other portions of each sample, the titration of the medium again carried out, and the *titre* of the medium estimated. Without going into detailed figures, I may state that the results were quite comparable to those obtained in the previous estimations of the range of reaction exhibited, the various samples being from about neutral to phenolphthalein (*i. e.* 0) to + 10 or + 11. Obviously, then, the first step in the preparation of a generally useful medium was to determine the exact reaction which gave the best all-round results, in order that every worker might prepare his medium in the same way, and all obtain similar results. In determining the most suitable reaction for a medium of this character several factors must be taken into account. In the first place the reaction must approximate fairly closely to the "optimum reaction" for the growth of the organism it is desired to isolate, so that growth may be accelerated, or, at any rate, not retarded. Secondly, the reaction must be such that the litmus solution is not markedly affected, either in the acid or alkaline direction—and in this connection it should be recollected that a marked acidity is easily obtainable by utilising such organic acids as have but little action upon litmus. Thirdly, the reaction should be as acid as is compatible with good bacterial growth, in order that the finished medium should be clear and translucent—unobscured by phosphatic and albuminous deposits. So far as the first heading was concerned, previous experiments had shown me that the optimum reaction of the coli group when grown upon ordinary nutrient agar lies between + 5 and + 8, but that a good and vigorous growth is obtainable between 0 and + 10.

A fairly wide range was available also under the second heading, previous experiments having shown that media prepared from meat, according to my methods, remains *neutral* to litmus so long as the reaction lies roughly between 0 and + 12. Clear and translucent media also can be obtained, associated with a similar range of reaction, thus fulfilling the third requirement.

In order to determine practically the best reaction for the medium under study I prepared several batches of nutrose-agar accurately standardised to 0, + 2·5, + 5, + 7·5, and + 10 respectively, the tint of the finished medium varying from

bluish purple in the first mentioned to a reddish purple in the medium of + 10 reaction. I then poured plates of each sample, and seeded them with several members of the coli group, viz. *B. typhosus, B. enterititis of Gärtner, B. dysenteriæ, B. coli,* and *B. lactis ærogenes,* and incubated at 37° C. for twenty-four hours. Of these organisms the *B. coli* and *B. lactis ærogenes* alone ferment lactose with the production of an acid reaction, the other bacilli giving rise to the formation of small quantities of alkali. After incubation the resulting growth on the various plates was carefully examined, and it was found that the largest colonies, showing the most vigorous growth and producing the most vivid colour, whether red or blue, were formed on the plates poured from the batch of medium, having a reaction of + 2·5. Further suspensions in sterile salt solution of the various bacilli (with the exception of the *B. dysenteriæ*) from this particular batch of medium showed more active motility than the bacilli in similar suspensions from colonies grown on media of any other reaction, while the *B. dysenteriæ* in like manner appeared to have more active Brownian movement. The next step was to seed plates poured from samples of media of various reactions, with mixtures of one or both of the acid producers in association with one or more of the alkali producing members of the coli group. After incubation it was again found that the plates showing the most clearly contrasted colour reactions of the associated bacteria were those containing medium of + 2·5 *titre.*

This all important question of most suitable reaction definitely settled, I now directed my attention to each of the ingredients of the medium in turn, examining critically and comparing the directions already given by various workers, and settling on what I considered the best proportions and the best method of incorporation.

II. *Meat extract.*

The watery extract of meat which formed the basis of the medium I prepared precisely as I should do for any other standard "meat" medium, that is, by the methods I have already fully described elsewhere (4).

III. *Solution of agar.*

One of the first modifications made in the medium was the substitution of the best powdered agar for the "crude" or "bar" agar recommended by Drigalski and Conradi. It had been particularly impressed upon me that powdered agar was unsuitable, as by its use it was impossible to obtain a sufficiently smooth and even surface on the "plates" to allow of successful insemination. The contention, however, that powdered agar gave rise to a rough surface was so opposite to my experience of it when used in the preparation of ordinary nutrient agar that I determined to give it a further trial in preparing nutrose-agar, with the result that it was found to be perfectly satisfactory. This being so, I was enabled to reduce the quantity of agar from thirty grammes per litre to twenty, for as I have shown previously (4), water will barely hold as much as 2 per cent. agar in solution; moreover, boiling water will dissolve out a larger proportion of agar from the powdered form, and that more readily than it can extract from the same quantity of the crude commercial form. In other words, there is so much extraneous matter present in the crude form of agar that it is necessary to subject even more than 3 per cent. of agar in this form to the solvent action of water in order to extract as much gelatinous material as can be obtained from two per cent. of the purified powdered agar.

Further, by dissolving the agar in water, kept at the boiling-point by bubbling live steam through it, the time necessary to effect complete solution is reduced from three hours or more to thirty minutes.

IV. *Solution of nutrose.*

The next point investigated was one which had given considerable trouble, and had reference to the difficulty of obtaining clear agar by filtration in Stage I. The trouble was due to the appearance of flocculent deposits in the medium, the result of the precipitation of nutrose. An attempt was therefore made to dissolve 2 per cent. nutrose in distilled water, by means of

heat, but it was at once found that the solution, opalescent, turbid, and flocculent whilst hot, deposited nutrose as a precipitate on cooling. I therefore prepared a series of flasks, each containing 100 c.c. of distilled water, to which lactic acid or sodic oxide was added to produce a graded series of *titres* from 0 to + 1·5 on the one hand, and from 0 to — 5 on the other; two grammes of nutrose was then added to each, and the entire series heated in the steamer at 100° C. for one hour. The solutions were allowed to cool, filtered, and then each solution in turn filled into a "tared" weighing bottle of a reputed capacity of 10 c.c., and weighed. The weight of the reputed 10 c.c. of nutrose solution was then compared with a similar quantity of distilled water, and the difference noted. The result of this series of experiments, all of which were conducted at a temperature of 16° C., is shown in the accompanying table. From this it will be seen that water, to which sufficient sodic oxide has been added to produce a titre of — 3·5, will dissolve practically 2 per cent. of nutrose, and will hold in solution about six times as much nutrose as neutral distilled water is capable of doing. When once solution has been effected, subsequent neutralisation and acidification of the fluid causes the precipitation of the excess of nutrose in the form of a firmer coagulum than is obtained by acidifying neutral solutions.

So that the next important modification I made in the preparation of this medium was to divide my Fleischwasser into three portions of about 600 c.c. each, dissolve the peptone and salt in one, and the agar in another, whilst the third was titrated, and its reaction adjusted to — 3·5, and the nutrose dissolved therein. Finally, the three portions are mixed thoroughly, the resulting mass titrated again, and its reaction adjusted to + 2·5 by the addition of standardised (normal) lactic acid,[1] and filtered. After carrying out these steps it was found that a clear, translucent filtrate, free from flocculi, could be constantly obtained.

[1] This "standard" (normal) lactic acid is a solution of lactic acid of such a strength that when titrated at the boiling-point, using phenolphthalein as the indicator, 1 c.c. is exactly neutralised by 1 c.c. normal sodium hydrate.

TABLE I.—*Solubility of Nutrose in Fluids of Varying Reactions.*

	Distilled water	Distilled water adjusted to a reaction of									
	0	− 0·5	− 1	− 1·5	− 2	− 2·5	− 3	− 3·5	− 4	− 4·5	− 5
Weight of weighing bottle + 10 c.c. nutrose solution	27·7200	27·7282	27·8008	27·8314	27·8350	27·8498	27·8560	27·8812	27·8674	27·8454	27·8102
Weight of weighing bottle	17·8936	17·8936	17·8936	17·8936	17·8936	17·8936	17·8936	17·8936	17·8936	17·8936	17·8936
Weight of 10 c.c. of nutrose solution	9·8264	9·8346	9·9072	9·9378	9·9424	9·9562	9·9624	9·9876	9·9738	9·9518	9·9166
Weight of 10 c.c. water at 16° C.	9·7870	9·7870	9·7870	9·7870	9·7870	9·7870	9·7870	9·7870	9·7870	9·7870	9·7870
Weight of nutrose in solution	0·0394	0·0476	0·1202	0·1508	0·1554	0·1692	0·1754	0·2006	0·1868	0·1648	0·1296

V. *Accidental presence of glucose.*

With these modifications of the original method of manufacture I was for a time satisfied, and the measure of success I attained in the isolation of the *B. typhosus* from clinical material convinced me of the value of the medium. Some work on the general bacteriological flora of the human intestine soon showed, however, that there was another fallacy to be eliminated from the method, a fallacy made still more apparent when I commenced to employ the medium for the isolation of the *B. dysenteriæ* from the fæces. I refer to the occasional presence of inosite or glucose in appreciable quantities in the watery extract of meat. Both *B. typhosus* and *B. dysenteriæ* ferment glucose when present, with the production of a slight amount of acidity, although they have no action upon the lactose which is added to the medium; consequently, if glucose is present in addition to the lactose, colonies of typhoid and dysentery growing on the medium show variations in the colour reactions which are extremely confusing and annoying. The authors, in their original directions, wittingly or otherwise, eliminated this factor to a certain extent by directing that the meat should stand in contact with water for twenty-four hours, but in point of fact, nothing short of inoculating the meat extract with the *B. coli* and incubating for a few days will completely split up and remove the sugar in question. This procedure presents many serious objections, and is, moreover, a tedious and troublesome business.

VI. *Use of ox serum.*

I therefore tried the substitution of ox or sheep serum for the watery extract of meat, and found it answer extremely well, for not only does fresh serum contain no sugar, but it does contain an enzyme (glycolytic), which will quickly destroy any added sugar. Blood is collected in the slaughter-house direct from the animal in a tall glass cylinder previously sterilised by dry heat, allowed to coagulate, and then placed in the ice chest. Some twelve hours later the serum, which has separated, is pipetted off, mixed with twice its bulk of distilled water, and heated in the steamer at 100° C. to destroy its contained ferment. This

solution of serum completely replaces the watery extract of meat as the basis of nutrose-agar.

In preparing the serum solution care must be taken to secure serum as free from admixed hæmoglobin as possible, otherwise the finished medium will present a greenish hue, which, although not seriously interfering with the colour changes in the litmus produced by micro-organisms, certainly detracts somewhat from the appearance of the medium.

VII. *Inhibitory action of crystal violet.*

With regard to the suggested inhibitory action of the aqueous crystal violet solution (1 per 1000), I must confess to being extremely sceptical. Its addition, to the extent of 1 per cent., to the medium appears to me to exercise no influence whatever in that direction, aërial micro-organisms and mould, as well as members of the mesentericus group of bacilli present in fæces, certainly grow luxuriantly on the finished medium. I do think, however, that some bacteria evince a selective affinity for the stain, and some varieties of colonies growing on the medium are distinctly tinted thereby.

It only remains for me to detail seriatim the steps in the manufacture of the nutrose-agar as I now prepare it, and which, if exactly followed, permit of the completion of a batch of medium well within the limit of an eight-hour day, and to add a few remarks on the technique of the plates poured therefrom.

VIII. *Preparation of nutrient agar.*

A.—1. Emulsify 20 grammes Pepton. sicc. Witté in 100 c.c. distilled water previously heated to 60° C.

2. Add 10 grammes sodium chloride.

3. Emulsify 40 grammes finest powered agar in 400 c.c. cold distilled water, and mix with the peptone salt solution in a litre flask.

4. Dissolve the ingredients thoroughly by bubbling live steam through the mixture for half an hour, the flask being suspended in a bath of boiling water during this process.

B.—1. Measure out 500 c.c. ox serum into a "tared" three-litre flask, and add to it 900 c.c. distilled water.

2. Heat in the steam chamber at 100° C. for half an hour.

C.—1. Add the agar mass to the diluted ox serum, shake thoroughly to mix, and weigh the mixture.

2. Titrate the mixture and add sufficient $\frac{n}{1}$ NaOH to adjust the reaction of the mixture to — 3·5.

3. Emulsify 20 grammes nutrose in 100 c.c. distilled water, add the emulsion to the mixture in the flask, and heat in the steamer for thirty minutes.

4. Now weigh the mixture and make up to 2090 grammes by the addition of boiling distilled water.

5. Titrate again and add sufficient standardised $\frac{n}{1}$ lactic acid to render the reaction + 2·5.

6. Cool to below 60° C., add the well beaten whites of four eggs, and heat again in the steam chamber for thirty to forty-five minutes.

7. Filter through papier chardin into a tared two-litre flask and weigh the filtrate; about 1900 grammes or c.c. clear "agar" will be obtained.

8. Fill the nutrose-agar into small flasks in quantities of 150 c.c. (This is most conveniently done by placing the flask to be filled on one pan of a trip balance, counterpoising it and putting on weights to the extent of 150 grammes, then filling the medium into the flask till the pans balance.)

9. If not needed for immediate use, sterilise in the steamer at 100° C. for twenty minutes on each of three successive days.

D.—1. Take as many sterilised test-tubes as there are 150 c.c. flasks of medium and fill 20 c.c. Kahlbaum's litmus solution into each.

2. Heat in the steamer at 100° C. for twenty minutes.

3. Weigh out, and dissolve 1·5 grammes lactose in each tube of litmus solution.

4. Add 1·5 c.c. of a 0·01 per cent. solution of crystal violet (B. Höchst) to each tube.

5. Sterilise in the steamer at 100° C. on each of three successive days.

IX. *Preparation of plates.*

1. For use liquefy a flask of nutrose-agar by immersion in a water bath at 100° C. As soon as the medium is fluid add the contents from one of the prepared test tubes and mix thoroughly.

2. Pour the colored fluid medium into sterile petrie dishes to the depth of three or more millimetres. One flask (of 150 c.c.) will supply sufficient medium for about six petrie dishes of the size in general use in this country, viz. 11 cm. diameter. The larger size, 25 cm. diameter, sometimes employed, are unwieldy and unnecessary.

3. Open each plate, and rest the edge of its cover on the side of the lower half, and so allow the steam to escape freely whilst the agar is solidifying.

4. When the medium has set open and invert the petrie dishes, and place in an incubator running at 60° C. for forty-five minutes (or one running at 42° C. for two hours). At the end of this time the surface of the medium will be firm and *dry*, and ready to inoculate.

5. The material to be plated must first be suspended in either sterile salt solution or sterile broth, and a few drops of the emulsion deposited on the surface of the medium in one of the plates by means of a platinum loop, resting the lid of the plate on the bench during the process of inoculation.

6. Smear the suspension over the surface of the medium by means of the short arm of an L-shaped glass rod, previously sterilised in the bunsen flame and allowed to cool.

7. Without sterilising or recharging the glass rod, smear the surface of a second plate, and then a third, and, if it is considered necessary, a fourth plate.

8. Cover the plates, invert them, label the under surface (which is now uppermost), and incubate, still in the inverted position, at 37° C.

References.

1. v. Drigalski und Conradi.—"Ueber ein Verfahren zum Nachweis der Typhus bacillen," 'Zeitsch. f. Hygiene u. Infektionskrankh.,' Bd. xxxlix, 1902, p. 283.

2. Eyre.—"On the Neutralisation of Culture Media," 'Path. Soc. Trans.,' vol. li, 1900, p. 283.

3. Eyre.—"Nutrient Media of 'Standard' Reaction, etc.," 'Brit. Med. Journ.,' 1900, ii, p. 921.

4. Eyre.—"The Standardisation of Nutrient Media," 'Brit. Med. Journ.,' 1901, ii, p. 788.

5. Kamen.—'Anleitung zur Durchführung bakteriologischer Untersuchungen,' Wien., 1903.

6. v. Koch.—'Die Bekampfung des Typhus,' Berlin, August Hirschwald, 1903.

January 19*th*, 1904.

13. *A case of emphysematous gangrene caused by the Colon bacillus.*

By Leonard S. Dudgeon and Percy W. G. Sargent.

De varietate Gangrenæ emphysematosæ bacillo coli causatâ.

Summarium.

Aeger, vir annorum 24, e vehiculo ad terram ejectus erat.

Crus dextrum graviter vulneratum est, ossibus fractis et cute partibusque mollibus dilaceratis. Quum concussus transisset, crus præcisum est.

Cruris sinistri etsi et cutis lacerata et ossa fracta erant musculi neque contusi nec lacerati sunt; gangræna, tamen, emphysematosa de vulnere pervagans die quinto apparuit.

Membrum per mediam partem femoris præcisum est. Hic, etiam, aderant emphysema, œdema musculorum, viriditasque pinguis.

Lente reciperavit aeger sanitatem.

Nunquam in urinâ aut saccharum aut albumin repertum est.

Culturæ bacteriologicæ ex telis emphysematosis, et aërobice et anaërobice factæ sunt.

In telis ultra aream emphysematosam repertus est staphylococcus pyogenes albus; repertus est insuper bacillus quidam quem monstraverunt experimenta bacillum coli esse.

Hic bacillus apud animalia morbificus fuit, sed emphysemam non generavit, etiam quum in animalia unâ cum staphylococco albo injectus esset.

Hujus ægri sanguis hunc bacillum agglutinavit. In

sanguine, et lymphocyti et myelocyti unâ cum cellulis generis intermedii reperti sunt.

Welch varietatem aërobicam bacilli aërogenis capsulati descripsit quam unam et eamdem cum bacillo pseudo-œdematis maligni (Sanfelici) esse credit: opinatur, præterea, exempla gangrænæ emphysematosæ antea bacillo coli attributa hoc bacillo causari.

Hoc modo bacilli duo dijudicandi sunt. Culturâ in venas cuniculi injectâ, animal statim occiditur: cadavere in cistâ calefactâ (20° C.), horas quattuor et viginti conservato, varietas illa aërobica bacilli capsulati in visceribus vasisque sanguiferis emphysemam generat; bacillus coli nihil efficit.

Illo experimento facto cum bacillo nostro, emphysema nunquam reperta est.

Bacillus ergo noster, bacillus coli communis haberi debet.

The term emphysematous gangrene may now be taken to mean that group of cases which are characterised by the formation of gas in the tissues as the result of their inoculation with pathogenic organisms. This definition should be made clear at the outset, since the subject already suffers under the burden of a redundant nomenclature. The term should not be used to describe cases in which gas occurs merely as a decomposition product in tissues already dead or dying from some other cause.

We wish to emphasise this point because the case which we now bring forward, being definitely due to a member of the *B. coli* group, is of particular interest in view of Prof. Welch's observations, to which reference will be made later on.

Clinical history.

The patient, a previously healthy man of 24, and a railway shunter by occupation, was admitted to St. Thomas's Hospital on October 3rd, 1903, under the care of Mr. Makins, who has kindly allowed us to make use of the case.

He had been standing on the footboard of a moving van

when he was caught under the chin by a signalling wire and thrown to the ground. No one witnessed the accident, but it was tolerably clear from the state on admission that the wheels must have passed over the left leg, but not over the right, although both had suffered compound fracture. He was admitted some two hours after the accident, having been conveyed eight miles by train.

On admission he was suffering from severe shock, the temperature being 96° and the pulse 140. The right leg was hopelessly crushed at about its middle, with great comminution of the bones and much laceration of the soft parts, the foot being cold and devoid of sensation. The left leg presented a compound comminuted fracture at its middle, both bones being extensively splintered. Communicating with the fracture was a gaping wound about two inches long, but there was very little bruising or laceration of the soft parts. The urine was normal. Ether was administered, and both wounds cleansed as thoroughly as possible. The legs were dressed with cyanide gauze and placed in temporary splints.

On the morning of the third day, some thirty-six hours after admission, the patient's condition had so far improved that amputation of the right leg was decided upon. It was now quite cold and lifeless; no pulsation could be felt in the vessels below the fracture, and there was some mottling of the skin. There were neither blebs nor subcutaneous crackling. The temperature had risen to 99·6°, and the pulse had varied from 130 to 140 since admission.

Amputation was performed immediately above the knee by Carden's method, drainage being provided. The operation was well borne. On the fourth day both limbs were dressed. There was a copious discharge from the stump consisting of blood-stained serum, which smelt quite sweet. The left leg was now decidedly swollen, the skin being pale and shiny round the wound, which had been sutured.

On the morning of the fifth day the temperature was 103·2°, and the pulse 132. The patient looked extremely ill, with pale and anxious face and dry tongue. There had been no rigor.

There was no sugar in the urine. The condition of the limb was as follows:—The skin was pale and shiny, and showed a distinct marbled appearance, with bluish cutaneous venules.

Fine crackling, due to gas in the subcutaneous tissues, was present around the wound, and extended to just above the knee. On removing some stitches there was a spirt of brownish fluid, followed by the escape of some bubbles of gas. This fluid had a peculiarly sickening mousy smell. Amputation was performed just below the middle of the thigh by the anterior flap method. The muscles cut through were very œdematous, and the subcutaneous fat showed in places greenish necrotic areas. Some gas crepitation could be felt in the flaps, and could still be obtained on the following day, but had disappeared on the third day after operation. Only a few sutures were placed in the flaps, and free drainage was provided.

For four days after the second amputation the temperature did not fall below 101°, and varied from that level to 103°, whilst the pulse and respiration remained rapid. There was a good deal of thin discharge from the left stump for a few days, which gradually assumed an ordinary purulent character. No further evidence of gas formation appeared. The reparative processes were greatly delayed, the flaps for several days showing very little attempt at healing. The subsequent progress of the case was slow but uneventful, except for the formation of a conical stump on both sides, necessitating the removal of a portion of bone later.

Bacteriological examination.

Culture media were inoculated, and cover-slip preparations were made from the emphysematous tissues, and from a small area of suppuration just beyond. The broth tube obtained from the first-named region was incubated anaërobically at 37° C., while the other tube was treated in a similar manner, only under aërobic conditions. The films prepared from the tissues were stained by Gram, and counter-stained with weak carbol-fuchsin. A short, stout bacillus which did not stain by Gram, and a long, broad bacillus with rounded ends which stained deeply with Gram, were obtained from the emphysematous tissues, but only a Gram staining coccus was seen in the films prepared from the area of suppuration.

Examination of the aërobic cultures.

Agar plates were prepared from the original broth tubes as a

series of three dilutions. Opaque white colonies appeared at the end of twenty-four hours, all of which proved to be identically the same. Sub-cultures which were made on various artificial media were found to have the following characteristics:

Agar.—Thick, pure white, and moist streak, with isolated colonies at the margin.

Jelly.—Similar growth but less marked. Slight liquefaction at the end of forty-eight hours, which gradually increased.

Milk.—This medium was clotted at the end of fifty-six hours' incubation.

Potato.—Thick, white and moist growth on the surface of the potato after forty-eight hours' incubation.

The organism was found to be a coccus which stained well by Gram, and may therefore be classed as a *Staphylococcus albus.*

Examination of the anaërobic cultures.

Well-marked turbidity of the broth cultures was present at the end of twenty-four hours. A short, stout bacillus which decolourised by Gram was obtained from the broth cultures, similar to the organisms found in the tissues. A subculture was made in broth and grown aërobically. A much more luxuriant growth occurred than had been obtained anaërobically, and the original culture was re-incubated anaërobically. A similar bacillus was, however, obtained in each case. Agar plates were prepared in a series of five dilutions, and incubated aërobically. Large, brownish-white coloured colonies, with regular margins and a moist surface, were seen scattered over the surface of all the plates. There was also a somewhat offensive odour. All the colonies appeared to be the same. Subcultures were made in broth and grown aërobically, from which various artificial media were inoculated.

Agar streak.—Thick white line of growth with raised centre and slightly spreading edge. A copious growth had occurred at the end of forty-eight hours.

Glycerine agar.—Similar to agar but more luxuriant.

McConkey's neutral red agar.—Good growth at the end of twenty-four hours, and the media was slightly decolourised. The agar was found to be completely decolourised at the end of eight days.

Glucose agar shake.—Extensive production of gas at the end of twenty-four hours.

Blood serum.—Thick white streak with spreading edge, and complete liquefaction of the serum in ten days.

Potato.—Thick, moist, brownish-white growth was obtained in twenty-four hours.

The medium of Drigalski and Conradi.—Thick, moist, sky-blue coloured growth on the surface of the medium after twenty-four hours' incubation, but there was no change of colour at the end of three weeks' growth.

Gelatine—slant.—Raised colonies with irregular margins but no liquefaction at the end of several days.

Neutral red jelly.—Medium was completely decolourised at the end of eight days.

Glucose jelly shake.—Well-marked production of gas in twenty-four hours.

Litmus cane sugar shake and mannite shake.—Both media were acidified, and there was well-marked production of gas in twenty-four hours. They were completely decolourised in four days.

The medium of Capaldi.—Slight growth and acid production in four days.

The medium of Proskauer.—Good growth without any formation of an acid reaction.

Litmus milk.—Acidified and clotted in four days, and completely decolourised in eight days.

Slight production of indol after eight days' incubation, and very well marked after ten days.

·2 per cent. carbolic broth was found to inhibit the growth of the organism.

The bacillus was found to grow well at the room temperature.

The thermal death-point was found to vary between 50°-60° C.

Morphological characters, etc.

Most of the chief characteristics have already been referred to. The bacillus was found to be sluggishly motile. About four or five flagellæ were attached to each bacillus as shown by Muir's modified Pitfield method.

Filtration tests.

A large flask of broth was inoculated with the bacillus in

question and incubated at 37° C. for several days. A very extensive growth took place, and this was filtered through a Klein's porcelain filter. The filtrate was incubated at 37° C. for twenty-four hours and found to be sterile. It was then poured into several sterile test tubes, re-incubated, and again found to be sterile.

Each tube was then inoculated as follows :—(1) With a standard culture of *B. coli.* (2) Another sample of *B. coli.* (3) The bacillus described by Corner and Singer. (4) Bacillus of Shiga. (5) Bacillus of Flexner. (6) *B. typhosus.* (7) Our bacillus.

These tubes were then incubated for twenty-four hours at 37° C. A slight growth was then obtained in every tube except in the case of our bacillus. A control tube also remained sterile.

The tubes were again incubated for seventy-two hours. A good growth was obtained in every case, most marked in the samples of *B. coli,* least so in the sample of *B. typhosus.* Our bacillus would not, however, grow in its own filtrate.

A few days after the patient's leg had been amputated pockets of pus appeared in the flaps. Broth tubes were inoculated, and pure cultures of the *Staphylococcus albus* and *aureus* were obtained in the usual way.

Film preparations were made of the pus, but only a Gram staining coccus was seen.

Bacteriological examination of the patient's blood.

Ten cubic centimetres of the patient's blood were removed in a sterile glass syringe from the basilic vein of the right arm. This was incubated with 50 c.c. of nutrient broth in an Erlenmyer flask at 37° C. for several days, but was found to be sterile.

This examination was made while the patient's temperature was at its highest.

Pathogenesis.

One cubic centimetre of a twenty-four hours broth culture was injected intra-venously into a rabbit. The animal was very ill for several days, but finally recovered. There was no local lesion.

One and a half cubic centimetres of a twenty-four hours broth

culture were injected into the peritoneal cavity of the same rabbit, with a similar result.

One cubic centimetre was next injected into the subcutaneous tissues of a guinea-pig's leg. A large, red, and œdematous swelling occurred at the end of twelve hours, and the animal appeared to be very ill. At the end of thirty-six hours there was some œdema of the abdominal wall, but there did not appear to be any evidence of emphysema.

One and a half cubic centimetres were injected into the peritoneal cavity of the same animal four days later. At the end of eighteen hours there was general peritonitis and a small quantity of pus in the right flank. A bacillus identical with our own was present in the films of the peritoneal exudation and in the pus. A pure culture was also obtained of the same bacillus from both situations.

Lastly, equal portions of broth cultures of our bacillus and of the *Staphylococcus albus*, which was also isolated from the patient's tissues, were injected subcutaneously into a guinea-pig's leg. A large abscess formed in forty-eight hours, but there was no evidence of emphysema.

Professor Welch considers that it is absolutely essential that the method employed below should be used for the separation of the *B. coli* from the aërobic variety of the *B. aërogenes capsulatus*.

Two cubic centimetres of our bacillus and of the Corner-Singer bacillus were injected intra-venously into rabbits, which were killed about two minutes after the injection had been made. The bodies of the animals were kept for twenty-four hours in an incubator at a temperature of 20° C., and at the end of that time they were carefully dissected, but there was *not* the slightest evidence of *gas* formation in the blood-vessels, or in any of the viscera, in either case.

Agglutination tests.

A filtered agar emulsion was made of our bacillus and tested with various serums, using dilutions of 1-10 and 1-20. Our patient's serum gave a very slight clumping and very slight loss of motility at the end of thirty minutes, more obvious with the weaker dilution. The same dilutions were employed with the blood serum of a patient who was suffering from appendicitis, and a similar result was obtained. No agglutination or loss of motility

was obtained with the serum of the infected guinea-pig. A standard typhoid serum also failed to give any reaction. The patient's serum was found to have no agglutinating properties for the *Staphylococcus albus* isolated from his own tissues.

Examination of the blood.

October 7th, 1903.—Red cells, 1,850,000 per c.mm.; hæmoglobin, 45 per cent.; colour index, 1·25; leucocytes, 19,000 per c.mm.

Fresh blood.—Rouleaux formation was only just perceptible; poikilocytosis was very well marked.

Stained blood.—	Total No.	Percentages.
Polymorphonuclear neutrophils...	366	73·2
Lymphocytes	54	10·8
Large mononuclears	60	12
Intermediate cells	15	3
Myelocytes	3	0·6
Eosinophils	2	0·4
	500	100

No mast cells were seen. Sixteen nucleated red cells were seen while counting 500 leucocytes, of which eleven were normoblasts, three microblasts, and two megaloblasts. Macrocytes, microcytes, and cells showing polychromatophilic and granular degeneration were also present in large numbers. Blood platelets were very numerous.

October 23rd.—Red cells, 1,928,825 per c.mm.; hæmoglobin, 25 per cent.; colour index, ·6; leucocytes, 8,960 per c.mm.

Fresh blood.—Rouleaux formation fairly well marked. Blood platelets were numerous. Poikilocytosis was present.

Stained blood.—	Total No.	Percentages.
Polymorphonuclear neutrophils...	365	73·0
Small lymphocytes	58	11·6
Large lymphocytes	19	3·8
Large hyaline cells	30	6·0
Intermediate cells	13	2·6
Eosinophils	11	2·2
Mast cells	4	0·8
	500	100

Eight nucleated red cells were seen while counting 500 leucocytes, of which seven were normoblasts and one was a megaloblast. Macrocytes and microcytes were numerous. Polychromatophilic and granular degeneration was also observed in many cells.

November 12th.—Red cells, 3,981,250 per c.mm.; hæmoglobin, 60 per cent.; colour index, ·77; leucocytes, 4,940 per c.mm.

Fresh blood.—Rouleaux formation extremely well marked. Very slight poikilocytosis present.

Stained blood.—	Total No.	Percentages.
Polymorphonuclear neutrophils ..	353	70·6
Small lymphocyte	76	15·2
Large lymphocyte	22	4·4
Large hyaline cells	38	7·6
Intermediate cells	0	0
Myelocytes	1	0·2
Eosinophilis	8	1·6
Mast cells	2	0·4
	500	100

No neucleated red cells were seen, and there was complete absence of any degeneration in the erythrocytes.

The intermediate cells which we refer to in this paper appear to occupy a position half-way between the large hyaline cells and the myelocytes, and thus we have every gradation from the small lymphocyte up to and including the myelocyte.

Leishmann's stain was used for the differential blood counts.

Remarks.

The organism isolated from this case is a facultative anaërobe, conforming, with the few exceptions which have already been noted, to the standard type of the *B. coli.*

It will be noticed that we failed to produce emphysema in animals with our bacillus. In this respect our results agree with those of Klein (3), Sanfelice (4), and others, to which Prof. Welch (5), in his admirable and exhaustive paper, has drawn particular attention. He says, "There is a relatively small group of cases of gaseous phlegmon attributed by those reporting them to the Colon bacillus or the Proteus bacillus. In most of these cases anaërobic culture methods were not employed. No one has succeeded in producing experimentally gaseous phlegmon with

either of these bacilli, and I think there is good reason to be sceptical concerning their capacity to produce this disease, unless perhaps the *B. coli* may do so in diabetes."

We may here draw attention to the fact that at no time did sugar appear in the urine of our patient.

Chavigny (1) succeeded in producing emphysematous gangrene when he injected the bacillus which he had isolated from a case together with the *Staphylococcus aureus*. We, however, failed to produce emphysema even when our bacillus was inoculated along with the *Staphylococcus albus* isolated from the same case.

It has already been mentioned that a short and stout bacillus which stained by Gram was also present in the films prepared from the patient's tissues, as well as the bacillus which failed to stain by Gram. We were unable to obtain an organism possessing similar reactions either from cultures grown *anaërobically* or aërobically. We have observed, however, on several occasions in the tissues of both man and animals infected with the *B. coli*, a similar result. We are led to believe that it is a special property of certain members of the *B. coli* family when they are producing severe changes in animal tissues. We intend to fully discuss this point at some future date. The results of the filtration tests, viz. that one variety of the *B. coli* family may be able to grow in the filtrate of another, but not in its own filtrate, will also be discussed in a subsequent communication.

Another point to which we wish to draw attention is that the culture media inoculated from the emphysematous tissues were from the first incubated under strict anaërobic precautions.

Sanfelice described an organism which he isolated from a case of emphysematous gangrene, and to which he gave the name of *B. pseudo-œdematis maligni*. This organ is in many respects similar to the standard type of *B. coli*, and Chavigny has suggested for it the name of *Paracolon bacillus*.

Professor Welch has described an aërobic variety of his *B. aërogenes capsulatus* which "has the power of producing gas abundantly in the blood and tissues of rabbits killed a few minutes after intra-venous injection, a power not possessed by genuine colon bacilli." He attaches great importance to this observation, since it is a test which has not been adopted by those who uphold the view that emphysematous gangrene can be

due to the *B. coli.* He believes that it is identical with the bacillus of Sanfelice, the *B. pseudo-œdematis maligni.*

Corner and Singer (2), in a recent paper read before this Society, described a case of emphysematous gangrene which they considered to be due to the *B. œdematis aërobius* of Sanfelice. They, in common with others, failed to employ what Professor Welch considers to be the crucial test. Mr. Shattock kindly supplied us with a culture of their bacillus, which we subjected to the test above described, but we failed to find the slightest evidence of gas formation in the tissues of a rabbit. In this respect their bacillus exactly corresponds with our own. In those tests which they employed their bacillus differed from ours in these reactions:—(*a*) whereas their bacillus was non-motile, ours was motile; (*b*) indol was much more rapidly produced by their bacillus; (*c*) it did not acidify litmus agar.

Such differences are well known to occur among the various members of the *B. coli* group. On these grounds, therefore, we consider that the bacillus described by Corner and Singer is, like ours, a colon bacillus.

We therefore bring forward our case, and, since the application of Professor Welch's method for the separation of the aërobic variety of the *B. aërogenes capsulatus* from the *B. coli,* that of Corner and Singer also, as examples of that small group of cases of emphysematous gangrene which are caused by the *B. coli.*

There is still, however, one point which has yet to be explained. In these cases of emphysematous gangrene which appear to be due to the *B. coli,* no one has, as Professor Welch remarks, yet succeeded in producing gaseous phlegmon in the tissues of the various inoculated animals. We must remember, however, that the colon bacillus is well known to adapt itself to its surroundings, and it may, therefore, be able to produce emphysema in the damaged tissues of man, although quite unable to do so in the healthy tissues of rabbits and guinea-pigs.

REFERENCES.

1. *Chavigny.*—'Annals de l'Institut Pasteur,' 1897, p. 680.

2. *Corner and Singer.*—'Path. Soc. Trans. London,' vol. lii, part 1, 1901.

3. *Klein.*—'Centralblatt für Bakteriologie,' x, p. 186.

4. *Sanfelice.*—'Annali del Institutio d'Igiene Sperimentale di Roma,' 1892, n. s. i, p. 365.

5. *Welch.*—"Shattuck Lecture," 'Boston Medical and Surgical Journal,' vol. cxlii, No. 4, p. 73, July 26th, 1900; also 'Johns Hopkins Bulletins,' 1900, p. 185.

January 19th, 1904.

14. *The pelvic organs from a case of epithelioma treated by Dr. Otto Schmidt's serum.*

By R. N. Salaman.

The case of epithelioma of the cervix which I wish to bring under notice would have no special claim to your attention were it not that it had attained a certain notoriety in connection with the alleged curative treatment of Dr. Otto Schmidt, of Cologne. This case, which was alluded to by Dr. Jossé Johnson at the Abernethian Society, St. Bartholomew's Hospital, on November 5th, 1903, was there spoken of as suffering from the effects, and indeed dying of the sequences of an overcure—an "inconvenient cicatrisation," as he described it, of the diseased tissues, a cicatrisation of the cancerous parts induced by Dr. Schmidt's serumtherapy.

The clinical history, for which I am indebted to the courtesy of Dr. Kochmann, the medical attendant of the case, is briefly as follows:

On October 22nd, 1901, Mr. Bland-Sutton removed the uterus and right ovary (by the abdomen) for fibro-myomata.

February 5th, 1902.—Mr. Bland-Sutton found cancer of the portio vaginæ.

February 22nd.—Dr. Lewers confirmed the diagnosis and the opinion of Mr. Bland-Sutton that the case was inoperable.

End of April, 1902.—The patient visited Berlin, and a laparotomy was performed by Prof. Landau with a view to complete removal of the affected parts; on finding the disease too advanced he curetted and cauterised the growth in the vagina.

September 3rd, 1902.—Renewed cauterisation. From this time till April the patient's condition was not satisfactory; there was often both hæmorrhage and discharge, but no cachexia.

April 6th, 1903.—Dr. Otto Schmidt visited the patient in London, gave one injection of his serum, which was followed at weekly intervals by two further injections. These injections

produced no reaction except some pain and tension at the site of the puncture.

Towards the end of April, 1903, the patient went to Cologne and was there treated for ten weeks by Dr. Schmidt; on her return to London the treatment was continued till the end of August, when it was stopped, and colotomy was performed by Mr. Mansell Moullin to relieve intestinal obstruction.

Towards the latter end of October sickness occurred daily, and the patient died on November 7th from uræmia.

The *post-mortem* was made by Dr. Schorstein, who handed me the pelvic organs to report on.

The following is the report of the macro- and microscopic examination of the organs, as well as of the uterus and cervix which were removed by Mr. Bland-Sutton and kindly placed at my disposal by Dr. Kochmann.

The parts removed after death comprise the bladder, vagina, rectum, and sigmoid flexure, both kidneys and ureters, and the left ovary. The right ovary and uterus were absent, having been removed by previous operation.

The vagina was closed at its upper end entirely by cicatricial tissue. The mucous membrane of its upper three fourths is replaced by a sloughing and ulcerating surface, a scraping from which, freshly examined, demonstrated the presence of squamous epithelial cells. In the lower part of the anterior wall of the vagina the latter becomes much thickened; demarcation is lost between mucous membrane and connective tissue.

Both ureters pass through the indurated tissue already described in the anterior wall of the vagina. The left, in the latter one and a half inches of its course, is definitely constricted although still admitting of the passage of an ordinary probe. The right ureter towards its end is similarly constricted. Into the vagina there projects from the anterior wall, out of a sloughy base, an artery the size of the ulna; its lumen is almost entirely obliterated by thrombosis.

Tissues immediately around the vagina.—On the peritoneal side there is a great deal of matting and thickening, by means of which the left ovary, in which is a small fibroid, has become adherent to the sigmoid gut. Part of the left ovary is replaced by a small multilocular cyst.

Glands.—None containing growth were found at *post mortem.*

An enlarged gland was, however, discovered along the course of the left external iliac. This was red and soft, and scrapings from it contained no squamous epithelium.

Sigmoid gut.—At a point sixteen inches above anal margin it is constricted, and its mucous membrane superficially ulcerated. The gut wall is firmly adherent to the adhesions in Douglas's pouch and to the left ovary. Two inches above is the wound of a colotomy operation. This stricture of gut has none of the appearances of primary growth.

The kidneys.—In both the pelvis is much distended and the calyces enlarged; this is much more advanced on the left than the right side. The latter kidney has undergone very considerable damage. The right, though less diseased, exhibits signs of a subacute nephritis.

Naked-eye appearance of uterus and fibro-myomata removed by Mr. Bland-Sutton.

These latter, preserved in alcohol, were sent to me by Dr. Kochmann. They consisted of—

(1) The body of the uterus, in which was present a large submucous myoma, several small peritoneal myomata, and interstitial myomata the size of walnuts.

(2) The cervix of uterus. The os uteri has an irregular shape, and is eroded. The substance of the cervix immediately surrounding the canal near the os is soft, and readily breaks down. Within the muscle-tissue of the cervical canal is a small myoma undergoing calcification.

(3) Myoma size of goose's egg, which had apparently come from the uterine specimen.

Microscopical examination.—Os uteri removed at operation.—This shows undoubted epithelioma; the growth is of the ordinary variety; it had penetrated to a considerable degree into the muscular walls of the cervix. Typical pearls are seen, as well as outlying chains of cells in the more distant lymphatics. The epitheliomatous growth is accompanied by an inflammatory reaction, which is not excessive. In some places the growth had penetrated the glandular crypts, bringing about a destruction of the columnar cells of the latter. Little breaking down of the cells of the epithelioma is to be seen.

Sections of the vaginal mucous membrane at its upper end taken post mortem.—The vaginal wall is infiltrated throughout its thickness with epitheliomatous growth. There is an advanced degree of fibrous-tissue formation, together with a considerable amount of cellular infiltration. In the latter are many plasma cells. The cells of the new growth show a strong tendency to degenerate; many have lost their power of staining, more or less absolutely. Within others there is vacuole formation.

It is possible that some of the degeneration may be due to *post-mortem* changes.

The vaginal wall opposite the point of constriction of the left ureter.—Sections show that the tissues are infiltrated with epitheliomatous growth to an advanced degree. Fibrosis and inflammatory reaction are present, but the epithelial growth rather exceeds in quantity the fibrous tissue. A nerve whose course has been along the plane of the section is seen to be split up in all directions by islets of growth. The same degenerative changes are seen in the cells here as were seen in those of the vagina.

Wall of sigmoid gut at point of constriction.—The mucous membrane of the gut itself is in places lost owing to excoriation; much of it, however, is present, and its basement membrane, except in one or two places where it had been pierced by growth from below, is intact. Epitheliomatous growth pervades and destroys the muscular tissue of the gut wall; in quantity it far exceeds the fibrous and muscular tissues. Large groups of cells underlie the basement membrane, whilst it is epitheliomatous growth which, as before stated, has pierced the gut and produced an ulcerated surface within it.

Degenerative changes, though less in quantity, are seen here as elsewhere. Mytosis amongst the epithelial cells was found, although not very general. The inflammatory reaction is here not extreme.

Gland from outside of external iliac artery.—This was the size of a hazel nut. On microscopical section it, at first sight, appeared the seat of extensive epitheliomatous deposit: closer inspection showed clearly that this was not the case; an overgrowth of the endothelium of the gland reticulum had occurred throughout the peripheral sinus and all the main lymphatic cells, and had given rise to the appearance of growth. Besides

this, the gland shows evidence of inflammation in the distension of blood-vessels and occasional hæmorrhage.

The appearances, other than the acute one, are the same as those seen in the enlarged lymph-glands sometimes found secondary to adenoma of the breast.

Myoma removed from the left ovary post mortem.—The structure was that of an ordinary myoma, except that here and there were thin strands of cells which seemed to be of endothelial origin.

Pathological examination of the case shows that it is one of epithelioma commencing at the external os of the cervix (some two years ago), and after removal of the latter it had infiltrated the entire thickness of the vaginal wall, leading later to extensive ulceration of the latter, and, at the same time, by direct extension, to an infiltration of the surrounding organs (ureters and colon). The appearance of the kidneys suggests that the ureters began to be seriously constricted some three to six months before the end. The kidneys are in a state of early pyelo-nephritis.

The growth has spread along the adhesions formed by the peritoneum above the roof of the vagina, to the broad ligament, till it has reached the wall of the sigmoid colon. This has been infiltrated from without inwards.

The growth in the gut is most probably of a later date than that infiltrating the ureters, as is evident from the abundance of the growth as opposed to fibrous tissue, and from the relative absence of degenerative changes.

The appearance of the lymphatic glands suggests some recent acute inflammation as well as a chronic one.

It will be seen, therefore, from these data that no curative effect can be ascribed to the serum tried.

January 5th, 1904.

---

15. *A method for the detection of the* Bacillus enteritidis sporogenes *in water.*

By R. T. Hewlett.

The micro-organism named by Klein the *Bacillus enteritidis sporogenes,* being a filth and sewage microbe, its presence in

water has been suggested as an index of sewage contamination.

Without entering into the question of the significance of this bacillus, I desire to make some suggestions with regard to the method to be employed for its detection in water.

The method recommended by Klein for this purpose is to concentrate the micro-organisms contained in the water (500 to 1000 c.c.) by filtration through a Chamberland filter; a suspension of the microbes deposited upon the walls of the filter-candle is then made in a measured volume of sterile water or broth, say 10 c.c.; 1 c.c. of this suspension is introduced into a series of recently boiled milk-tubes, and these tubes are heated to 80° C. for ten to fifteen minutes, and are finally incubated anaërobically at 37° C. for twenty-four to forty-eight hours. The presence of the *Bacillus enteritidis sporogenes* will be indicated by a peculiar change in the milk (almost clear watery whey, on which floats a raft of honeycombed casein, with disengagement of gas), in which a large, Gram-staining, non-sporing, somewhat anthrax-like bacillus is seen on microscopical examination, the whey being pathogenic to guinea-pigs in amounts of 1 to 3 or 4 c.c., and causing peculiar *post-mortem* appearances.

Now, the method of concentrating water by filtration for the detection either of the *Bacillus coli* or of the *Bacillus enteritidis sporogenes* seems to me to be beset with pitfalls, and I believe is being generally given up. An additional apparatus, difficult of sterilisation, has to be used; the filter may possibly not be perfect, and may allow the micro-organisms to pass through; it is not certain how far the micro-organisms, and especially spores, may not be driven into the pores of the filter by the pressure employed for the filtration; it is uncertain how perfect the suspension can be made, and how many microbes may still be left behind on the walls of the filter; and, lastly, there is a good deal of manipulation and risk of contamination in preparing the suspension. For these reasons, therefore, I consider the filtration method fallacious, and to be avoided, if possible, and for the examination for the *Bacillus coli* the use of *concentrated* media for the larger quantities examined gets over the difficulty.

If milk could be concentrated, the same procedure might be adopted for the detection of the *Bacillus enteritidis sporogenes*,

but this is impracticable. It occurred to me that it might be useful to ascertain how far milk might be diluted and still show the characteristic changes brought about by the *Bacillus enteritidis sporogenes*. To several boiling tubes (viz., large test-tubes), containing 25 c.c. of milk, quantities of tap-water were added, varying from 10 to 60 c.c. to a tube. A few drops of an aqueous suspension of Strand mud, which is always rich in the spores of the *Bacillus enteritidis sporogenes*, were added to each, the tubes were heated to 80° C. for fifteen minutes, and incubated anaërobically. All showed the typical change at the end of forty-two hours. This proves, therefore, that milk may be diluted with at least twice its volume of water, and still will show the changes characteristic of the *Bacillus enteritidis sporogenes*. This experiment has been repeated several times.

The next question is whether, if the spores of the *Bacillus enteritidis sporogenes* are distributed in a large volume of fluid, such as is obtained by diluting milk to this extent, the change in the milk is likely to take place as readily as when the spores are concentrated in a smaller volume. I have at present only one experiment bearing on this point. Into five ordinary milk-tubes 0·5, 0·5, 0·1, 0·1, and 0·1 c.c. of a suspension of Strand mud were introduced respectively. To every one of five boiling tubes, each containing 25 c.c. of milk, 50 c.c. of ordinary unsterilised tap-water (which does not contain the *Bacillus enteritidis sporogenes*) were added, and also amounts of the same suspension of Strand mud corresponding to those added to the ordinary milk-tubes—viz., 0·5, 0·5, 0·1, 0·1, and 0·1 c.c. All the tubes were heated to 80° C. for fifteen minutes, and incubated anaërobically. The result was that of the ordinary milk-tubes those to which 0·5, 0·5, and one 0·1 c.c. of the suspension had been added showed the characteristic change; that is, one spore at least of the *Bacillus enteritidis sporogenes* was present in 0·3 c.c. of the suspension. Of the boiling tubes to which both tap-water and suspension were added, the two which contained 0·5 c.c. of the suspension showed the *enteritidis* change; the other three with 0·1 c.c. each did not. This correspondence between the two series of tubes is as close as could be expected, I think, but some further work is necessary on this point. The change takes place somewhat slower in the large tubes than in the ordinary tubes.

The method which I suggest for the detection of the *Bacillus enteritidis sporogenes* in water without recourse to concentration by filtration is therefore as follows: Boiling-tubes, measuring about 17 centimetres in total depth by about 3 centimetres in diameter, have 40 c.c. of milk introduced into each, and are plugged with wool and sterilised in the ordinary way. At the time of using the tubes are boiled in a water-bath for a few minutes to expel air, and then 60 c.c. of the water to be examined are added to each; that is, the milk is diluted with one and a half times its volume of the water. The wool plug is replaced by a cover of two thicknesses of sterile filter-paper, kept in place by a rubber band, and the tubes are heated to, and maintained at, 80° C. for ten to fifteen minutes. The tubes are then incubated anaërobically at 37° C. in a Bulloch's apparatus, or, what answers just as well, with alkaline pyrogallic in a stoppered museum jar, without a neck, of a size adapted to contain them. By using a dozen tubes 700 c.c. of water can thus be examined. Tubes have been used in preference to flasks, as the former are more readily contained in the jars or apparatus employed for the anaërobic cultivation. Other modifications will readily suggest themselves.

January 19th, 1904.

---

16. *On the relation of* Staphylococcus pyogenes aureus *to rheumatic fever.*

By F. J. Poynton and W. V. Shaw.

[With Plates II and III.]

De ratione Staphylococci aurei *ad febrem rheumaticam.*

(Cum tabulis II, III.)

Summarium.

Multi febrem rheumaticam pyæmiam quamdam attenuatam esse affirmaverunt, febrem scilicet orientem e quavis infectione quæ pyæmiam ipsam generare possit. Nobis

autem, longe secus videtur; quia per clinicam rationem constat febrem rheumaticam per se existere.

In quâ re exempla quinque et viginti proferimus, eaque omnia ex ægris febre rheumatica peremptis desumpta Nam si febris rheumatica nihil nisi pyæmia esset, staphylococcus aureus aliquo modo attenuari debet (staphylococcus nempe ille qui per se maxime in corpore humano pyæmiam efficit), et febrem sæpe rheumaticam efficere debet.

Quod, re ipsa,refelli opinamur.

Nos enim pro certo habemus per illa experimenta quorum rationem reddimus, diplococcum rheumaticum a staphylococco aureo facile discerni posse.

Ex illis omnibus quinque et viginti ægris, ne in uno quidem aderat staphylococcus aureus; in eis qui febre rheumatica interierant staphylococcum deprehendimus nusquam.

Quinetiam comparatione facta, per experimenta invenimus aluid staphylococco aureo effici, aluid diplococco rheumatico.

Ex staphylococco oritur septicæmia aut pyæmia cum abscessibus locis in multis, aut nihil; ex diplococco, aut nihil aut febris rheumatica.

Deinde, si injectio duplex fieret, et diplococci et staphylococci, vel amborum simul vel alterius post alterum, hæc quæ rem convincunt enotavimus.

Quotiens ambo simul injiciebantur totiens fieri solebat ut mors cito consequeretur; in cadavere autem apparent abscessus pyæmici (in quibus demonstratus est staphylococcus areus) necnon arthritis et endocarditis.

Staphyloccus facilius in sanguine deprehenditur, diplococcus in articulis; uterque in telis post mortem inventus est. Quotiens autem injectio staphylococci aurei in-

jectionem diplococci rheumatici subsequebatur, totiens evenit morbus quidam pyæmicus, aut septicæmia quæ cito mortem attulit.

Quantum in medicinâ clinicâ e talibus experimentis tute conjici potest, statuimus tantum abesse ut staphylococcus aureus in infectionibus mixtis febrem rheumaticam efficiat ut magis pyæmiæ aut septicæmiæ letalis causa sit. Casum exponimus pueri quem jam cruris cellulitide laborantem, invaserunt et arthritis et pericarditis.

Non obstantibus cellulitidis indiciis, indicia morbi tantam affinitatem cum febre rheumatica habebant, ut quærendum esse videretur num febre rheumatica laboraret æger.

Puero mortuo repertæ sunt et pericarditis purulenta et arthritis non sine abscessibus locis in multis.

E puero illo et staphylococcus aureus et diplococcus rheumaticus a Alexander Paine culti sunt.

Ex his collegimus *primum*, quod febris rheumaticæ causa haud est staphylococcus aureus aut in infectione simplice aut in mixtâ adhibitus; *deinde*, quod febris rheumatica quoad ad staphylococcum aureum pertinet, nullo modo est pyæmia attenuata.

The object of this paper is to continue the series of investigations which have been made in recent years upon the infective origin of rheumatic fever, and to uphold the view that the disease is, in all probability, a special one, for the clinical entity has already been established by the careful investigations of experienced observers. We rely for our evidence upon clinical, pathological, and experimental studies, firmly believing that it is only by a broad survey of the question that the problems of rheumatic fever can be solved. It is, we believe, essential to place the bacteriological and experimental results side by side with the clinical course of the disease in man, in order to avoid the danger of becoming involved in side issues or half truths, and in support of this we would instance one example, that of endocarditis. All must admit that this is an important result

of rheumatic fever, and a direct consequence of the disease, for there is no trustworthy evidence to point to it as an indirect or secondary result. All must admit too that the allied infections, the pneumococcal, the staphylococcal, gonococcal, and streptococcal (pyogenes so called), may also in some instances produce endocarditis, but the series of events, and the course and history of the cases in any of these infections, are different from the accepted course of a true rheumatism. Again, until recently, experimental endocarditis was a rare occurrence, but now it is a frequent one, and for this reason, that a diplococcus obtained from the damaged valves in that very disease, rheumatic fever, which above all causes endocarditis, possesses the power of producing experimental endocarditis also, with remarkable constancy. Yet in spite of this there are some investigators who draw the conclusion that experiment in this matter is useless, because they have found, naturally enough, that the other micrococci also will sometimes produce endocarditis in animals as they will in man. With that conclusion we do not agree. Another inference that has been drawn is that because some of these other micrococci have produced endocarditis, they are also capable of producing rheumatic fever. We believe that also to be a dangerous inference from imperfect data, and not warranted by a true and careful consideration of the facts. Neither do we believe that rheumatic fever can be considered an example of an attenuated pyæmia in a commonly accepted meaning of the term pyæmia.

At this point we wish to put before you very definitely our view on this question of rheumatic fever considered as an attenuated pyæmia. If those who hold this view imply by it that rheumatic fever is a disease of the pyæmic type in that it shows various local lesions, which contain within themselves at one time or another the infective agent, and further if they wish to emphasise that these lesions tend to take as a rule a benign course, then we also are quite in accord with that view which has been taught us by earlier investigators. But if they wish to imply, as many do, that any disease of the pyæmic type, that is any disease which causes multiple abscesses, will, when of a mild type, produce rheumatic fever, we are directly opposed to them. They then clearly hold that the disease is not an entity, while we hold that it is as definite an entity as tuberculosis.

Again, to speak of attenuation in the description of a disease like rheumatic fever which may be most virulently fatal, is in our opinion an abuse of the meaning of words. Now, if the view be accepted that rheumatic fever is not an entity but is an attenuated pyæmia, it should follow that the *Staphylococcus aureus*, itself a most important cause of pyæmia in man, should also be in its attenuated state a frequent cause of rheumatic fever. But we shall attempt to show that in our experience far from the *Staphylococcus aureus* being a frequent cause of rheumatic fever, it is not a cause of this disease at all, and that therefore the vague conception of rheumatic fever as an attenuated pyæmia must be abandoned so far as the *Staphylococcus aureus* is concerned.

We take as our type of rheumatic fever the disease as it occurs in childhood and in the young adult, and rely entirely on fatal cases which *post-mortem* examinations have confirmed as the true disease. In this way alone can we hope to start from some point of agreement, for we believe that no one will dispute that the *post-mortem* evidences of rheumatic fever are very definite ones, and on the other hand, that if there is not a *post-mortem* examination it is always open to any objector to question the diagnosis.

It is first essential for us to show that it is possible with reasonable care to distinguish the two micro-organisms, the *Staphylococcus aureus* and *Diplococcus rheumaticus*, and that this is possible the following data will show.

A. The *Staphylococcus pyogenes aureus* is about 1·0 μ in diameter, and grows in irregular clumps. It is usually a micrococcus.

The *Diplococcus rheumaticus* measures about 0·5 μ in diameter, and grows in masses on solid media and in chains in liquid media. It is usually a diplococcus.

B. The staphyloccus stains well by Gram's method.

The diplococcus stains feebly by Gram's method.

C. The staphylococcus liquefies gelatine.

The diplococcus does not liquefy gelatine.

D. The staphylococcus grows freely on agar, forming a smooth, white, shining, opaque layer, which on exposure becomes of a deep yellow colour.

The diplococcus grows (but not freely) on agar, forming minute, discrete, white, slightly opaque colonies, and there is no development of colour.

The same is true of litmus agar.

E. The staphylococcus growing in bouillon makes the fluid at first turbid, and later clear with a yellowish sediment.

The diplococcus in the same medium forms a flocculent white precipitate leaving the supernatant fluid clear.

F. The staphylococcus upon potato gives an abundant yellow growth.

The diplococcus grows feebly upon the same medium, forming minute discrete colourless colonies.

G. The staphylococcus grows well and freely upon blood agar. After twenty-four hours at 37° C. it appears as an opaque yellowish paint-like growth spreading out from the track of inoculation. On further incubation it grows into the medium, producing a yellowish brown discoloration.

The diplococcus grows well on blood agar. After twenty-four hours' incubation the colonies appear as distinct, clear, and almost colourless growths along the track of inoculation. On further incubation the colonies increase in size, but do not form a continuous film unless present in great numbers. In time they produce a change of colour, and the red brown of the agar is changed into a yellow brown where the micrococci grow down into the medium. The alteration is very similar to that produced by the pneumococcus.

H. Both micro-organisms grow in alkaline litmus milk, but the diplococcus usually produces more acid, and a firm clot; the *Staphylococcus aureus* less acid and a looser clot.

In 1901 Triboulet and Coyon showed that the diplococcus produced formic acid in nitrogenous media, and acetic acid in milk. In this treatise[1] he gives a careful account of various acids which he has found during the growth of the micro-organism. The production of formic acid has been fully confirmed by Dr. Ainley Walker and Mr. Ryffel.[2] And for us Mr. George Berger, of King's College, Cambridge, has demonstrated that acetic acid is especially formed in the milk medium, confirming again the observations of Triboulet and Coyon.

It is clear then that with care these two micro-organisms can be differentiated from one another.

[1] 'Le Rheumatisme articulaire aigu.'

[2] "On the Pathology of Acute Rheumatism and Allied Conditions," 'Brit. Med. Journ.,' Sept. 19th, 1903.

We next come to these all-important questions: Is the *Staphylococcus aureus* an organism which is present in cases of undoubted rheumatic fever, and can it be isolated from the local lesions? Our experiences and those of Dr. Paine have been very definite, for we have not found this micro-organism, and although we do not pretend that we have always obtained pure cultures in our investigations, yet when we failed to do so we did not find the *Staphylococcus aureus* as the cause of the mixed culture. Needless to say, we attach great importance to this evidence, which appears to us to have a vital bearing on the pathogenesis of rheumatic fever.

Further, though each one of us has isolated the *Staphylococcus aureus* from the human tissues, the conditions we have found in such cases were not to be confused with those of rheumatic fever, when it was possible to make the investigation complete, but if the investigation is incomplete it is easy enough to fall into error. It is, for example, within the experience of all that the *Staphylococcus aureus* may cause an arthritis or pleurisy, which need not reach the stage of suppuration, and which clinically cannot be distinguished from the rheumatic inflammation. So also the tubercular infection may sometimes cause these same fleeting inflammations.

But we do not call these conditions "pseudo-rheumatism," much less rheumatic fever. Nor, again, because we usually meet with staphylococcal arthritis in the suppurative stage, and rheumatic arthritis in the non-suppurative stage, do we think it correct to argue that the rheumatic arthritis is an attenuated variety of the staphylococcal. The tubercular, pneumococcal, staphylococcal, and other infections show different grades of virulence and these assist in producing the differences in the clinical course of the diseases which result. We expect the same to occur with the rheumatic infection, and believe that it does occur, although its recognition is obscured by the use of such adjectives as rheumatoid, septic, or malignant. All the great infectious diseases show their different types of virulence, but for some reason or other when this power is claimed for the rheumatic, it is often objected that rheumatic fever is not really a disease at all but only a peculiar reaction to many infections.

Our position is not based on mere theory. There is the evidence of clinical observation, such as Dr. Paine and Dr.

Poynton put forward in a paper upon malignant endocarditis, published in the 'Medico-Chirurgical Transactions' in 1902. There is also the experimental proof put forward upon that occasion. We will give a further experimental proof with the diplococcus kindly sent to one of us (W. V. S.) by Professor Wassermann. It was obtained from a case of fatal chorea and rheumatic fever. This micro-organism produced in different animals these differing results: a transitory arthritis; an arthritis with endocarditis and infarcts in the lungs, kidneys and spleen; and an acute illness fatal on the third day, with early endocarditis and arthritis.

Thus it must be admitted that rheumatic fever may cause something more than fleeting inflammation.

But, although we have not demonstrated the *Staphylococcus aureus* as a cause of rheumatic fever, it must needs be that our investigations have not been very numerous. Taking into account the earlier work of Dr. Paine and Dr. Poynton, some twenty-five fatal cases of rheumatic fever form the basis of this investigation, and compared with the frequency of the occurrence of the disease, these only represent a small total. It may be objected, then, that this evidence is insufficient, and for this reason we have further studied the experimental results produced in rabbits by the *Staphylococcus aureus* in pure culture.

Before dwelling upon these experimental results we should like to protest against that attitude of mind which expects that a micro-organism should produce infallibly a constant result in animals. Pathogenic organisms are not always pathogenic to man, nor do they always when they are pathogenic produce a regulation disease; the same is equally true of animals. Our excuse for this obvious remark must be this, that from time to time the objection is brought forward that the results of inoculation of animals, especially rabbits, are quite unreliable. That has not been our experience, and we are convinced that, if the disease in the animal is studied as the disease in man, a definite conclusion can be arrived at, so far as rheumatic fever is concerned.

The experimental results from the inoculation of the *Staphylococcus aureus* are well known, but we have repeated them again, and one of us had already repeated them with Dr. Paine[1]

[1] "A Contribution to the Study of Malignant Endocarditis," 'Med.-Chir. Trans.,' 1902.

with the special object in view of producing conditions similar to those which result from inoculation of the diplococcus of rheumatic fever. Since one of us (W. V. S.) has recently recorded[1] the results of inoculation of the diplococcus into monkeys we have been able to amplify this part of the investigation in a direction which is of considerable interest, and which has strengthened our belief in the entity of rheumatic fever.

The results of intravenous inoculation of the *Staphylococcus aureus* into rabbits is in the vast majority of cases to produce: (1) septicæmia and rapid death without local lesions but with much hæmolysis; or (2) pyæmia with abscess formation in the kidneys, spleen, heart-wall or elsewhere; or (3) no result at all.

If, instead of intravenous inoculation, an injection is made locally into such a joint as a knee-joint, the illness is more gradual, but abscesses form in the various organs, and in rare cases endocarditis of the ulcerative type may occur.

The micro-organism can be easily recovered from the blood in which it produces great hæmolysis, and, speaking generally, the tendency of the disease is to produce either a fatal result or no effect.

The usual results of the inoculation of rabbits intravenously with the diplococcus are as follows:—After an incubation period of about one to three days, during which time the animal may show a rise of temperature, the heart becomes excited, arthritis develops in one or more joints, especially those of the knee and carpus, mitral endocarditis, pleuro-pneumonia and pericarditis may follow, and the animal as a rule dies from the cardiac inflammation. Nodules, twitching movements, hæmorrhages, iritis and nephritis have been noticed in exceptional cases. We have never met with an abscess in the kidneys, spleen, liver or heart-wall, but have observed white infarcts in the kidneys. The duration of the illness varies, but, if it is fatal, death usually occurs between seven and twenty-one days. Recovery is not uncommon, and this after very definite symptoms of the infection have developed, or again, chronic articular inflammation with osteo-arthritic changes may result and persist for months, the animal having otherwise recovered. The endocarditis may affect the mitral, aortic or tricuspid valve, but with by far the greatest frequency the mitral is the one attacked.

[1] 'Journal of Path. and Bact.,' December, 1903.

It may be a simple or a vegetative endocarditis, and every grade between these can be demonstrated. Septicæmia we have not seen, even with large injections, but a negative result is not uncommon after small injections.

The diplococcus can be recovered in pure growth from the advanced exudations, but not with certainty from the blood.

FIG. 23.

A B

The hearts of two rabbits. In each the left ventricle is laid open. Specimen A shows acute mitral stenosis; specimen B shows acute aortic stenosis. Results produced by the intravenous injection of *Diplococcus rheumaticus.*

EXPLICATIO FIGURÆ.

Corda cuniculorum quorum in venas cultura bacteriologica diplococci rheumatici injecta erat. In exemplo A foramen auriculo-ventriculare sinistrum coartatur excrescentibus in valvulâ formandis. In exemplo B coartatur aorta simili causâ.

When a monkey has been injected intravenously the following symptoms have been observed by one of us (W. V. S.), and were published in the 'Journal of Pathology and Bacteriology' for December, 1903.

1. In one case a transient arthritis supervening about twelve hours after infection.

2. In another, a multiple arthritis followed by pericarditis; endocarditis, and myocarditis. The exudations were serofibrinous; there were also hæmorrhagic infarcts found in the kidneys; there were some patches of broncho-pneumonia and enlargement of the spleen. Death occurred on the fourth day.

3. In a third case, multiple arthritis of much severity followed infection, and later a mitral systolic murmur developed, but the animal made a good recovery, and is still alive four months later.

FIG. 24.

The heart of a monkey. The left ventricle is laid open and the mitral and aortic valves exposed. Vegetations of considerable size are seen on each segment of the aortic valve. Minute vegetations are also present on the mitral valve. The result of intravenous injection of the *Diplococcus rheumaticus*.

EXPLICATIO FIGURÆ.

Cor simiæ cujus in venas cultura bacteriologica diplococci rheumatici injecta erat. Patefactus est ventriculus sinister. In segmentis singulis valvulæ aorticæ monstrantur excrescentia.

The diplococcus can be recovered in pure growth from the exudations.

We are of opinion that any one who makes an experimental study of these two micro-organisms, or who failing this, trusts to the evidence of repeated observation by others, must conclude that the weight of experimental investigation even when divorced from clinical observation, is opposed to the acceptance of the *Staphylococcus aureus* as a cause of rheumatic fever.

In these investigations of ours care was taken to put these two bacteria under the same conditions out of the body, and to use them in varying degrees of virulence. We are thus convinced that there is a wide difference in the nature of the two infections.

But there is another problem connected with the *Staphylococcus aureus:* Can this micro-organism produce a disease indistinguishable from rheumatic fever if that infection is a mixed one? The clinical study of these mixed infections is one of the greatest difficulty, and at the present time it is almost impossible to judge of the relative parts taken in a disease by two infective agents. It is possible, nevertheless, that something may be learnt from an experimental study of this problem, especially if clinical facts can be steadily accumulated for comparison with such investigations. The two micro-organisms we are studying

FIG. 25.

The heart of a monkey. The left ventricle is laid open and the mitral valve exposed. There are vegetations on the mitral valve and pyæmic abscesses in the myocardium. The result of intravenous injection of *Diplococcus rheumaticus* and *Staphylococcus aureus.*

EXPLICATIO FIGURÆ.

Cor simiæ cujus in venas culturæ bacteriologicæ diplococci rheumatici et staphylococci aurei injectæ erant. In valvulâ auriculo-ventriculari sinistrâ excrescentia, in myocardio abscessus pyæmici, monstrantur.

in this paper give, as we have shown, very different experimental results, and so we have tried the effect of the injection of mixed cultures simultaneously, and the effect also of the injection of the *Staphylococcus aureus* after a previous infection with the diplococcus of rheumatic fever. The animals we have used have been rabbits and monkeys. To make a brief summary of our results: we found in the first place when the injections

were simultaneous that the presence of the *Staphylococcus aureus* impressed itself by rendering the disease unlike rheumatic fever and like pyæmia, and that this, the more virulent organism, caused us special difficulty in making observations, because the death of the animals was often very rapid. If the animal had already shown signs of rheumatic fever, then the staphylococcus killed it with the evidences of septicæmia and abscess formation. The effect of simultaneous injection with both micro-organisms was well shown in the case of a monkey. Death occurred on the fifth day. During this time extensive arthritis developed, with a fibrinous exudation, containing the diplococcus in great numbers. There was mitral endocarditis, and in addition there were pyæmic abscesses in the heart-wall containing vast numbers of the *Staphylococcus aureus*. The staphylococcus and diplococcus were present in the blood. Both micro-organisms were isolated again after death, the diplococcus from the arthritic exudation and the *Staphylococcus aureus* from the blood.

With rabbits also, it was our experience that the diplococcus was most easily found in the joints, and the *Staphylococcus aureus* in the blood, and that the type of the disease was pyæmic. Both micro-organisms were again isolated from the animal tissues. In the solid tissues it is hardly possible, we believe, to differentiate the two micro-organisms under the microscope, for, although the diplococcus is more easily decolourised by Gram's method, that is a comparative test difficult to apply in the tissues. In the exudations the streptococcal arrangement of the diplococcus is helpful, and the occurrence of the staphylococcus in masses in the pyæmic abscesses is also characteristic.

Our preparations will show that it is possible to differentiate the two micro-organisms in the fluid tissues and by culture, but so far as a solid tissue is concerned—for example, a mitral valve—we hesitate to state dogmatically that the micro-organism present is the diplococcus or staphylococcus, or whether both are present in the lesion.

We have alluded to the rapid deaths of the animals from the presence of the *Staphylococcus aureus*. This we endeavoured to overcome by inoculating mixed cultures directly into the knee-joints of rabbits.

EXPLANATION OF PLATE II.

Illustrating the communication by Dr. F. J. Poynton and Dr. W. V. Shaw on "The Relation of *Staphylococcus pyogenes aureus* to Rheumatic Fever." (P. 126.)

FIG. 1.—Experimental rheumatic arthritis. A film from the exudation in the knee-joint of a monkey intravenously injected with *Diplococcus rheumaticus*, showing the presence of the diplococcus. The animal had recovered from a mild attack of arthritis due to a previous inoculation, but succumbed to a second injection with a culture of the *Diplococcus* made two hours after death from a child dead of rheumatic fever. In addition to the arthritis there was endocarditis of the mitral and aortic valves, and fatty degeneration of the myocardium. Death occurred on the fifth day. ($\frac{1}{12}$ immersion; oc. 4.)

FIG. 2.—A section through a pale area of the cardiac muscle of the same monkey. As shown by osmic acid staining, the pallor was due to fatty degeneration; no nuclear stain has been used, the fat droplets alone being blackened by the osmic acid. ($\frac{1}{12}$ immersion; oc. 4.)

FIG. 3.—Experimental arthritis. A film from the exudation in the knee-joint of a rabbit, dead from the intravenous injection of *Staphylococcus pyogenes aureus*. The animal died of pyæmia on the third day. The micro-organism appears as cocci singly or in pairs with flattened faces. ($\frac{1}{12}$ immersion; oc. 4.)

TABULA II.

Ad dissertationem "De Ratione Staphylococci aurei ad Febrem rheumaticam" illustrandam.

F. J. Poynton et W. V. Shaw. (P. 126.)

FIGURA 1.—Arthritis rheumatica experimento causata. Exudatio in genu simiæ cujus in venas injecta est cultura diplococci rheumatici. Aderat insuper endocarditis valvularum auriculo-ventricularis sinistræ et aorticæ, unâ cum myocardii degeneratione adiposa. Animal die quinto mortuum est. (Ob. $\frac{1}{12}$; oc. 4.)

FIGURA 2.—Sectio microscopica myocardii ejusdem animalis, acido osmico subjecta, degenerationem adiposam in telæ muscularis cellulis monstrans. (Ob. $\frac{1}{12}$; oc. 4.)

FIGURA 3.—Arthritis pyæmica experimento causata. Exudatio in genu cuniculi cujus in venas injecta est cultura staphylococci aurei. Animal die tertio mortuum est. (Ob. $\frac{1}{12}$; oc. 4.)

[illegible]

[illegible] Staphyl[illegible] [illegible] illustran[illegible]

[illegible]



Fig. 1.

Fig. 2.



Fig. 3.

Bale, Sons and Danielsson, Ltd.

EXPLANATION OF PLATE III.

Illustrating the communication by Dr. F. J. Poynton and Dr. W. V. Shaw on "The Relation of *Staphylococcus pyogenes aureus* to Rheumatic Fever." (P. 126.)

FIG. 1.—A blood film from a monkey dead from the intravenous injection of the *Diplococcus rheumaticus* together with the *Staphylococcus aureus*. The film shows the *Diplococcus rheumaticus* in chain form, and the staphylococcus in clusters. Both micro-organisms were, moreover, isolated from the tissues. ($\frac{1}{12}$ immersion; oc. 12.)

FIG. 2.—Experimental arthritis; mixed infection. A film from the exudation into the knee-joint of a monkey, dead from the simultaneous intravenous injection of *Diplococcus rheumaticus* and *Staphylococcus pyogenes aureus*. Both micro-organisms are present in the film, the diplococcus in chains, the staphylococcus in groups. ($\frac{1}{12}$ immersion; oc. 12.)

FIG. 3.—Experimental endocarditis; mixed infection. A section through a minute vegetation upon the mitral valve of the heart of a monkey into whose veins were injected simultaneously the *Diplococcus rheumaticus* and *Staphylococcus pyogenes aureus*. The vegetation showed the structure of the ordinary rheumatic form; and the arrangement and appearance of the micrococci lead to the belief that this was a rheumatic lesion. ($\frac{1}{12}$ immersion; oc. 2.)

FIG. 4.—A section through a pyæmic abscess in the myocardium of a monkey, showing great numbers of the *Staphylococcus aureus* in the necrotic tissue. From the same animal as the preceding. Death resulted on the fourth day, from pyæmia. Both the micro-organisms were recovered from the tissues. ($\frac{1}{12}$ immersion; oc. 4.)

TABULA III.

Ad dissertationem "De Ratione Staphylococci aurei ad Febrem Rheumaticam" illustrandam.

F. J. Poynton et W. V. Shaw. (P. 126.)

FIGURA 1.—Sanguis simiæ cujus in venas injecta est cultura diplococci rheumatici unâ cum cultura staphylococci aurei. Monstratur diplococcus rheumaticus in catenarum formâ, staphylococcus in formâ uvarum, dispositus. Utrumque bacterium ex telis etiam cultum est. (Ob. $\frac{1}{82}$; oc. 12.)

FIGURA 2.—Arthritis experimento causata. Exudatio in genu simiæ cujus in venas injecta est cultura diplococci rheumatici unâ cum cultura staphylococci aurei. Monstratur diplococcus rheumaticus in catenarum formâ, staphylococcus aureus in formâ uvarum, dispositus. (Ob. $\frac{1}{82}$; oc. 12.)

FIGURA 3.—Endocarditis experimento causata. Sectio per valvulam excrescentem scissa,—valvulam auriculo-ventricularem sinistram simiæ cujus in venas injectæ sunt culturæ diplococci rheumatici et staphylococci aurei. Læsionem hanc rheumaticam esse credimus, propter micrococci dispositionem et aspectum. (Ob. $\frac{1}{2}$; oc. 2.)

FIGURA 4.—Sectio microscopica abscessus pyæmici in myocardio ejusdem simiæ, staphylococcum aureum intus ostendens. Animal die quarto pyæmiâ mortuum est. Utrumque bacterium in telis repertum est. (Ob. $\frac{1}{12}$; oc. 4.)

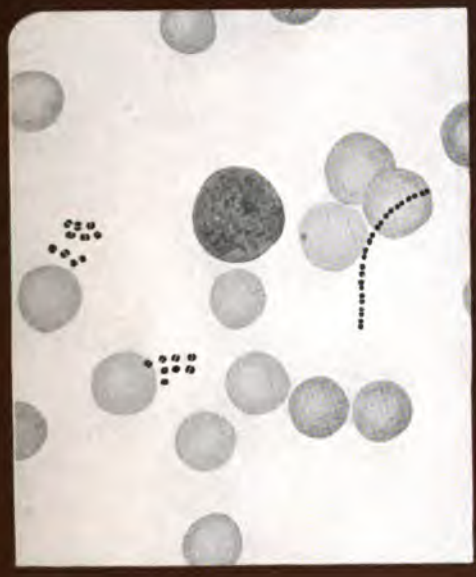

Fig. 1

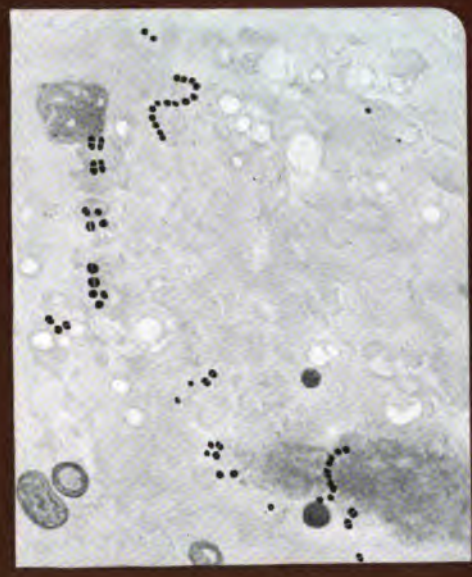

Fig. 2.

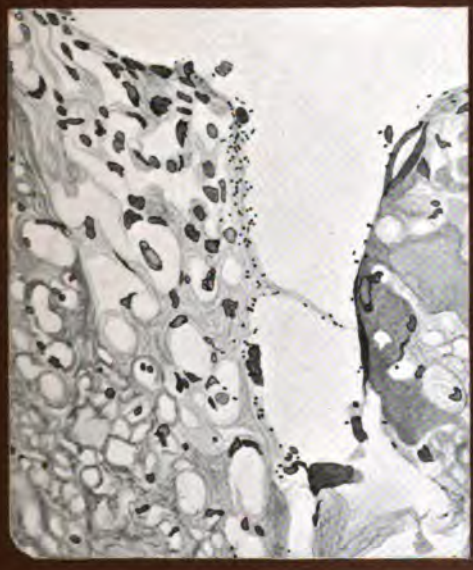

Fig. 3.



Fig. 4.

Bale, Sons and Danielsson, Ltd.

The animals then survived a longer time, but as before, developed pyæmia with abscesses in the liver and spleen. Again the diplococcus was found most easily in the arthritic exudations, the *Staphylococcus aureus* in the blood and spleen.

We conclude, then, that the *Staphylococcus aureus*, when injected into these animals in association with the diplococcus, tends to alter the type of the disease from that of rheumatic fever to that of pyæmia and staphylococcal septicæmia.

This conclusion, so far as one can apply it to clinical medicine, upholds our opinion that rheumatic fever is not a result of the staphylococcus infection, and should a staphylococcal infection supervene upon the rheumatic the tendencies would be twofold:

1. To accelerate death.
2. To produce a condition of pyæmia rather than malignant endocarditis.

Our clinical opportunities of studying mixed infections have been few, but in 1901 Dr. Paine and Dr. Poynton had the opportunity of studying such a case in a child.

A boy aged 8¾ years was admitted on February 15th, 1901, to the Hospital for Sick Children, Great Ormond Street, suffering from cellulitis of the right leg, the result of a sore on the heel. The limb was incised, but no pus escaped. Three days afterwards he complained of pain in the right hip, and the next day of pain in the left hip. Upon the 24th loud pericardial friction was heard, and upon March 1st there was pain in the left shoulder.

Several who saw this child, though well acquainted with the fact of the cellulitis, suspected that this illness might be rheumatic fever because of the low range of temperature, the absence of shivering and rigors, the slight distress, and the loud pericardial friction. The child died on March 4th, and at the post mortem there were found purulent pericarditis and arthritis, with abscesses in the kidneys and lungs. Dr. Paine took cultures from the pericardium and left hip-joint. In each case the result was a mixed one of the *Staphylococcus aureus* and a minute diplococcus. This case exemplifies the point we emphasised earlier—the importance of a complete investigation. Many of the clinical features of the case resembled those of rheumatic fever; the necropsy showed conclusively that it was not rheumatic fever. The bacteriologist

demonstrated it to be a mixed infection, and the *Staphylococcus aureus* a cause of the pyæmic condition.

Throughout we have expressed ourselves dogmatically, for it is necessary for some one to take a definite line upon this question. Yet our spirit is not one of obstinacy, but rather of controversy in the search of truth.

We put forward, then, these two statements based on this investigation:

(1) The *Staphylococcus aureus* is not a cause of rheumatic fever either in simple or mixed infection.

(2) Rheumatic fever is not an attenuated pyæmia, so far as the *Staphylococcus aureus* is concerned.

January 5th, 1904.

---

17. *A case of pyocyaneus pyæmia following otitis media.*

By T. J. Horder.

Instances of the pathological action of *B. pyocyaneus* in man fall into three groups of cases:—

1. The bacillus is found not seldom in suppurative foci in various situations, usually in association with the more common pyogenic organisms, but occasionally alone. In the pus from cases of middle ear disease it seems to be often present; Kossel found it in eight out of fifty-two such cases which he examined, that is, in nearly 16 per cent.

2. During the past few years the bacillus has been isolated by several bacteriologists from the stools in cases of epidemic diarrhœa, notably in some such epidemics affecting children. This has led to the suggestion that some of the minor outbreaks of dysentery may be due to *B. pyocyaneus*. In this connection Houston's recent demonstration of the organism in sewage effluents is important.

3. A very few cases of general pyocyaneus infection have been recorded—perhaps some five or six. Kraunbal reported a case in 1893, and Ehlers reported two cases shortly afterwards.

All the cases which have occurred were collected by Symmers in an article in the 'Medical Magazine' in 1896. The clinical features of the cases closely resembled those of typhoid fever. In some of them there occurred a bullous or gangrenous skin eruption, which was thought to be characteristic of the disease.

It is to this last class of pyocyaneus infections that the case which I bring before you this evening belongs. The patient was a cellarman, aged 33 years, and was admitted to the Great Northern Hospital on account of purulent otorrhœa, severe headache, and fever. The otorrhœa had existed for many years, with intermissions, and had been more profuse than usual for 14 days previous to admission. The disease was bilateral and the right tympanum was perforated. There were no signs of sinus thrombosis, cerebral abscess, or mastoid disease. The temperature varied between 100° and 102°. Headache was the main symptom. A week after admission diarrhœa set in, but was never profuse. The serum test for typhoid fever with 1–20 dilution was twice negative within one hour. The diazo reaction was absent from the urine. A fortnight after admission a leucocytosis of 32,000 was present. On these grounds typhoid fever was excluded, and a diagnosis of septicæmia made. Wasting took place rapidly and delirium became a prominent symptom. During the fifth week of the illness signs of paraplegia occurred, and at the end of the fifth week, after very marked emaciation, the patient died rather suddenly.

At the *post-mortem* examination the brain and its membranes were found to be quite healthy. There was nothing abnormal in the intestines. Both middle ears contained pus, there were several small abscesses in the lungs, and the spinal meninges were distended by pus from the level of the mid-dorsal region to the cauda equina. In all these situations the pus was of a creamy consistency and of a brilliant green colour. Films from the pus showed thick bacilli not staining by Gram's method. Cultures on agar and gelatin, and in broth, gave a pure growth of *B. pyocyaneus*. A careful search was made for the more common pyogenic organisms in plate-cultures, but without any positive result. The heart's blood and splenic pulp were negative to cultivation.

The morphological and cultural characters of the bacillus were those usually described; the organism was pathogenic to

guinea-pigs, producing a hæmorrhagic œdema at the seat of inoculation, and, if sufficient of the broth culture were injected, leading to septicæmia, the bacillus being recovered from the spleen and heart's blood.

April 19th, 1904.

---

18. *A survey of the recorded cases of Hæmatoporphyrinuria not due to Sulphonal.*

By Archibald E. Garrod.

Whereas the recorded examples of hæmatoporphyrinuria in which this symptom has resulted from the administration of sulphonal are now many in number, those in which it has been possible to exclude the influence of that drug or of the closely allied trional remain very few. However such cases undoubtedly do occur, and it is the object of the present communication to bring them into comparison with each other, in order to see what pathological diagnostic or prognostic conclusions may be arrived at from the study of them.

The term hæmatoporphyrinuria is here used to designate a condition in which the urine has a conspicuously abnormal colour, which may have any degree from a dull red to almost complete blackness, and is found to contain abundance of hæmatoporphyrin, as evidenced by the intensity of the spectroscopic absorption bands of that pigment.

As Hammarsten first pointed out, the colour of the darker urines of this class is only in small part due to the hæmatoporphyrin which they contain, and is mainly attributable to the presence of abnormal pigments which show no characteristic absorption spectra, and of which we know but little as yet.

In one of the cases presently to be referred to I was able to remove the hæmatoporphyrin so completely that its spectrum was no longer seen, without appreciably affecting the colour of the urine, and if one adds this pigment to normal urine until its absorption bands are visible with as great intensity as with

the darkest specimens, only a comparatively insignificant change of tint is produced.

It is evident that in the condition known as hæmatoporphyrinuria we are confronted with a profound disturbance of pigment metabolism, and not with a mere increased excretion of hæmatoporphyrin, and it is well that cases of the kind referred to should be dealt with as members of a separate class from those in which, although the quantity of hæmatophorphyrin in the urine is much in excess of the normal traces, the tint of the liquid is not so seriously affected as to attract attention.

In these days of self-medication, it is often no easy matter to exclude entirely the taking of sulphonal by any given patient; but in addition to the internal evidence supplied by the course of the cases themselves, and the presence or absence of associated toxic symptoms, we have conclusive proof of the occurrence of hæmatoporphyrinuria not due to sulphonal in the fact that some cases were put on record before the introduction of the drug in 1888, and even before this compound was first produced by E. Baumann in 1886.

It will be necessary to review briefly the literature of the subject, and the first case which calls for notice was recorded by Baumstark[1] in 1874. This observer isolated from the nearly black urine of his patient two pigments to which he gave the names of urorubrohæmatin and urofuscohæmatin. The spectra of urorubrohæmatin which he figures would justify the conclusion that the case was one of hæmatoporphyrinuria were it not for the analyses which he made of the two pigments, both of which were found to contain considerable quantities of iron. As it is the nature of the case must be regarded as doubtful.

The patient was a man, whose age is not stated, whose disease was diagnosed as Pemphigus leprosus complicated with Lepra visceralis. The full clinical and pathological features which were described by J. H. Schultz[2] in his thesis have not been accessible to me, but the leading points were as follows :—

For seven years previously to 1873, when he died, the patient was attacked each spring by a febrile disorder, which lasted until the autumn and was accompanied by a conspicuous enlargement of the spleen. The temperature, which showed morning

[1] 'Archiv. f. d. ges. Physiologie' (Pflüger's), 1874, ix, p. 568.

[2] 'Ein Fall von Pemphigus Leprosus &cet.' Dissert. Greifswald., 1874.

remissions, sometimes reached 106° F., and there were rigors and hot stages but no sweating. After the fever had persisted for a time bullæ appeared, first upon the nose and afterwards upon other parts of the face, head and neck, and lastly upon the hands. The bullæ at first contained blood-stained fluid but later became purulent and discharged, leaving painful ulcers which produced much scarring and loss of tissue. The nose and pinnæ of the ears were practically destroyed by the repeated attacks. The trunk and lower limbs escaped. In the winters the patient regained fairly good health. According to his account the abnormal colour of his urine had been noticed several years before the annual fever and bullous eruption commenced, and was at first most marked in the mornings. It persisted all the year round but was intensified during the febrile periods. Post mortem the spleen was found to be much enlarged and of a very dark colour.

We owe to Neusser[1] the account of the two next cases, which occurred in 1881. In both cases the red urine was carefully studied and was found to contain large quantities of hæmatoporphyrin. The untreated urines showed the two bands, resembling those of oxyhæmoglobin, which constitute what is now known as the "metallic spectrum" of hæmatoporphyrin. This is not uncommonly the case with sulphonal urines, and the spectroscopic appearances may seriously mislead one who is not familiar with such examinations. In other cases the urine, although acid in reaction, shows the four bands of the spectrum of alkaline hæmatoporphyrin; and in others again the two spectra are superposed.

Neusser's first patient was a man aged 48, who suffered from pleurisy with effusion, from which he made a good recovery. He stated that he first noticed the blood-red tint of his urine at the commencement of his illness in February, 1881, but it persisted during and after his stay in hospital, and when he was last examined, in the November of that year, his urine was still red and showed the same absorption bands.

The second case was that of a man aged 29, who succumbed to pulmonary phthisis and chronic nephritis. His urine had a dirty red colour, was rich in hæmatoporphyrin but contained no blood. Albumen and many casts were present. The observa-

[1] 'Wiener Sitzungsberichte,' Abth. III, lxxxiv, 1881, p. 536.

tions covered only a short period before the patient's death, and there is no record of the previous duration of the abnormal coloration.

The above are the only cases of the kind under discussion which were placed on record before the introduction of sulphonal, but it must be mentioned that the presence of hæmatoporphyrin in *small* quantities in the urine of patients with rheumatic fever was first described in 1880 by MacMunn[1], who then called it "urohæmatin."

The first sulphonal case was recorded by Stokvis[2] in 1889, and others by Salkowski[3] and Hammarsten[4] in 1891.

In 1890, MacMunn[5] gave an account of the urine of a patient under the care of Mr. Cant, of Lincoln. A woman, aged 40, had suffered from exophthalmic goitre for three years, and during that period and previously to the onset of the disease she had passed the dark-coloured urine from time to time. Hæmatoporphyrin was found to be present in abundance in the urine. I am indebted to Mr. Cant and to his partner, Dr. W. H. B. Brook, for some further particulars of this case. The influence of sulphonal may in all probability be altogether excluded; and, indeed, the history of the long-continued or repeated hæmatoporphyrinuria extending over a period of more than three years, carries us back beyond the introduction of that drug in 1888.

Dr. Brook describes the urine as of a dark port-wine colour. He estimated that 700 c.c. contained 0·0081 grammes of iron. The aromatic sulphates were found to be largely in excess of the simple sulphates.

The patient was very anæmic. Red corpuscles, 2,250,000 per c.m.; hæmoglobin, 48 per cent.

In the same year there appeared an account by Ranking and Pardington[6] of two remarkable cases. Both patients were women, aged 41 and 47 respectively, both highly neurotic and subject to chronic gastric catarrh and menstrual disturbances. Vomiting, thirst, anorexia, supra-pubic pain, and profound

[1] 'Proc. Royal Soc.,' 1880, xxxi, p. 211.

[2] 'Nerland. Tijdschrift voor Geneeskunde.,' 1889, ii, p. 413.

[3] 'Zeitschr. f. physiol. Chemie.,' 1891, xv, p. 286.

[4] 'Skandinav. Archiv. f. Physiol.,' 1891, iii, p. 319.

[5] 'Journal of Physiol.,' 1890, xi; 'Proc. Physiol. Soc.,' p. xiii.

[6] 'Lancet,' 1890, ii, p. 607.

prostration were prominent symptoms, but neither patient exhibited signs of organic disease. Both were in bed on milk diet in different rooms in the same house. The patients were not related. One died and the other recovered.

The urines, which presented the now familiar features of hæmatoporphyrinuria, were examined by Russell, MacMunn, and Copeman.

The symptoms observed recall those met with in sulphonal cases, and the simultaneous occurrence in the same house suggests a common origin; but no sulphonal was administered, and I have Dr. Ranking's permission to quote his conviction that, in the fatal case at any rate, no sulphonal had been taken. A dose of acetanelide had been followed by some unpleasant symptoms, which passed off; and in the second case acetanelide had not been given.

Sobernheim's[1] case, published in 1893, was that of a boy aged 13 years, who suffered from typhoid fever. Hæmotoporphyrinuria was a prominent symptom, and it persisted up to the time of the patient's discharge from hospital, although the urine was not then so red as during the febrile period. There was evidence that for years previously the colour of the urine had attracted attention at intervals, and some years before he came under observation the boy had on one occasion been sent home from school because of its dark-red colour. The influence of sulphonal could be definitely excluded in this case; and, except for the hæmatoporphyrinuria, the course of the typhoid fever did not deviate from that ordinarily observed.

In 1898, McCall Anderson[2] recorded two very remarkable cases of brothers aged 26 and 23 respectively. Both had had recurrent attacks of Hydroa æstivalis each summer, in one case from the age of four, and in the other from that of three years onwards. The eruption occurred on the exposed portions of the body, and had produced serious scarring of the nose, face, and hands. It was not attended by constitutional disturbance. The duration of the attacks was increasing.

In the case of the elder brother the redness of the urine was stated to have recurred with each attack of hydroa, and to have disappeared in the intervals; but latterly it had persisted for

[1] 'Deutsche med. Wochenschr.,' 1893, p. 566.

[2] 'British Journal of Dermatology,' 1898, x, p. 1.

some time after the eruptive period was over. The urine of the younger brother was said to have never resumed its normal colour in the intervals between the attacks.

Both urines are described as having a light Burgundy-red colour, and the presence of abundance of hæmatoporphyrin in both was established by the investigations of F. Harris.

In 1889, E. Nebelthau[1] described the case of a female, whose age is not stated, who suffered from congenital syphilis with ulceration of the face and scalp. During a prolonged stay in hospital she continually passed Burgundy-red urine rich in hæmatoporphyrin, and said that her urine had had the same character as long as she could remember. There was no evidence of disease of the intestinal or urinary tracts, her blood was normal, and no abnormal pigment was obtained from the serum or from the fæces.

A case recorded by J. Calvert[2] in 1901 was the only one of this group in which I have had the opportunity of investigating the urine. It was a most pronounced case of hæmatoporphyrinuria, but in some points of detail the urine differed from any one of a number of dark sulphonal urines which I have examined from time to time.

The subject was a woman, aged 32, a general servant, who was admitted to St. Bartholomew's Hospital after a copious hæmatemesis due to a gastric ulcer. She made a good recovery, and in no other respect did the course of the case differ from that of an ordinary one of its kind. The number of red corpuscles and percentage of hæmoglobin rapidly recovered themselves even during the period of dark urine. At first the urine was nearly black, but the colour gradually diminished and had returned to the normal before her discharge from hospital.

Careful inquiry from the patient, her mistress, and her doctor seemed to exclude the taking of any sulphonal, and the patient stated that she had passed similar urine about a year previously, when she was suffering from dyspepsia, but had no hæmatemesis nor melæna.

The last case, described by J. Pal[3] in 1903, is in some

[1] 'Zeitsch. f. physiol. Chemie.,' 1899, xxvii, p. 324.
[2] 'Clinical Soc. Trans.,' 1901, xxxiv, p. 41.
[3] 'Zentralb. f. innere Med.,' 1903, xxiv, p. 601.

respects the most interesting of all. It was that of a man aged 66, who for six years had suffered from occasional attacks, resembling those of paroxysmal hæmoglobinuria, and which were always excited by exposure to cold, or by getting wet through. During each of the three first winters he had three attacks, but by care and warm clothing had then staved them off for three years. He had never had one in summer. The attacks were attended by substernal and lumbar pain, and lasted from twelve to twenty-four hours. During the paroxysms the urine was almost black. In the intervals the colour was normal and the hæmatoporphyrin present did not exceed the normal trace. There was a history of syphilis, and the presence of chronic renal disease was evidenced by hyaline and granular casts and traces of albumen. That the condition was one of hæmatoporphyrinuria was established by the investigations of E. Ludwig.

On reviewing the cases of the above series, the first point which attracts attention is the sex incidence. Hæmatoporphyrinuria from sulphonal is almost confined to women, and male cases are very few and far between. In the cases not due to sulphonal, on the other hand, no such comparative immunity of the male sex is observed, for of the twelve cases quoted, if Baumstark's be included, seven occurred in males and five in females.

It is further noticeable that in a considerable proportion of the cases under consideration the hæmatoporphyrinuria was continuous over long periods, or had recurred at intervals.

At one end of the series stand Nebelthau's case in which it had been present as long as the patient could remember, and Anderson's second case in which it had apparently persisted for twenty years. In some other instances it had recurred or persisted for years, and in Calvert's case the history pointed to a similar attack a year previously.

Still more striking is the fact that in some of these cases the hæmatoporphyrinuria does not appear to have had any evil significance, nor to have materially interfered with the patients' recovery from the illness for which they came under observation.

Except in Ranking and Pardington's cases the associated toxic symptoms met with in sulphonal cases appear to have been wholly wanting.

Some of the cases fall naturally into groups; as for example,

those of Ranking and Pardington, which occurred simultaneously in the same house, and were characterised by the gravity and similarity of the attendant symptoms.

One cannot fail to remark the points of similarity between McCall Anderson's cases and that of Baumstark. In all three there were bullous eruptions, recurring each summer, upon the exposed portions of the body, followed by deep scarring and tissue destruction; and in all there was long persisting hæmatoporphyrinuria or a closely allied urinary change. On the other hand, whereas Baumstark's patient exhibited conspicuous febrile disturbance, with enlargement of the spleen during each attack, those under Anderson's care showed no such evidences of constitutional disturbance.

In Nebelthau's case the only attendant manifestations were those of congenital syphilis, and Pal is inclined to connect the paroxysmal hæmatoporphyrinuria of his patient with antecedent syphilis.

Other patients suffered from such diverse maladies as typhoid fever, phthisis, pleurisy with effusion, exophthalmic goitre and gastric ulcer, which help us little in the attempt to attach a diagnostic value to the urinary phenomenon.

Calvert's case affords additional evidence of a fact to which all the available evidence points, viz. that hæmatoporphyrinuria is not the outcome of an excessive hæmolysis, but rather of perverted hæmoglobin catabolism. The number of red corpuscles and the percentage of hæmoglobin quickly increased, even whilst the hæmatoporphyrinuria persisted. Blood counts in sulphonal cases tell the same story, and Nebelthau states that the blood of his patient, who had had hæmatoporphyrinuria for years, was normal.

The associated hæmatemesis and melæna in Calvert's case were also interesting in connection with the view put forward by Stokvis that hæmatoporphyrinuria due to sulphonal is the result of hæmorrhages into the intestinal canal or into its walls. However, such hæmorrhages have usually been absent in sulphonal cases which have been examined post mortem, and in this case there was a history of a similar urinary condition a year previously, apart from any hæmatemesis or melæna. Moreover, in other cases of hæmatemesis I have failed to find any noteworthy increase of the urinary hæmatoporphyrin.

A study of the minor increases of the amount of hæmatoporphyrin in the urine, which are so commonly met with in disease, leads to the conviction that the chief determining factor is the condition of the liver, and it would appear that diffused morbid conditions of that gland are mainly responsible for increased excretion of the pigment under consideration. As examples may be quoted cirrhosis, fatty degeneration, leukæmic infiltration, nutmeg liver, and the changes in the hepatic parenchyma which accompany rheumatic and other fevers. Lead poisoning, which is very constantly accompanied by increase of urinary hæmatoporphyrin, is a recognised cause of fatty change in the liver.

The evidence forthcoming does not yet justify the assumption that extreme hæmatoporphyrinuria has a similar origin, although marked degeneration of the liver has been noted in some of the sulphonal cases, and notably in one described by Taylor and Sailer.[1] In Neusser's fatal case of phthisis a moderate fatty degeneration of the liver was noted post mortem, but it is a striking fact that in no one of the cases discussed is there any mention of the presence of signs of gross hepatic disease.

In framing any theory of the source and origin of urinary hæmatoporphyrin it is necessary to take into consideration the fact that the pigment is not only met with in the urine, but is present in traces in the bile, in the fæces, even when the bile duct is occluded, and occurs in considerably larger quantity in the meconium of infants than in the urine and fæces of healthy individuals.[2]

It is not improbable that hæmatoporphyrin is an intermediate product of hæmoglobin catabolism which, as the result of morbid changes, chiefly in the liver, may escape the further changes which it normally undergoes, and which, even in health, is to a small extent excreted unchanged. Of the origin of the dark-coloured abnormal pigment which are apt to accompany it in cases of hæmatoporphyrinuria we, as yet, know absolutely nothing.

The points which are brought out by this survey may be briefly summed up in the following conclusions :—

[1] 'Contributions from the William Pepper Laboratory, Philadelphia,' 1900, p. 120.

[2] Bradshaw Lecture R.C.P., 'Lancet,' 1900, ii, p. 1323.

1. Hæmatoporphyrinuria, such as is met with as the result of the taking of sulphonal or trional, occasionally, but very rarely, occurs in cases in which the influence of those drugs can be excluded.

2. Hæmatoporphyrinuria not due to sulphonal is not specially met with in females; indeed, of the recorded cases the larger number have been in males.

3. The phenomenon, when not occurring as one of a train of toxic symptoms, has no specially unfavourable prognostic significance.

4. When not due to sulphonal it is apt to persist for long periods, sometimes over many years, or may recur intermittently or in a paroxysmal manner.

5. Hæmatoporphyrinuria cannot usually be regarded as a symptom of any special disease, nor is there any special evidence of serious implication of the liver in cases in which the symptom is met with in its extreme forms.

March 1st, 1904.

A contribution to the pathology of the thymus gland.

By Leonard S. Dudgeon.

(With Plate IV.)

De Glandulæ Thymi Morbis.

(Cum Tabulâ IV.)

Summarium.

Hujus glandulæ conditionem et normalem et morbidam examinavi apud fœtum (exempla 10), apud infantem (exempla 105), adultum (usque ætatem annorum 70), et insuper apud animalia.

Modus operandi. Cadavere ponderato, thymus in situ primum inspectus est; deinde ablatus, ponderatus, atque scrutatione macroscopicâ et microscopicâ subjectus est.

Glandula normalis apud infantem (annorum 2·5) pondere inter 7 et 10 g., ut opinor, variat.

Hâc ætate glandula bilobata et solida est.

In hâc dissertatione discussæ sunt; thymi conditio in eis (*a*) qui subito interierunt aut qui, inopinato, mortui inventi sunt; (*b*) qui ex morbis diversis acutis interierunt; (*c*) qui ex morbis chronicis emaciati interierunt; (*d*) thymi adulti structura; (*e*) thymi fœtalis structura; (*f*) thymi animalium structura.

(*a.*) Ægrorum qui subito interierunt aut qui, inopinato, mortui inventi sunt, cadavera 16 examinavi.

Horum thymus pondere inter 47·05 g. (infantis annorum 5) et 7·770 g. (infantis anni 1, mensum 4).

Incrementum glandulæ in his casibus facile judicatur quum in memoriam revocemus thymum normalem (apud infantem annorum 2·5) pondere inter 7 g. et 10 g. variare. Dubois in cadaveribus quattuor infantum ex syphile congenitâ mortuorum thymum indagavit: succum e thymo perscisso exudantem opinatus est ex syphilomate liquefactâ ortum esse. In hâc conclusione graviter erravit, nam succus ille in glandulâ normali semper, ut inveni, adest.

Cellulæ, insuper, succi pene omnes lymphocyti sunt.

Succum thymicum ex octo harum glandularum perauctarum bacteriologice examinavi.

In septem exemplis fuit succus sterilis; in uno pneumococcus cultus est.

In plerisque horum sedecim ægrorum rachitis aderat; telæ lymphoideæ pharyngis et thymi incrementum apparuit: auctum est splen, unâ cum glandulis intestinalibus solitariis et agminatis, in tribus ex his exemplis.

Glandulæ thyroideæ incrementum semel inveni; bis, in thymi partibus superficialibus hæmorrhagiam; sæpe

hæmorrhagiam subpleuralem et subpericardialem. Structura penitior glandulæ plerumque normalis reperitur, sed cellularum eosinophilarum multitudo adest.

Harum cellularum aliæ cellulis ossium medullæ similes sunt; aliæ, cellulis eosinophilis sanguinis.

In vasis quoque capillaribus glandulæ hæ cellulæ frequentes sunt.

(*b.*) In eis ex morbis diversis acutis mortuis, thymus pondere esse 5·440 g. inveni.

Plerumque glandula histologice normalis apparet, sed in ægris ex pneumoniâ aut broncho-pneumoniâ mortuis hæmorrhagia aderat.

(*c.*) In eis qui ex morbis diversis chronicis emaciati interierunt; (1) ex marasmo simplice, exempla 15 examinavi. In his exemplis glandula pondere inter 2·68 g. et 0·905 g. variabat. Thymus mollis esse, albus, œdematosus videbatur, sed, ut demonstravit sectio, vere durissimus erat; succus abfuit; (2) ex tuberculose; in exemplis 28, glandulæ pondus minimum 0·345 g. fuit; pondus medium, 3·065 g.; (3) ex aliis morbis chronicis, exempla 13 observavi; in his exemplis variavit thymus pondere inter 2·695 g. et 1·28 g. Fibrosis glandulæ in omnibus his exemplis insignis fuit.

In eis qui ex marasmo simplice aut ex morbis diversis chronicis emaciati interierunt, læsio thymi princeps ex atrophiâ constat. Simul thymus simul corpus tabescit. Conditio, quidem, glandulæ thymi bene corporis conditionem indicat.

Development.

The thymus gland is developed from the hypoblastic lining of the pharynx. It takes origin as a tubular diverticulum from the dorsal portion of the pharyngeal aspect of the third visceral

cleft on each side. This diverticulum has thick epithelial walls, and it grows by rapid proliferation of its cells. The two lobes of the organ are formed by extension downwards on the side of the trachea towards the pericardium, and by meeting the corresponding hypoblastic evagination of the opposite side.

The narrow upper part of the outgrowth remains for a time tubular, and connected with the pharyngeal cleft from which it originates. Ultimately this connection is broken through, and the expanded lower end sends out solid bud-like branches after the manner of an acinous gland. Originally, therefore, the thymus is epithelial in structure, but soon, however, it becomes invaded by connective and lymphoid tissue, so that it is ultimately transformed into a lymphoid organ. The concentric corpuscles of Hassal are the remnants of the epithelial structure of the gland (Cunningham).

It appears probable from Beard's researches in Elasmobranchs, which have been confirmed by other observers, that the leucocytes first make their appearance with the formation of the thymus. Beard is of opinion that they (leucocytes) are formed from the hypoblastic epithelium of the thymus rudiment (Schäfer).

The growth of the gland proceeds during the first two years of life, reaching the maximum period of development at the end of the second year. From this period the size of the gland remains somewhat stationary until about puberty,[1] when the atrophy becomes much more rapid, but from my own experience and that of others, true gland tissue can be found even in adults of advanced age.

Anatomy.

The thymus gland in the new-born child is described by Professor Cunningham as being of pinkish colour and composed of two lateral lobes, generally of unequal size, separated by an intervening fissure. The main portion of the gland is situated within the thorax, but both lobes send prolongations upwards for a short distance into the neck, sometimes reaching to the level

[1] I wish to draw attention to this fact, that although the weight of the gland does not decrease to any extent during this period, the histological changes are considerably altered.

of the thyroid. The thoracic portion of the gland lies in the superior and anterior mediastina, and extend downwards as far as the level of the fourth costal cartilage, lying on the surface of the pericardium and superficial to the innominate veins.

I have frequently noticed in large and enlarged thymus glands a small intermediate or third lobe, and other observers have had a similar experience. In the large majority of cases, however, such as one sees in the *post-mortem* room of a children's hospital, the thymus gland has either one or two lobes. "Small accessory thymic glands may occasionally be found about the periphery of the thymus body," according to Hektoen, but I have never seen anything to justify such a statement. It is also said that the gland may be completely absent, but one would have to satisfy oneself by microscopical examination of the connective tissue from the normal thymic area before such a statement could be accepted as true. Sir John Simon remarks: "I have never noticed absence of the thymus except in cases of true acephalism."

The blood supply is derived from the inferior thyroid, internal mammary, and possibly other arteries, and the gland is drained by the inferior thyroid, internal mammary, and both innominate veins.

The nerve supply, according to most authors, is derived from the vagus and sympathetic trunks.

The cavity in the centre of each lobe is one of the most conspicuous features of large and enlarged thymus glands. The size of the cavity varies according to the freshness of the tissues. If we leave a thymus gland exposed to the air for some hours we shall find at the end of that time that there is a large cavity in each lobe filled with thick yellow, often blood-stained, fluid very similar to pus. The presence of this fluid has frequently given rise to various mistakes, more especially to the diagnosis of abscess formation. Sir Astley Cooper likened this fluid to chyle. If we squeeze a perfectly fresh and normal gland this fluid wells up in all directions, but it apparently increases by the breaking down of the gland tissue, and will eventually give rise to a definite cavity in the centre of the lobe. I consider that this fluid arises from a liquefaction of the elements of the thymus, and it consists almost entirely of lymphocytes.

Histology.

Before we come to consider pathological changes we will refer to a few essential points of the normal histology of the gland.

The thymus gland is enveloped by a sheath of connective tissue which sends off septa from its deep surface which pass into the gland substance and separate the lobules from each other. Each lobule is composed of clusters of adenoid tissue, with a small amount of connective tissue intervening.

A follicle consists of an outer cortical and an inner or medullary portion, but in the former the lymphoid cells are closely packed, whilst in the medulla of the gland they are much less numerous, and the retiform matrix is coarser.

The medulla contains the concentric corpuscles of Hassall. These bodies, which are first observed about the fourth month of fœtal life, are spherical in shape, and consist of flattened cells arranged concentrically around one or more central cells, and are frequently enclosed in a further group of flattened cells, *i. e.* they are compound. I consider, however, that the central portion of Hassall's corpuscles is often found to have undergone some form of degeneration.

These concentric bodies are remnants of the epithelial structure from which the gland was originally developed, and occur as islets, owing to the ingrowth of mesoblastic tissue. Large, pale-stained, somewhat granular nucleated cells form the chief constituents of this portion of the gland. Nucleated red blood-corpuscles have been demonstrated in the medulla of the thymus by various observers, also polymorphonuclear neutrophils.

Lastly, coarsely granular eosinophils are found throughout the gland, but more especially, from my own observations, along the course of the various septa. I will refer to this subject at a later period.

The blood vessels form a fine plexus around the various follicles, and from them capillaries penetrate into the medulla.

Weight of the normal gland.

It is doubtful whether we ought to give any exact normal weight for this gland. It appears to vary enormously in weight according to the health of the child, and according to age.

Anything and everything seem to produce some variation from the so-called "standard weight." I have come to the conclusion, from a careful analysis of my various tables, that the average weight of the gland, from birth up to the age of two years, is roughly about seven to ten grammes. It is usually stated that there is very little alteration in the weight of the gland till puberty, when a rapid degeneration commences. We must be careful to note that these remarks apply solely to the weight of the gland, not to any histological detail. If we examine a thymus from a child aged two years and one from a case at puberty, although the weights may be similar, there is usually marked fibrosis in the latter. It is doubtful if two thymus glands taken from two healthy children of the same age will give the same result, and therefore I wish to emphasise that the weights which I have given as a standard are only roughly approximate and not of any absolute value.

It is most obvious, if we are to judge by the literature, that there is a very great difference of opinion as to the normal weight of the thymus gland. Some observers give definite figures, but make no allowance for the variability in the weight of the gland. I think if the above remarks are expressed in a tabulated form they will serve to illustrate what has been previously stated.

TABLE I.

(*Average weight of the thymus gland according to various authorities.*)

AUTHOR.	STATEMENT
Testut	Weight at birth: 5 grammes.
Arthur Robinson	" " about half an ounce = 14·285 grammes.
Vierordt	" " 24 grammes.
"	Weight at end of second year: 26 grammes.
Robert Howden	Weight at birth about half an ounce.
Osler	" " about 14 grammes.
"	Weight at nine months about 20 grammes.
"	Weight at end of second year: 25—30 grammes.
Ziegler	Weight at birth: 24 grammes.
"	Weight in a child aged two years about 26 grammes.
F. J. Roberts	Weight at birth: half an ounce.

TABLE I—*continued.*

AUTHOR.	STATEMENT.
John Thomson	Weight at birth about half an ounce.
"	Weight about end of second year: 1½—2 ounces.
Hugh Thursfield	Weight of gland under the age of 2½ years is about 6—7 grammes.
Jacobi	Weight at birth from 1—200 grains.
J. S. Fowler	Weight of thymus gland about ½—1 ounce.
John Ruhräh	Weight at birth about 12 grammes.
Friedleben	*Intra-uterine life.*
"	3—5 months: 0·3 grammes.
"	6—7 " 2·3 "
"	8 " 5 "
"	term 13·7 "
	After birth.
"	9 months: 19·8 grammes.
"	9 months to 2 years 26·2 grammes.
"	3 years to 14 " 25·9 "
"	15 " 25 " 21·0 "
"	26 " 35 " 3·0 "

If we refer to the standard text-book on Medicine, Professor Osler's, we find that his observations are almost identical with those of Friedleben. The weight of the thymus gland, as given by both these authorities, is to my mind incorrect. A gland which weighs 25 to 30 grammes is considerably enlarged.

Hugh Thursfield, in a paper based on his own observations which were made at the Great Ormond Street Hospital, came to almost identically the same conclusion as I have. He says, in reference to the weight of the thymus gland as given by Osler, "This statement appears to be erroneous; the weight is enormously exaggerated."

As I have already remarked, Thursfield considers that the weight of the gland varies between 6 to 7 grammes. Testut, likewise, from an average of twenty cases gives the average weight as 5 grammes. Most other writers on this subject have followed in the footsteps of Friedleben. My own results are obtained from an examination of fœtal glands and from the thymus glands of children who have died from acute diseases, *e. g.* broncho-pneumonia. We must be careful, however, not to place too much stress on the weight of the thymus, because some glands which I have examined in children of six years or more, although the gland has been about normal in weight,

yet histologically it has consisted almost entirely of fibrous tissue.

Those who have made *post-mortem* examinations on children in whom the thymus gland has been found to weigh 20, 30, and 40 grammes or more, must be conscious of the striking disproportion between the weight of the child's body and the gland.

Technique.

The children were weighed in each case, as far as it was possible to do so, before the *post-mortem* examination was commenced. The relations of the thymus gland to surrounding structures and its appearance before removal from the body were carefully noted. The weight of the gland and its consistence was ascertained, and in most cases of enlarged or medium-sized glands, a bacteriological and histological examination was made of the thick fluid found in the interior of each lobe.

In a few cases fresh pieces of gland tissue were teased out in normal saline, but the result proved to be of little value.

The various fixing and hardening fluids employed were as follows:—Formalin (10 per cent.), gradually increasing strengths of alcohol, Müller's fluid, and lastly, Orth's bichromate formalin mixture. The last mentioned fixative was found to give by far the best results. Paraffin was used for embedding in every case. Mayer's hæmalum, and eosin proved to be the most satisfactory method for staining sections of the thymus, but Unna's polychrome methylene blue, Mann's methyl blue, Delafield's hæmatoxylin and methyl violet were also employed. Lastly, sections from many of the glands were stained by [1] Van Gieson's method in combination with either Mayer's hæmalum or Delafield's hæmatoxylin.

Films, prepared from the fluid found in the interior of various thymus glands, were either stained immediately by Leishman's or Jenner's methods, or fixed by heat and stained with alcoholic eosin and methylene blue, or dilute carbol fuchsin.

[1] Several samples of this stain were tried, but the formula which I obtained from Dr. Powell White has always given excellent results. Water, 50 c.c.; saturated solution of picric acid in water, 50 c.c.; acid fuchsin 1 per cent., 15 c.c.

Fœtal glands.

I have examined the thymus glands removed from ten fœtuses. The ages varied from the fourth month to term. I carefully examined the viscera in each case, but could not find any evidence of congenital syphilis, but as the fœtuses were obtained from the "slums" of Lambeth, syphilis could not be excluded. The largest thymus gland was obtained from an anencephalic fœtus which was an eighth month child, and was very well nourished. The weight of the gland was found to be 22 grammes, 200 milligrammes. Sanné and others have already drawn attention to the fact that this type of monster has usually been found to have an enlarged thymus. The average weight of the glands in the above cases—if we omit the anencephalic fœtus—is 4 grammes, 575 milligrammes, but if we include the monster, it is 6 grammes, 53 milligrammes. Thick fluid was found in the interior of all the normal and the enlarged thymus glands, and it was found to consist almost entirely of lymphocytes.

It was found impossible to differentiate cortex from medulla in the thymus of the fourth month fœtus, while in the gland of the fifth month fœtus the differentiation was only slightly developed. The histological characteristics of every gland were otherwise normal. A large number of eosinophils were present in most of the glands, but more especially in the thymus of the anencephalic fœtus. Hassall's corpuscles were normal in every case, but were usually much smaller than in children's glands. I consider that if a gland is atrophic, however slight it may be, these bodies are usually found to be enlarged, but there was not a specimen of an atrophic thymus in any of the fœtuses which I examined. Hæmorrhages were present in the thymus of a ninth month fœtus, but I could not detect any inflammatory condition of the lungs to account for it. Weber, however, has recorded hæmorrhages in the thymus at birth.

Histological examination of the fluid present in normal and enlarged thymus glands.

Specimens of the fresh fluid were examined in normal saline solution, and stained films were prepared as already mentioned.

The cells which were found in this fluid consisted almost entirely of lymphocytes; but large hyaline cells, connective tissue corpuscles, eosinophils, and polymorphonuclear neutrophils were also present.

In one case the cells were so degenerated that it was impossible to make a satisfactory examination of the fluid.

Bacteriology.

If we refer to Table VII, we note that in seven out of eight cases examined, the glands were found to be sterile. The only case (Table VII) from which positive results were obtained is of great interest. A child died quite suddenly, and at the *post-mortem* examination no organic lesions were found beyond an enlarged thymus and rickets. The right lobe of the thymus was larger and softer than the rest of the gland, and contained a large abscess cavity which was surrounded by only a thin layer of gland tissue.

Broth and blood serum tubes were inoculated from the pus, which was thick and reddish-brown in colour. Film preparations were stained with Gram and weak carbol fuchsin. Large numbers of capsulated cocci, diplococci, and short chains were seen which stained by Gram. Very small, delicate, transparent and isolated colonies appeared on the surface of the blood serum, and a fine turbidity of the bouillon was noticed at the end of twenty-four hours. Films prepared from both of these media showed a coccus similar to the above, except that it was not capsulated. Sub-cultures were made on gelatine and blood agar. The organism grew well in the form of small isolated colonies on the latter media and in a similar manner on jelly (24° C.), except that the rate of growth was much slower.

The pathogenicity of a broth culture was tested by inoculating ½ c.c. into the peritoneal cavity of a white mouse. Death occurred in about eighteen hours, and a similar organism was grown from the heart blood and spleen. Large numbers of cocci, diplococci, and streptococci were seen in film preparations made from a scraping of the spleen, and which also stained by Gram. I think, therefore, we can describe the organism isolated from the thymic abscess in the above case as the pneumococcus of Fraenkel. Those who have had the opportunity of studying the

relations of the various micro-organisms found in children's diseases, are well aware of the variety of lesions which are produced by the all-important pneumococcus. I think this is, however, the first time the organism has been found in a case of suppuration in the thymus gland. It is a matter of considerable regret that a bacteriological examination of the heart blood was omitted in this case. There is no doubt that in many cases from which the pneumococcus has been isolated from a local lesion, the organism has also been present in the general blood stream. Dr. Branson and myself have already referred to this subject, which is of great practical importance, especially in relation to prognosis. It is possibly owing to this fact, that children and adults in whom the local lesion has been of a benign character have yet succumbed, because such cases have been examples of an unsuspected septicæmia.

All observers are agreed as to the rarity of acute inflammatory lesions of the thymus gland, but cases have been recorded following on acute pericarditis, pleurisy, and Ludwig's angina (Rolleston).

One has to be quite certain that the suspected abscess is not really a collection of thick fluid which is normally present in large and enlarged thymuses. I should advise careful examination of the gland before and after its removal from the body, preparation of films from the fluid, and also that cultures should be made on artificial media.

Lastly, in tuberculosis of the thymus gland, Jacobi and others have demonstrated the presence of the tubercle bacillus in sections of the gland tissue.

The adult thymus.

The gland has been examined in adults of all ages up to seventy. It usually appears to consist of little more than fibrous tissue intimately associated with the connective tissue in the neck, but yet sufficiently conspicuous to enable one to remove the gland at an autopsy even on old people. I did not weigh the gland in any of my cases, as it was so intermixed with the surrounding connective tissue that the results would have been valueless.

Invasion of the gland with adipose tissue appears to be the

FIG. 26.

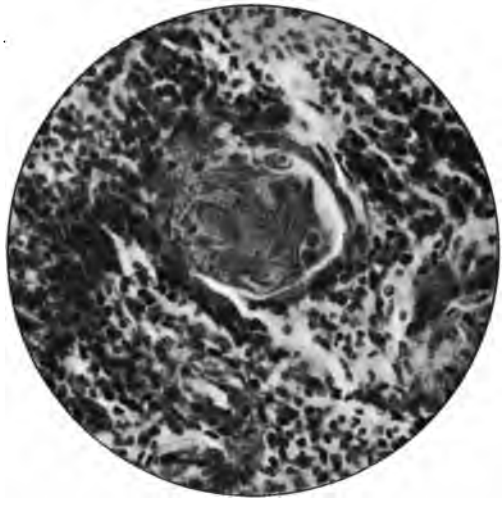

A Hassall corpuscle from the normal thymus of an adult. × 450.

EXPLICATIO FIGURÆ.

Corpusculum (Hassall) glandulæ thymi normalis adulti. × 450.

FIG. 27.

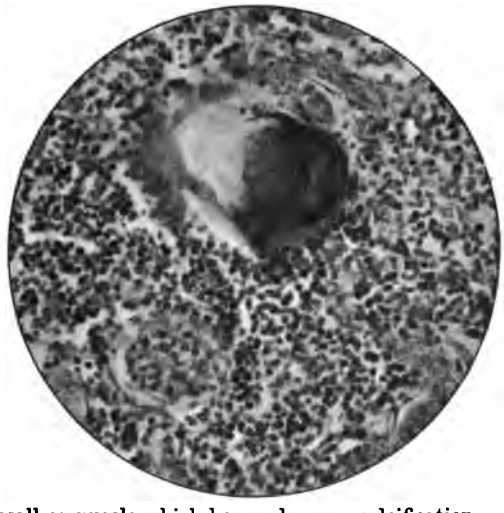

A Hassall corpuscle which has undergone calcification. × 450.

EXPLICATIO FIGURÆ.

Corpusculum (Hassall) quod calcificatum est. × 450.

most common microscopical change in these cases. The adipose tissue separates islets of lymphoid corpuscles, in which there may be one, sometimes two Hassall corpuscles, but rarely more. These bodies may be normal, or may show hyaline, granular, or calcareous degeneration. It is interesting to find that the islets of thymic tissue consist chiefly of lymphoid corpuscles, and not of endothelial cells which we find so constantly in primary and secondary atrophy. I have never seen any eosinophils in these cases. In specimens of the glands such as I have described, stained with Sudan III, or Scharlach, the relations of the adipose tissue to the rest of the gland tissue is shown better than by any other method. I have never failed to find the thymus gland either in children or in adults. It is sometimes so atrophied that it appears to be absent, but a careful search will always reveal thymic tissue in some of the "suspected pieces." The eldest case from which I obtained a specimen of the gland was in a man aged sixty-eight.

Alexander Bruce examined six specimens of adult thymus glands up to the age of forty. His results are very similar to my own. His paper was of great value, as up to that time it was freely stated that the thymus gland was completely absent in adults. Now we know that those observers who were responsible for such statements could only have made a most superficial examination of the thymus gland at the autopsies.

Examination of the thymus glands of various animals.

There is little to be added on this subject to what has been already said about the normal human thymus. Perfectly typical specimens of eosinophils can be demonstrated in the thymus of a young rabbit, especially along the septal walls and in the connective tissue, but also among the lymphoid corpuscles as in the human thymus. I have seen transitional forms of eosinophils more often in the young rabbit's thymus than in specimens from any other source. The thymus in cats, dogs, rabbits, guinea-pigs, rats, mice, etc., are very small, but the glands from sheep and calves are large and bulky, and when perfectly fresh contain the same thick fluid such as is met with in the normal or enlarged thymus of children. The fluid in animals also consists of lymphocytes, and I have found it to be sterile.

In some of the specimens, Hassall's corpuscles were found to have undergone hyaline, granular, and calcareous degeneration. I have never seen in the thymus glands of animals any changes similar to those which occur in primary atrophy.

Tuberculosis.

Tuberculosis of the thymus was found on four occasions. In three of the cases death occurred from general tuberculosis, in the last case the disease was practically limited to the thorax. In every case the thymus was almost entirely converted into a fibrocaseous mass, except for small areas of glandular tissue in one corner of the organ. There was little to be seen microscopically beyond areas of caseation and numerous giant cell systems. The capsule was apparently much thickened. In virulent forms of tuberculosis in children, we not infrequently find almost every gland in the body converted into caseous material, and almost every organ likewise. In such cases, a large group of tubercular glands can usually be found in the superior mediastinum in the position of the thymus. We must be careful to isolate the thymus from these glands, as otherwise we are inclined to consider the whole mass as tubercular lymphatic glands, or to incorrectly include the thymus with the tubercular mass. In the early stages of general thoracic tuberculosis in children, these glands are small but generally show evidence of tubercle; in the more severe cases, however, they are very much enlarged and tend to adhere to all other neighbouring structures. I have not met with an example of either congenital or primary tuberculosis of the thymus, such as has been recorded in the literature.

Demme has recorded a case which he considers to be an example of primary tubercle of the thymus.

A child, born of non-tubercular parents, and whose weight at birth was found to be 2780 grammes, was breast-fed for three weeks, and then fed on cow's milk. From this period the child gradually emaciated, but did not present any physical signs beyond some dulness over the manubicum. Death occurred on the forty-second day of the illness. The thymus gland was found to be enlarged and to contain three small but typical tubercles in which tubercle bacilli were demonstrated. No other organ in the body was found to be tubercular.

Congenital Syphilis.

Paul Dubois directed the attention of the profession to the relation between congenital syphilis and the thymus gland. It is doubtful, however, if any statements ever rested on such an insecure basis. He considered that a thymus gland which contained what he incorrectly described as "pus" was evidence of congenital syphilis. When we refer to the literature of this subject, we find that other observers followed in the same footsteps. Perhaps the greatest error which Dubois made was to consider the thick yellow fluid which he found in the thymus gland as pus. I have drawn attention in this paper to the fact that one of the most characteristic features of a normal or enlarged thymus is the thick fluid found in the interior of the gland. It certainly resembles pus to the naked eye, but is quite unlike it microscopically. There can be little doubt to my mind that the so-called "pus" in the thymus, which Dubois found in four cases of congenital syphilis, was really the fluid which is always present in a normal or enlarged thymus gland. I have never seen a specimen of a thymus gland which could be described as syphilitic. Four cases which, clinically, were examples of congenital syphilis, died of marasmus, but without any evidence of syphilis in the thymus.

Jacobi considers that an excess of connective tissue, whether the gland is large or small, is the most characteristic feature of a congenital syphilitic thymus. He also mentions that there is general thickening of all the coats of the blood-vessels in such cases.

It does not require much evidence to prove Jacobi's statements to be incorrect. We have it on the authority of Henoch, that he has twice seen multiple collections of pus scarcely the size of a pea in the thymus glands of infants. These children developed at the same time many pemphigus bullæ, especially on the palms and soles, and they died in the first week of life.

Ludwig Fürth, as a result of an examination of two hundred autopsies on congenital syphilis, found syphilitic lesions in the thymus gland on seven occasions. It is claimed by some writers, as Dubois remarks, that the thymus gland is the earliest viscus to be attacked, or it may be the only organ to show any evidence of syphilis.

Parrot, on the other hand, has never seen a single example of syphilis affecting the thymus. Dr. J. A. Coutts has discussed the syphilitic question at some length and has come to this conclusion: "I feel justified in my belief that up to the present the involvement of the thymus in inherited syphilis is at least not proven." Personally, I think there is much to commend these remarks, for although there is no reason why the thymus gland should escape in congenital syphilis, yet we require much more evidence than Dubois, Diday, Jacobi and others have brought forward towards proving any special pathological lesion. In fact, those who believe in the inaccurate statements of Dubois would find syphilitic disease of the thymus gland very common, more so even than congenital syphilis itself.

Atrophy.

I have classified atrophy of the thymus under two headings —Primary Atrophy and Secondary Atrophy.

Primary atrophy.—I mean by this expression an atrophy associated with "marasmus," whatever may be the cause, provided no true pathological changes are found at the autopsy, which could have produced such a result. This condition may be produced by improper feeding, want of assimilation of food on the part of the child; and lastly, it is sometimes the only evidence of congenital syphilis.

Professor Ruhräh has drawn attention to the fact that the most characteristic lesion of marasmus, beyond the wasting of fat and muscles, is atrophy of the thymus gland. There is no doubt that this observation is correct. Those who perform *post-mortem* examinations on infants must be struck by the extraordinary appearance of the gland in cases of marasmus. My own observations, drawn from an analysis of fifteen cases, are in accordance with what has been already stated. The thymus gland in some cases might be easily overlooked, as it appears to consist of little more than œdematous connective tissue. If we refer to Table II we notice that the youngest of my cases was ten days old, while the age of the eldest child was two years. There was considerable loss of weight in every case, and in two cases the children were found to weigh about a third of the normal. One of the smallest glands I have ever

seen (No. 2, Table II) was found to weigh only 905 milligrammes, in three others the weight was under 2 grammes, in five under 3 grammes, in five under 4 grammes, while in one case it was found to weigh 5 grammes. The average weight was 2·680 grammes.

If we refer to the condition of the thymus gland we shall

FIG. 28.

A B

A. Thymus, weighing 905 milligrammes, from a case of marasmus. Natural size. B. Thymus, weighing 345 milligrammes, from a case of secondary atrophy. Natural size.

EXPLICATIO FIGURÆ.

A. Glandula thymus 905 mg. pondo, ab ægro ablata ex marasmo mortuo; magnitudinis naturalis. B. Glandula 345 mg. pondo, ab ægro ex morbo chronico emaciato ablata; magnitudinis naturalis.

find that it was frequently described as "white, soft, and œdematous," and this is to my mind the most characteristic evidence of an atrophic thymus. These glands, however, usually cut with great resistance.

I have never seen any thick fluid in an atrophic gland such as is invariably met with in large and enlarged glands. There is also complete absence of any lobular arrangement.

Professor Ruhräh observed from an analysis of eighteen cases of marasmus that the lowest weight of the thymus gland was 1·2 grammes and the highest 7·5 grammes, and that the average

weight for sixteen of the cases was 2·2 grammes. He states that, except for a terminal infection, the atrophy of the thymus was the only pathological lesion found.

Histological changes.—An increase of the fibrous stroma was noted in every case. This tissue spreads irregularly throughout the gland, and divides it into numerous alveoli. In five of the glands the fibrosis was very marked. In most cases there was some thickening of the outer coat of the arteries, but more especially in the five cases in which the fibrosis was most marked. Van Gieson's stain was found to be most useful for the demonstration of this change in the coats of the arteries. In eleven cases the differentiation of cortex and medulla was most imperfect, generally impossible. In one case (No. 4) the divisions of the gland were obvious. Perhaps the most characteristic change present in an atrophic gland is the replacement of the lymphoid corpuscles by cells with spindle-shaped nuclei, and endothelial cells. The amount of lymphoid tissue is very sparse as compared to a normal gland. Giant-cells, some with three or four nuclei, others with only two nuclei, are usually numerous. These cells resemble the small giant-cells which we meet with in the lymphatic glands in lymphadenoma. Hassall's corpuscles appear to be much more numerous, but this is probably due to the marked atrophy of the gland tissue while the corpuscles remain, and thus appear to be out of all proportion to the rest of the gland. I have also found that they are generally much larger than normal. Calcification of these corpuscles was found in many cases. It is not uncommon to find that half a Hassall corpuscle is calcified, while the remainder is granular or homogeneous in appearance, and may be surrounded by a few flattened cells.

Hæmorrhages have been noted in two cases. I will refer to the significance of this fact below. On two occasions the gland substance was replaced by adipose tissue.

It is frequently found that a clear space surrounded by flattened cells appears to be the only evidence of a Hassall corpuscle.

I have found that the concentric corpuscles stain bright red with eosin, and generally yellow, sometimes deep orange, but never red, with Van Gieson's stain. This last statement is of interest, as Professors Ruhräh, Stokes, and Rohrer have observed that

these corpuscles in marasmic glands usually stain *bright rose-red* by Van Gieson's method, although sometimes they stain an orange colour. They suggested that these changes might be due to a chemical alteration in the epithelium of the cell-bodies from kerato hyalin into true hyalin. A large number of specimens of epithelioma of the skin were stained with this picro fuchsin stain for comparison. The epithelial concentric bodies of epitheliomata, which are regarded as kerato hyalin, stained an orange-yellow colour, but a moderate number of these pearls contained globular bodies which stained a rose-red colour, and this was considered as evidence of true hyalin. I consider these statements erroneous. I have never been able to stain Hassall's corpuscles in any of my marasmic glands rose-red, but nearly always bright yellow, and occasionally deep orange colour. Secondly, although there is an exceptional opportunity for the study of squamous-celled carcinomata in the Clinical Laboratory of St. Thomas's Hospital, I have only once succeeded in staining any portion of the concentric bodies rose-red, but have always found, with this exception, that they stain yellow or at the most deep orange colour.[1]

Von Recklinghausen considered that one of the special characteristics of hyaline material was due to the property which it possesses of staining deeply with such acid dyes as acid fuchsin or eosin. Ernst considers that true hyaline material stains a deep red colour with Van Gieson, while colloid stains an orange or a yellowish brown colour, but also that hyaline material which is formed in connective tissue is stained deep red by fuchsin, while that which is derived from epithelial cells stains orange yellow. Von Kahlden considers that Ernst's statements are not justifiable, because true colloid often stains a deep red.

If we compare the brief summary which I have given above of the work of Professor Ernst on hyaline and other forms of degeneration, we shall see that my observations on Hassall's corpuscles and "cell nests" are similar to his, and in direct opposition to the results of Professor Ruhräh.

[1] Mr. Shattock has suggested that these discrepancies may be due to the Van Gieson's stain, which is used in such different manners and in such various strengths by different histologists. I can only say, however, that I have used several samples of Van Gieson's stain, but have only on one occasion obtained results similar to those of Professor Ruhräh.

Secondary atrophy.—I have included under this division such causes as tuberculosis and chronic non-tubercular affections, *e. g.* chronic empyema, which are some of the most important factors in the ætiology of the wasting diseases in children.

(1) *Wasting due to tubercle.*—From an analysis of twenty-six cases (Table III includes twenty-eight cases, but the weight of the thymus gland in two cases was unfortunately omitted) the average weight was found to be 3·065 grammes. The smallest gland I have ever seen is included in this list. It was found to weigh 345 milligrammes (*see* Fig. 28 B, p. 168). The largest specimen weighed 9·310 grammes.

(2) *Wasting due to chronic non-tubercular affections.*—The results are calculated from an analysis of twelve cases. The average weight of the thymus gland was found to be 2·605 grammes. I have omitted one case (No. 9) from this record, because the thymus gland was inseparable from the fibrous mediastinitis, and could only be weighed in conjunction with this tissue. These results are almost identical with the marasmic record, viz. 2·680 grammes. The smallest gland in this series weighed 1·280 grammes, while the largest gland weighed 4·400 grammes.

Naked eye changes of the thymus gland in secondary atrophy.—The gland was frequently described as soft, white, and œdematous, but while these changes are so characteristic in primary atrophy, yet in secondary atrophy they have not the same significance. If we find the thymus corresponds to the above description in a case of marasmus, we are fairly confident that it will present severe microscopical changes, but in the form of atrophy now under discussion we may find that a thymus gland which has been described as "soft, white, and œdematous" may not show any alteration in its minute histology.

In some cases the gland has been found to be hard and nodular owing to tubercular caseation surrounded by dense fibrous tissue. Secondary atrophy teaches us above everything else that we cannot accurately judge the condition of the thymus gland until a microscopical examination has been made.

Microscopical histology.—The capsule of the gland is frequently thickened, and fibrous bands may be seen passing in all directions throughout the gland tissue. The complete alteration in the structure of the thymus gland which has already been described

under "Marasmus," is also found in this form of atrophy, although not so frequently.

Fibrosis of the gland is the commonest microscopical change which we meet with in secondary atrophy. Sometimes it is of a slight degree and only present along the "septa," while in the most severe case the gland consists of little more than fibrous tissue and thickened blood-vessels. The Hassall corpuscles appear to undergo similar forms of degeneration as are met with in marasmic glands, but calcareous degeneration was found in a larger percentage of the cases of secondary atrophy, and might be described as a fairly common lesion. We occasionally find that one half of a Hassall's corpuscle has undergone calcareous degeneration, while the other half is granular.

Endothelial cells and connective-tissue corpuscles are usually found in the most atrophic glands, as met with in marasmus, to have replaced the normal glandular structure, viz. lymphoid corpuscles. Various varieties of "giant cells" are also met with. Eosinophils are either absent or very scarce. We must always remember that these glands which have lost all definite outline, and which appear to have undergone severe degenerative changes, yet microscopically may fail to show more than a slight fibrosis.

Mettenheimer arrived at similar conclusions from an analysis of thirty-seven cases of secondary atrophy of the thymus gland.

Conclusions derived from the study of fifteen cases of primary atrophy and forty-one cases of secondary atrophy.

1. Atrophy of the thymus gland is the most characteristic morbid lesion found in cases of marasmus.

2. In all wasting diseases of children we meet with a similar condition.

3. Atrophy of the thymus gland in children and wasting of the tissues are usually found to go hand in hand.[1]

4. We never find thick fluid in the interior of the gland in these cases.

5. It is usually impossible to differentiate the cortex from the medulla.

6. The most characteristic alterations in the histology of the

[1] Friedleben arrived at a similar conclusion many years ago.

thymus gland in cases of marasmus are as follows:—Fibrosis, which is usually well marked and often accompanied by thickening of the outer coat of the blood-vessels; atrophy of the lymphoid corpuscles, which are replaced by endothelial cells, connective-tissue corpuscles, and small "giant cells," and all varieties of degeneration are found to occur in Hassall's corpuscles.

7. In secondary atrophy we may meet with similar changes in the thymus gland as are met with in marasmus, although less frequently.

8. We are able to judge with some degree of certainty the state of nutrition of a child by a macroscopical and microscopical examination of the thymus gland.

TABLE II.—*Marasmus.*

Number.	Age.	Average weight of children of corresponding ages.	Weight of children in the recorded cases.	Weight of the thymus gland.	Naked eye changes in the thymus gland.	Microscopical histology.	Results of post-mortem examination.
		lbs.	lbs.	grammes.			
1*	$\frac{10}{12}$	10½	6	3·440	White, soft, and œdematous. No evidence of any syphilitic lesion.	Increase of fibrous tissue; lymphoid cells predominate; many Hassall's corpuscles seen.	None.
2*	$\frac{16}{365}$	7½	4½	0·905	Soft, white, and œdematous. No evidence of any syphilitic lesion.	Very marked fibrosis; very few lymphoid cells; many Hassall's corpuscles seen; thickening of blood-vessels.	Acute broncho-pneumonia.
3*	$\frac{7}{12}$	16½	10½	3·555	Very hard; but no evidence of any syphilitic lesion.	Fibrosis; few lymphoid cells; many eosins and Hassall's corpuscles.	Acute lobar and lobular pneumonia.
4	$\frac{14}{52}$	13	6¼	5·150	Red and firm.	Cortex and medulla can be differentiated; marked increase of fibrous tissue; lymphoid cells predominate; many giant cells and no eosins.	None.
5	$\frac{8}{12}$	18	8	1·900	Small, white, and œdematous.	Fibrosis; very few lymphoid corpuscles; many Hassall's corpuscles seen.	Acute broncho-pneumonia.

* These cases were diagnosed clinically as examples of marasmus due to congenital syphilis.

TABLE II.—*continued.*

Number.	Age.	Average weight of children of corresponding ages.	Weight of children in the recorded cases.	Weight of the thymus gland.	Naked eye changes in the thymus gland.	Microscopical histology.	Results of post-mortem examination.
		lbs.	lbs.	grammes.			
6	$\frac{3}{12}$	11	5½	2·140	Red, soft, and small.	Very marked fibrosis; only small islets of lymphoid tissue to be seen; adipose tissue has invaded gland.	None.
7	$\frac{8}{12}$	18	9	3·	Small, red, and firm.	Calcification of some of Hassall's corpuscles, which are increased; many eosins; fibrosis.	None.
8	$\frac{4}{12}$	13	4½	1·150	Red and soft.	Fibrosis; calcification of some of the Hassall corpuscles; lymphoid cells very few.	None.
9*	$\frac{10}{365}$	10½	3½	1·	Small, red, and soft; no evidence of any syphilitic lesion.	Well marked fibrosis; eosins numerous; many hæmorrhages; lymphoid cells replaced by spindle cells and endothelial cells.	None.
10	$\frac{7}{12}$	17	7½	2·82	White, soft, and œdematous.	Extreme fibrosis, etc.	Acute broncho-pneumonia.
11	$\frac{6}{12}$	16	8¾	2·77	White, soft, and œdematous.	Marked fibrosis; great diminution of lymphoid corpuscles; many giant cells; thickened blood-vessels.	Acute broncho-pneumonia.
12	2	26	14	2·560	Very small.	Marked fibrosis; thickening of blood-vessels; numerous spindle cells and endothelial cells replacing lymphoid corpuscles.	Extensive general thrombosis of veins; adrenal hæmorrhage.
13	1	20	8½	3·800	Small and firm.	Marked fibrosis.	Acute broncho-pneumonia.
14	$\frac{10}{12}$	18½	10½	3·470	Soft, white, and œdematous.	Marked fibrosis; large numbers of Hassall corpuscles; atrophy of lymphoid tissue.	Acute broncho-pneumonia.
15	$1\frac{11}{12}$	—	—	2·560	Soft, white, and œdematous.	Enormous increase of fibrous tissue; marked atrophy of gland tissue; great thickening of blood-vessels.	Acute broncho-pneumonia.

* These cases were diagnosed clinically as examples of marasmus due to congenital syphilis.

TABLE III.—*Tubercular Cases.*

Number.	Age.	Average weight of children of corresponding ages.	Weight of children in the recorded cases.	Weight of the thymus gland.	Naked eye changes in the thymus gland.	Microscopical histology.	Results of post-mortem examination.
		lbs.	lbs.	grammes.			
1	$1\frac{4}{12}$	21	$14\frac{1}{2}$	3·55	White, œdematous, and soft.	Gland appears to be normal.	General tuberculosis.
2	6	45	$19\frac{1}{4}$	—	Very small and œdematous. (I could not identify the entire gland).	Extreme fibrosis.	General tuberculosis; sub-diaphragmatic abscess.
3	$\frac{6}{12}$	16	$9\frac{3}{4}$	2·160	White, œdematous, and small.	Only a few areæ of thymus tissue left; extreme fibrosis and invasion with adipose tissue.	General tuberculosis; glands most affected.
4	$5\frac{1}{2}$	44	—	4·20	White, œdematous, and very soft.	Very extensive calcification of Hassall's corpuscles; gland otherwise normal.	Tubercular meningitis.
5	$1\frac{1}{2}$	22	$15\frac{1}{2}$	1·400	White, œdematous, and soft.	Large areæ of caseation; giant cells numerous.	General tuberculosis.
6	$\frac{11}{12}$	20	$16\frac{1}{4}$	5·800	Red and firm.	Calcification of many of Hassall's corpuscles; gland otherwise appeared to be normal.	Tubercular meningitis, etc.
7	$3\frac{1}{2}$	33	$19\frac{1}{2}$	1·870	White, œdematous, and soft.	Fibrosis; atrophy of lymphoid tissue; adipose tissue invaded gland.	General tuberculosis.
8	$\frac{8}{12}$	15	$7\frac{3}{4}$	1·570	White and soft.	Large numbers of Hassall corpuscles; fibrosis; lymphoid corpuscles replaced by endothelial cells.	General tuberculosis.
9	$2\frac{1}{2}$	28	21	5·740	Red and firm.	Gland appeared to be normal; large numbers of eosins.	Acute miliary tuberculosis.
10	6	Child was fairly well nourished.	—	2·370	Small, red, and firm.	Well-marked fibrosis.	Large cerebellar tumour; tubercular meningitis, etc.
11	$2\frac{1}{2}$	28	$14\frac{1}{2}$	2·630	White and soft.	Well-marked fibrosis; atrophy of lymphoid corpuscles; calcification of Hassall's corpuscles.	Tubercular peritonitis.

TABLE III.—*continued.*

Number.	Age.	Average weight of children of corresponding ages.	Weight of children in the recorded cases.	Weight of the thymus gland.	Naked eye changes in the thymus gland.	Microscopical histology.	Results of post-mortem examination.
		lbs.	lbs.	grammes.			
12	7	Large child, but rather wasted	—	5·820	Large, red, and firm.	Some increase of fibrous tissue; gland otherwise normal.	General tuberculosis.
13	4	35	18½	4·350	The lower extremity of the gland was attached to the pericardium and appeared to be fairly normal; the whole of the body was composed of fibro-caseous material surrounded by dense connective tissue; no cavity formation.	Gland tissue almost entirely converted into caseous material; numerous giant cells.	General tuberculosis.
14	$1\frac{9}{12}$	18½	7	2·370	Small and soft.	Well-marked fibrosis.	Thrombosis of the middle menigeal artery; general tuberculosis.
15	2½	28	14	2·500	Small and soft.	Slight atrophy of gland tissue.	Chronic thoracic tuberculosis.
16	2	26	20	1·230	Small, red, and firm.	Considerable atrophy of gland tissue; fibrosis.	General tuberculosis.
17	$1\frac{8}{12}$	24	14½	2·950	Small, œdematous, and white.	Considerable atrophy of gland tissue.	General tuberculosis.
18	3	31	14½	0·950	Extremely atrophied, white, and œdematous.	Extreme fibrosis; very little glandular tissue left.	Chronic abdominal tuberculosis.
19	$1\frac{8}{12}$	22	15½	2·000	Red, firm, and small.	Well-marked fibrosis.	General tuberculosis.
20	—	Great wasting.	—	—	Gland was not weighed, as it could not be separated from the tubercular glands which surrounded it; it, however, appeared to be much atrophied.	Atrophy of gland tissue; increase of fibrous tissue and invasion with adipose tissue; no evidence of tubercle.	General tuberculosis.

TABLE III.—*continued.*

Number.	Age.	Average weight of children of corresponding ages.	Weight of children in the recorded cases.	Weight of the thymus gland.	Naked eye changes in the thymus gland.	Microscopical Histology.	Results of post-mortem examination.
		lbs.	lbs.	grammes.			
21	$1\frac{7}{12}$	$22\frac{1}{2}$	$12\frac{1}{2}$	1·720	Red, firm, and small.	Gland tissue almost entirely converted into caseous material; numerous giant cell systems.	General tuberculosis.
22	8	Wasted.	—	9·310	Large, red, and soft.	Some fibrosis, otherwise normal.	General tuberculosis.
23	$1\frac{11}{12}$	25	18	5·000	Red and soft.	Invasion of gland with adipose tissue; well-marked fibrosis.	General tuberculosis.
24	$\frac{8}{12}$	16	$12\frac{1}{2}$	0·345	Very small and soft.	Extreme fibrosis; lymphoid corpuscles replaced by spindle cells and endothelial cells.	Chronic glandular tuberculosis.
25	$3\frac{6}{12}$	33	18	0·600	Small, soft, and white.	Fibrosis; atrophy of gland tissue; Hassall corpuscles show degenerative changes.	General tuberculosis.
26	$\frac{9}{12}$	18	12	0·922	Small and white.	Well marked fibrosis; no evidence of tubercle.	General tuberculosis.
27	$1\frac{11}{12}$	24	14	3·559	Small and firm.	Large number of hæmorrhages; increase of fibrous tissue; calcification of some of the Hassall corpuscles.	Tubercular ulceration of intestine; caseous mesenteric glands; gangrenous varicella adrenal hæmorrhage.
28	2	26	$14\frac{1}{2}$	4·700	Œdematous and very hard.	Large areæ of caseation; giant cell formation.	Tubercular broncho-pneumonia.

TABLE IV.—*Chronic Non-Tubercular Cases.*

Number.	Age.	Average weight of children of corresponding ages.	Weight of children in the recorded cases	Weight of the thymus gland.	Naked eye changes in the thymus gland.	Microscopical histology.	Results of post-mortem examination.
		lbs.	lbs.	grammes.			
1	$\frac{9}{12}$	18	8	1·600	White, soft, and œdematous.	Marked fibrosis and invasion of the gland with adipose tissue.	Internal hydrocephalus; acute ependymitis.
2	$1\frac{1}{2}$	22	$12\frac{3}{4}$	2·270	White, soft, and œdematous.	Marked fibrosis, so that the gland was divided into numerous alveoli; large numbers of eosins; lymphoid cells much diminished.	Chronic empyema.
3	$\frac{10}{12}$	19	$12\frac{1}{2}$	2·770	Small, red, and firm.	Marked fibrosis; scattered hæmorrhages; no alteration in the lymphoid tissue.	Chronic bronchitis.
4	$\frac{13}{12}$	—	Emaciated.	2·60	Soft and œdematous.	Atrophy of lymphoid tissue, which is replaced by endothelial cells, etc.; very few eosins.	Chronic meningitis; internal hydrocephalus.
5	$\frac{13}{12}$	20	$10\frac{3}{4}$	2·420	Soft, white, and œdematous.	Marked fibrosis.	Chronic broncho-pneumonia; rickets.
6	$\frac{13}{12}$	20	$12\frac{1}{2}$	1·880	Soft, white, and firm.	Marked fibrosis; atrophy of lymphoid tissue.	Chronic non-tubercular meningitis.
7	$1\frac{10}{12}$	25	$14\frac{1}{2}$	4·150	Large, soft and flabby in some places, hard in others.	Gland appears to be normal.	Chronic empyema.
8	$\frac{11}{12}$	20	$6\frac{1}{2}$	3·340	White and œdematous.	Fibrosis of gland; lymphoid tissue appears to be normal.	Congenital cardiac disease.
9	$1\frac{10}{12}$	25	15	9·800 (This record is of no value. See details).	Large, white, and very hard.	Enormous increase of fibrous tissue; large numbers of spindle cells; no eosins seen.	Chronic mediastinitis; adherent pericardium; chronic broncho-pneumonia; small loculated empyema; the thymus gland was embedded in the firm fibrous adhesion which had spread in all directions in the mediastina, and it was therefore impossible to isolate the gland.

TABLE IV.—*continued.*

Number.	Age.	Average weight of children of corresponding ages.	Weight of children in the recorded cases.	Weight of the thymus gland.	Naked eye changes in the thymus gland.	Microscopical histology.	Results of post-mortem examination.
		lbs.	lbs.	grammes.			
10	$\frac{3}{12}$	9	$5\frac{1}{2}$	2·200	Small, red, and firm.	Some increase of fibrous tissue; gland otherwise appeared to be normal.	Congenital cardiac disease; recto-vaginal fistula.
11	$2\frac{1}{2}$	—	Very marked wasting.	1·280	Small, white, and hard.	Well-marked fibrosis; invasion of gland with adipose tissue; atrophy of lymphoid cells.	Post-basal meningitis; chronic hydrocephalus.
12	$2\frac{1}{2}$	28	$14\frac{1}{2}$	2·960	Small and white.	Replacement of lymphoid corpuscles by endothelial cells; no red corpuscles seen in gland.	Very large spleen; subcutaneous hæmorrhages on all the serous membranes and in the mucous membranes.
13	$\frac{3}{12}$	18	$9\frac{1}{2}$	4·400	Small and firm.	Marked fibrosis; numerous hæmorrhages.	Chronic empyema; acute bronchopneumonia.

TABLE V.—*Fœtal Glands.*

Number.	Age.	Average weight of children of corresponding ages.	Weight of fœtuses in the recorded cases.	Weight of the thymus gland.	Naked eye changes in the thymus gland.	Microscopical histology.	Results of post-mortem examination.
		lbs.	lbs.	grammes.			
1	$\frac{8}{12}$	—	Not stated; very large and fat.	22·200	Large, red, and firm; thick, yellowish white fluid in the interior of the gland.	Normal gland; large number of eosinophil cells.	Very large adrenal glands; anencephalic fœtus.
2	$\frac{9}{12}$	—	Well nourished.	5·900	Red and firm.	Normal gland; very large number of eosins.	None.
3	$\frac{5}{12}$	—	—	·600	Small, red, and soft.	Differentiation of cortex and medulla poorly marked; large number of eosinophil cells present; lymphoid cells appear to be normal.	None.
4	$\frac{9}{12}$	—	Do.	3·600	Red and soft.	Gland appears to be normal.	None.
*5	$\frac{8}{12}$	4½	3 lbs. 3 oz.	7·5	Large, red, and soft; thick fluid in the interior of gland.	Normal gland; large number of eosinophil cells present.	None.
*6	$\frac{8}{12}$	4½	3 lbs. 1 oz.	6·	Large, red, and soft; thick fluid in the interior of gland.	Normal gland; large number of eosinophil cells present.	None.
7	$\frac{9}{12}$	7½	7	9·500	Large, red, and firm; thick fluid in the interior of gland.	Large number of hæmorrhages; gland normal; numerous eosinophil cells.	None.
8	$\frac{8}{12}$	1 lb. 8 oz.	1 lb. 2 oz.	2·500	Small, red, and soft.	Gland normal; large number of eosins seen.	None.
9	$\frac{8}{12}$	4½	3¾	6	Large, red, and soft; thick, yellowish white fluid in the interior of the gland.	Gland normal.	None.
10	$\frac{4}{12}$	—	—	About the size of a pea	Lobules of gland were very well marked.	Cortex and medulla not differentiated; no eosinophil cells seen; numerous Hassall's corpuscles.	None.

* Twins.

Acute Diseases.

I have collected thirty-three cases of children of all ages, from seven days up to fourteen years, who had succumbed to the various acute maladies.

Weight of the glands.—The average weight of the glands in these cases was found to be 5 grammes, 440 milligrammes. The largest gland weighed 14 grammes, 70 milligrammes, and the smallest gland weighed 1 gramme, 250 milligrammes. The average weight of the thymus in acute diseases is less than normal, but if we refer to Table VI we shall see that the children also lost weight, some considerably, from the acute diseases from which they had suffered. We therefore ought to expect some diminution in the weight of the thymus—an expectation which is realised.

Cause of death.—The common cause of death was generally found to be some pneumococcic infection, either broncho-pneumonia, lobar pneumonia, empyema, etc. It is impossible to over-estimate the importance of the pneumococcus in children's diseases.

Histology.—Hæmorrhages in the substance of the thymus were found in something like 95 per cent. of the deaths from broncho- and lobar pneumonia. They are also often present in deaths from empyema, but we must remember that acute broncho-pneumonia is by no means a rare cause of death in this disease.

Hæmorrhages have also been described in the thymus gland of the new-born, and in deaths from convulsions, whooping-cough, asphyxia, etc. We found in a microscopical section of the thymus gland obtained from a case of broncho-pneumonia, enlargement of the blood-vessels and scattered hæmorrhages throughout both the glandular and connective tissues. In some cases the gland is normal, in others, beyond the hæmorrhages nothing abnormal is found.

Fibrosis was present in a few cases, but was never accompanied by the various changes in the cellular tissues of the thymus which we meet with in marasmus and advanced "secondary atrophy."

Hassall corpuscles were frequently found to have undergone calcification.

There is little to be found in the literature as regards the

thymus in acute diseases. Peculiar alterations in the histology of the glands have been described in diphtheria, but of these I know nothing.

Dr. T. D. Acland recorded some observations which he had made on the thymus in a case of hæmphophilia, and in one of "purpura." There were spherical masses in the thymus, so large as to be readily visible to the naked eye. They were bounded by a layer of flattened elongated cells, with well-defined nuclei, and contained many epithelioid cells, some of which had a faint indication of a nucleus. The fibrous stroma of the glands was much increased.

I examined the thymus of two or three children who had purpura among other symptoms, but I never found any changes similar to those described by Dr. Acland. Dr. Acland informed me in a private communication that he was not sure of the nature of the bodies which he described.

TABLE VI.—*Acute Diseases.*

No.	Age.	Average weight of children at the various ages, in lbs.	Weight of my cases, in lbs.	Weight of thymus glands in grammes and milligrammes.	Appearances of the thymus glands at the autopsies.	Microscopical examination of the glands.	Cause of death; changes found at the autopsies.
1	2	26	20¼	6·480	Red and firm.	Scattered hæmorrhages; otherwise normal.	Acute empyema; acute meningitis.
2	2	26	18½	5·700	Ditto.	Calcification of some of Hassall's corpuscles; increase of fibrous tissue; lymphoid corpuscles normal.	Confluent broncho-pneumonia.
3	$\frac{12}{20}$	20	12½	3·510	White, soft, and œdematous.	Gland appears to be absolutely normal, except for hæmorrhage.	Acute broncho-pneumonia.
4	$\frac{4}{12}$	—	Well nourished.	2·920	Firm gland.	Increase of fibrous tissue dividing gland into pseudo-acini; numerous eosins.	Acute pneumococcic meningitis.
5	2½	—	Ditto.	5·720	Very œdematous; white and soft.	Increase of fibrous tissue which is very œdematous and infiltrated with leucocytes; lymphoid tissue normal.	General pneumococcis infection.
6	$\frac{5}{12}$	15	15	9·420	Large, red, and firm; thick fluid in interior of gland.	Normal; very large number of eosins.	Acute broncho-pneumonia.

TABLE VI.—*Acute Diseases*—continued.

No.	Age.	Average weight of children at various ages, in lbs.	Weight of my cases, in lbs.	Weight of thymus glands in grammes and milligrammes.	Appearance of the thymus glands at the autopsies.	Microscopical examination of the glands.	Cause of death; changes found at the autopsies.
7	$\frac{11}{12}$	20	12	2·720	Red, soft, and small.	Hæmorrhages present; increase of fibrous tissue which was œdematous.	Acute broncho-pneumonia.
8	7	—	Well-developed boy.	6·240	Large, red, and firm.	Gland normal; numerous eosins.	Pyæmia; acute osteo-periostitis
9	$1\frac{4}{12}$	21	$11\frac{1}{2}$	3·660	Red, small, and firm.	Numerous hæmorrhages; slight fibrosis.	Acute broncho-pneumonia.
10	$\frac{5}{12}$	15	$8\frac{1}{2}$	1·250	Very small and firm.	Marked fibrosis; many eosins.	Pneumococcic arthritis; pneumococcic septicæmia.
11	$\frac{6}{12}$	15	$8\frac{1}{2}$	2·200	Red, firm, and small.	Gland normal.	(Epidemic diarrhœa); no morbid lesions.
12	$\frac{11}{12}$	13	$7\frac{3}{4}$	6·255	Large, red, and firm.	Gland normal; numerous hæmorrhages.	Acute broncho-pneumonia; (diarrhœa and vomiting).
13	$\frac{9}{12}$	18	$10\frac{1}{2}$	4·250	Soft, white, and œdematous.	Well-marked fibrosis; many eosins.	Pneumococcic arthritis; pneumococcic septicæmia.
14	$\frac{6}{52}$	$9\frac{1}{2}$	$6\frac{1}{2}$	4·620	Red and firm.	Numerous hæmorrhages; slight calcification of many of Hassall's bodies; large numbers of eosins.	Acute broncho-pneumonia.
15	$\frac{10}{12}$	$18\frac{1}{2}$	$12\frac{1}{2}$	4·270	Red and firm.	Gland normal; no hæmorrhages seen; many eosins.	Acute broncho-pneumonia; empyema.
16	$\frac{6}{12}$	—	Very fat child.	8·060	Large, red, and firm.	Gland normal; many eosins.	Acute broncho-pneumonia; rickets.
17	$\frac{11}{12}$	19	$14\frac{1}{2}$	4·040	Soft, white, and œdematous.	Gland normal; many eosins.	Lobar and lobular pneumonia.
18	$\frac{10}{12}$	$18\frac{1}{2}$	13	5·545	Red and firm.	Gland normal, except for numerous hæmorrhages; many eosinophils.	Acute broncho-pneumonia; fatty liver.
19	$\frac{6}{12}$	17	14	7·100	Red and firm.	Slight fibrosis; calcification of some of Hassall's bodies; many eosins.	Empyema.
20	$\frac{5}{52}$	9	$6\frac{1}{2}$	3·250	Red and firm.	Gland normal; many eosins.	No morbid lesions; acute diarrhœa.
21	$1\frac{3}{12}$	21	$12\frac{1}{2}$	—	Soft, white, and œdematous.	Well-marked fibrosis; many spindle-shaped connective tissue cells infiltrating gland.	Acute broncho-pneumonia: acute empyema.

TABLE VI.—*Acute Diseases*—continued.

No.	Age.	Average weight of children at various ages, in lbs.	Weight of my cases, in lbs.	Weight of thymus glands in grammes and milligrammes.	Appearance of the thymus glands at the autopsies.	Microscopical examination of the glands.	Causes of death; changes found at the autopsies.
22	—	—	12½	2·500	Small, red, and firm.	Many hæmorrhages.	Gangrenous varicella; acute broncho-pneumonia.
23	$\frac{4}{12}$	13	9½	3·050	Small, red, and firm.	Slight fibrosis; many hæmorrhages, otherwise normal gland.	Acute broncho-pneumonia.
24	$\frac{5}{12}$	16	13	9·200	Large, red, and firm.	Many eosins; some of Hassall's corpuscles calcified; gland otherwise normal.	Retro-pharyngeal abscess.
25	2	26	20	6·300	White and soft.	Normal; many eosins.	Lobar and lobular pneumonia.
26	$1\frac{3}{12}$	20½	17½	1·600	White and soft.	Numerous hæmorrhages; gland infiltrated with adipose tissue; marked fibrosis.	Acute broncho-pneumonia; adrenal hæmorrhage.
27	$3\frac{13}{52}$	7½	7½	1·800	Red and soft.	Numerous hæmorrhages; well marked fibrosis; very few eosins; Hassall's bodies normal.	Acute general pemphigus.
28	$\frac{1}{52}$	7	9	7·850	Large, red, and soft.	Gland normal; numerous eosins.	Tetanus neonatorum.
29	6	—	Well-nourished girl.	14·070	Large, red, and firm.	Gland invaded with adipose tissue; some increase of fibrous tissue; some of Hassall's bodies calcified.	Acute rheumatism.
30	7	—	Well nourished.	10·	Large, red, and firm.	Many of the Hassall bodies were calcified; gland otherwise normal.	Appendicitis; acute general peritonitis.
31	$\frac{5}{52}$	—	Well-nourished child.	4·350	Red and soft.	Numerous eosins; gland otherwise normal.	Extreme pallor of all organs; œdema of brain (acute diarrhœa).
32	11	—	Well-developed girl, and well nourished.	8·770	Large and firm.	Gland normal.	Acute rheumatic fever; adherent pericardium; chronic mitral disease.
33	14	—	Ditto.	7·420	Large, red, and firm.	Gland normal.	Acute pericarditis; malignant endocarditis; acute pleuritis; chronic endocarditis.

Graves's Disease.

I obtained a specimen of an enlarged thymus from a case of Graves's disease, through the kindness of Dr. Seligmann.

The gland appeared to be almost normal. Connective-tissue corpuscles and endothelial cells were, however, more numerous in places throughout the gland tissue than we meet with under normal conditions. Some of the Hassall corpuscles showed well-marked calcification, while others stained in a homogeneous manner with acid dyes. I did not observe anything like the numbers of eosinophils such as are present in the enlarged thymus glands in children. The alteration in the structure of Hassall's corpuscles which was observed in this case appears to be of very little importance.

Hector Mackenzie and Walter Edmunds examined two enlarged thymus glands obtained from cases of Graves's disease. They did not consider that the structure of the gland differed in many respects from the normal, but that the concentric corpuscles did not appear to undergo degeneration so readily as in the thymus glands of healthy people.

The relation which the thymus gland bears to Graves's disease has been under discussion for some few years. Sir Astley Cooper refers to a most interesting case in his monograph on the thymus.

A young girl had suffered from severe dyspnœa for a short period, for which he could give no relief. There had been a "swelling" in the neck for some years, but it had increased considerably of late. Deglutition was also affected to some extent.

At the autopsy he found a large thyroid and a very large thymus. It seems to me that this case may have been one of Graves's disease, and if so, it would be the first recorded case in which enlargement of the thymus was observed.

Cases of "sudden death" and "found dead."

"Lymphatism."

I have been able to collect sixteen cases. All occurred in children under two years of age, except one case which occurred in a man aged 19, who died from tetanus.

The thymus gland.—The average weight of the thymus gland in my cases was found to be 25 grammes, 11 milligrammes. The largest gland weighed 47 grammes, 50 milligrammes, and the smallest gland 7 grammes, 770 milligrammes.

FIG. 29.

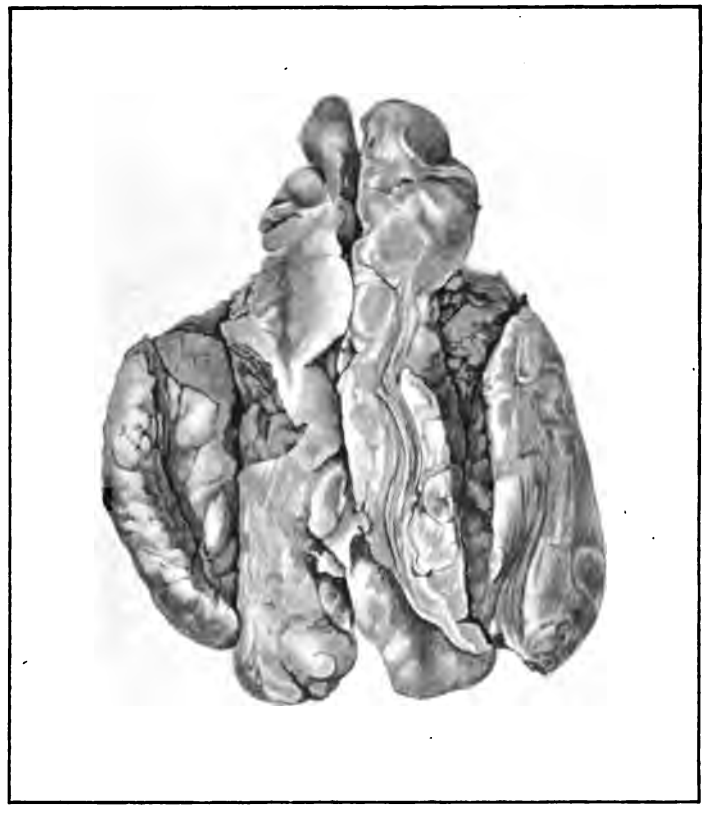

Enlarged thymus from a case of sudden death in an infant. Weight, 34 grammes. (Nat. size.)

EXPLICATIO FIGURÆ.

Glandula thymus peraucta infantis qui subito interierat. 34 g. pondere. (Magnitudinis naturalis.)

Hæmorrhages were seen on the surface of the gland in only one case.

Thick fluid which resembled "pus" to the naked eye, but which consisted almost entirely of lymphocytes, was present

in the interior of the gland in every case. I have already fully dealt with the characters of this fluid.

A bacteriological examination of the fluid was made in eight cases, but in seven cases it was found to be sterile, and in

FIG. 30.

Enlarged thymus from a case of sudden death in an infant. Weight, 46 grms. 500 m.grms. (Nat. size.)

EXPLICATIO FIGURÆ.

Glandula thymus peraucta infantis qui subito interierat. 46 g. 500 mg. pondere. (Magnitudinis naturalis.)

one case I found the pneumococcus. This case has been already dealt with under the bacteriological section.

Microscopical histology.—The structure of the thymus gland

in these cases was found to be normal, except for one point which is of considerable interest. Eosinophils have been described in the thymus, but only the variety which occurs in the blood, and also in very small numbers. I have found in the large or enlarged thymus glands, very large numbers of eosinophils which are of four varieties.

1. Large cells, with a single darkly-stained, granular and round or oval nucleus, which is generally situated at the periphery of the cell. Large numbers of coarse eosinophilic granules are arranged in an irregular manner around the nucleus.
2. Similar cells, but with a pale-stained non-granular nucleus.
3. Cells with a transitional nucleus.
4. Lastly, the true polymorphonuclear eosinophils of the blood.

These cells are found scattered throughout the gland tissue, occasionally in clumps, where they form 20, 30, 40, or even 50 per cent. of the cells. We find large numbers along the septa and in the connective tissue, and it is undoubtedly in such situations that these cells are most common. The first and second variety of eosinophil are about equally common, and form at least 95 per cent. of the coarsely granular oxyphil cells in the thymus. The polymorphonuclear cells are rarely met with. I found in the thymus of a young rabbit large numbers of the transitional type, which are so common in the bone-marrow. The eosinophil cell of the thymus differs from the eosinophil of the blood in two ways: (1) the nucleus, as already stated, is nearly always single, and is generally situated at the periphery of the cell; (2) the granules are generally smaller than those in the true eosin of the blood.

In some specimens of thymus glands large numbers of eosinophils may be seen in the interior of the small blood-vessels which are to be found in most microscopical sections, and differential counts have shown that the eosinophils may form 10 per cent. of the cells present. In these situations, however, the polymorphonuclear type of cell predominates, although a few of the tissue eosinophils are also present.

We must remember that although these cells are found chiefly along the septa and in the connective tissue, yet in the atrophic glands, in which the connective tissue is generally in considerable excess, the eosins are usually few in number, and

often absent. It is also interesting to observe that the "tissue eosinophils" and the polymorphonuclear eosins may both be present in the interior of the small blood-vessels. I cannot give at the present time any exact information as regards the relationship which exists between tissue eosins and blood eosins, if any.

An examination of the blood in cases of enlarged thymus, etc., has rarely been attempted, simply because of the extreme

FIG. 31.

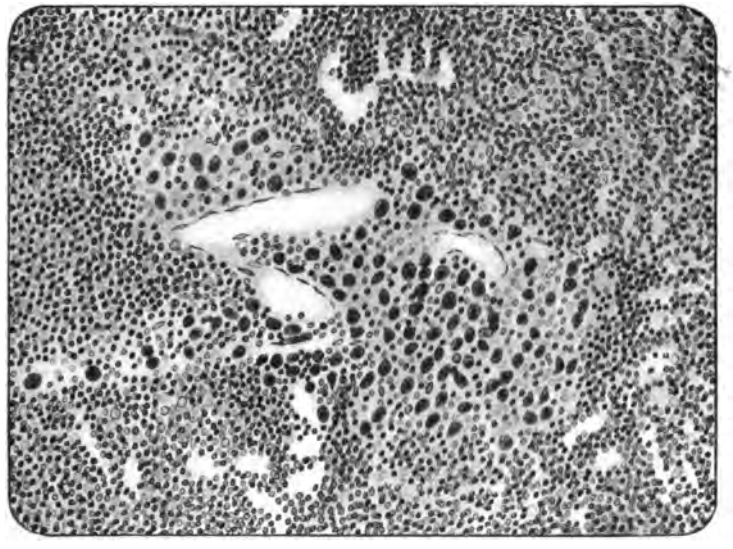

Section of enlarged thymus from an infant, showing a large number of eosinophil cells in the tissue. × 450.

EXPLICATIO FIGURÆ.

Glandulæ thymi perauctæ sectio microscopica, ex infante. In telâ lymphoideâ monstrantur permultæ cellulæ eosinophilæ. × 450.

difficulty in making the diagnosis. A case was recorded by James Ewing, of a child aged five years, who died quite suddenly under chloroform. An examination of the blood before death gave the following result:—76 per cent. lymphocytes out of a count of 500 cells, and only 2 *per cent. of eosins.* I have examined the blood in one or two "suspected cases," but

have not found any eosinophilia.[1] In rickets, which is so often accompanied by enlargement of the thymus, eosinophilia has been described by Hock (20 per cent.) and Weiss (16 per cent.). Morse found in his cases that the average number of eosins was 3 per cent., and the highest count was 7 per cent. We should expect to find that an increase of the eosins in the blood of children, as compared with adults, is physiological, *i.e.* if the eosinophil cells found in a normal thymus are in any way related to the eosinophil cells in the blood. Cabot states, "In infancy the percentage

FIG. 32.

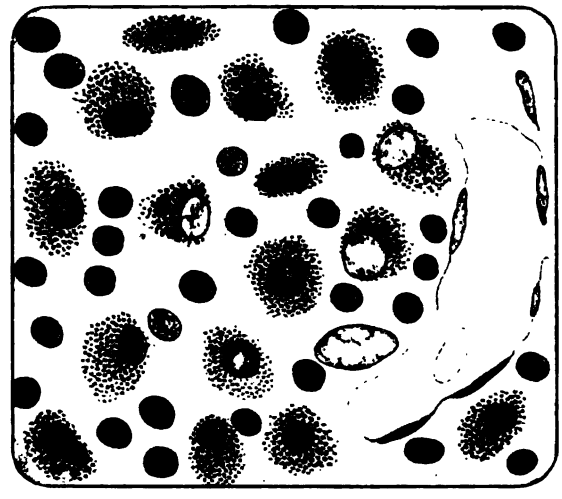

The preceding section of an enlarged thymus, showing the eosinophil cells in the tissue. $\frac{1}{12}$ oil immersion.

EXPLICATIO FIGURÆ.

Sectionis præcedentis pars maxime amplificata ($\frac{1}{12}$). Montrantur cellulæ eosinophilæ in telâ lymphoideâ.

of eosinophiles is very often higher than in adults, so that in them eosinophilia may be considered physiological." Ewing appears to arrive at a similar conclusion, viz.: "In children a

[1] Eugene Opie has drawn attention to some interesting points in connection with the life history of the eosinophil cell. He mentions that these cells are found in most glands in the body, but does not include the thymus, and also states that the eosins are most numerous along the course of the blood-vessels in the serous membranes. He makes the most unfortunate observation, however, that the large mononuclear eosinophil only occurs in the bone marrow.

relatively high proportion of eosinophil cells is the rule, and the variation in numbers is slightly greater. The average appears to be about 1·2 per cent. greater than in adults." If all these statements could be accepted without discussion we might be able to trace some connection between the thymus gland and the eosins in the blood, but unfortunately this is not possible. Firstly, we must always remember the frequency with which children suffer from the various forms of parasites; and even the common thread-worm may produce an eosinophilia of 7 or even 10 per cent., while the other varieties of parasites generally produce a much greater increase in this type of leucocyte. Secondly, we frequently find stated that the eosins amounted in a certain case to, *e.g.* 10 per cent. If, however, we study the literature more carefully, we shall find that only 100 leucocytes have been counted. There is not the least doubt that we cannot obtain reliable information unless we make a differential count of 500 leucocytes. I have frequently found that the eosins amounted to 8 per cent. in the first hundred, while if 500 cells were counted, they only reached about 2 per cent. This observation, of course, applies to all varieties of leucocytes, but more especially those which are normally few in number, viz. mast cells and eosinophils. It is also most important to know the total number of leucocytes in the blood. If we follow on these lines, we shall find that much of the literature is quite valueless. Lastly, I have not found that an eosinophilia is so common in children as Cabot and Ewing have claimed. I therefore think that although the thymus gland may be one of the seats of origin of the eosinophil cells, there is not sufficient evidence for this statement to stand without any fear of contradiction.

I have never seen any eosinophils in the thymus glands of old people, or in old animals. It is in the active glands of healthy children or in the enlarged glands associated with "sudden death" that we find such enormous numbers. An exactly similar result was obtained from an examination of the thymus glands of young animals. I do not consider that these cells are connective-tissue cells with eosinophilic granules, but on the other hand I am unable to bring forward any evidence, as yet, as to their true origin.

Results of the autopsies on my cases.—I have already referred to the thymus gland, as found at the autopsies on cases of

"sudden death," "lymphatism," and "found dead." Hypertrophy of the lymphoid tissue throughout the body was present in seven cases. This especially refers to the tonsils, adenoid tissue of the pharynx, and lymphatic glands (especially mesenteric, pharyngeal, and thoracic). I never found enlargement of the papillæ of the back of the tongue to any appreciable extent. The thyroid gland was enlarged in only one case. The solitary follicles of the intestine and Peyer's patches were distinctly enlarged in four cases. We must be very careful before we place much weight on this observation, as the lymphoid tissue in these situations in children is usually very prominent. In the recorded cases, however, definite enlargement was very obvious. Rickets was definitely present in eight cases. Of the remaining cases, death occurred from tetanus in a boy aged 19, so that here rickets may be excluded, and it was stated in the last seven cases that there was no evidence of rickets. In three of these cases the children were rather young for rickets. It is quite certain that rickets is very often accompanied by enlargement of the thymus and by hypertrophy of the lymphoid tissue generally, especially the pharyngeal. Jackson Clarke is reported to have said that: "Hyperplasia of the adenoid tissue in the naso-pharynx and throughout the body was as characteristic of rickets as the hyperplasia of the epiphyses." Some observers consider that the rickets is secondary to the lymphatic hyperplasia in certain cases. I never noticed hypoplasia of the heart and aorta as described by some observers. The spleen was moderately enlarged in seven cases. Hæmorrhages on the serous membranes was fairly common in my cases. I never noticed subcutaneous hæmorrhages. The blood in the right heart was sometimes fluid, at other times clotted, but never over-distended with blood. I always failed to find, although a careful search was made for, any thrombosis of veins or arteries in any part of the body.

A lymphoid condition of the bone-marrow has been recorded in a few cases (Osler).

A summary of the common changes found in these cases is as follows:—Enlargement of the thymus gland, hypertrophy of the adenoid tissue of the pharynx, enlargement of the lymphatic glands throughout the body but especially the pharyngeal, thoracic and mesenteric glands, hypertrophy of

the solitary follicles and Peyer's patches of the intestine, enlargement of the spleen, and lastly and very commonly rickets.

Causes of enlargement of the thymus gland.—1, Lymphatism; 2, rickets; 3, exophthalmic goitre; 4, myxœdema and cretinism; 5, acromegaly; 6, lymphatic leukæmia; 7, lymphadenoma; 8, myasthenia gravis; 9, Addison's disease; 10, scurvy; 11, epilepsy; 12, anæmia; 13, anencephalic fœtuses; 14, new growths;[1] 15, lastly but not least, enlargement from unknown causes.

What relation does the thymus gland bear to "sudden death," "lymphatism," and "found dead?"

The knowledge which we possess of this subject is almost entirely due to the energy of a few writers, more especially Grawitz, Friedleben, Paltauf, Ewing, Jacobi, and Osler.

Etiology of "sudden death."—1. *Suffocation from pressure exerted by enlargement of the thymus.*—The great supporter of this theory is Prof. Jacobi. He considers that as the space between the manubrium sterni and the vertebral column is little more than 2 cm. across in young children, and as this space is occupied by the œsophagus, trachea, blood-vessels, nerves, connective tissue, etc.; that with enlargement of the thymus, if "congestion" should occur for a few seconds, the space is so narrowed that suffocation takes place. Jacobi also considers that pressure on the recurrent laryngeal and other nerves may have important bearing on the cause of death in these causes.

2. Death is due to intra-vascular clotting. It is thought that some substance is secreted by the thymus which produces the above condition.

3. A specific micro-organism.

4. Adenoids.

5. Toxæmia.

6. Reflex.

The views of Prof. Jacobi have produced more discussion than perhaps any other question in relation to the thymus gland. There are both strong supporters and opponents of his theory.

[1] Dr. T. D. Savill makes a most unfortunate error in reference to this question. He says: "Enlargement of the thymus. A certain degree of enlargement is normal to childhood, and this may give rise to dulness over the manubrium. In the rare cases, enlargement is met with in after life; it is generally due to carcinoma, and it may be a primary deposit."

Prof. Brouardel considers that the thymus gland does compress the trachea, and that this compression gives rise to a slight degree of spasm, which rapidly causes the child's death. He also refers to a most important point, viz., that as the trachea and bronchi are very elastic in children, they are able to resume their normal states directly the sternum is removed. We cannot, therefore, draw accurate deductions at the autopsy as to whether the trachea has been compressed or otherwise. Grawitz, however, who called the attention of the profession to the relation of the thymus gland to sudden death in 1888, considered that death was not due to compression of the trachea and bronchi because the calibre of the air passages was not reduced in size in any of the autopsies on his cases.

Siegel, quoted by Prof. Osler, mentions the following case:—A boy, aged 2½ years, had had for two and a half weeks cough and dyspnœa, the latter of which was worse at night. Tracheotomy was performed without relief, but at a subsequent operation the anterior mediastinum was opened from above. A piece of the thymus gland appeared at the site of the operation, and therefore the gland was stitched to the fascia over the sternum. The child made a complete recovery. Koenig, also quoted by Osler, removed a portion of the thymus gland with a similar result. Caillé reported a case of sudden death in a child aged 6 months, due, in his opinion, to compression of the large blood-vessels by an enlarged thymus. Putnam referred to a similar case in a child under his care. The thymus gland at the autopsy was found to weigh six ounces. All these observers and many others agree in the main with Prof. Jacobi.[1] Some physicians consider that weakness of the head and neck muscles is a possible factor as a cause of death in cases of enlarged thymus. Trousseau, on the other hand, one of the most able physicians who ever lived, considered that death in these cases was due to spasm of the glottis. Paltauf believed that capillary bronchitis was the cause of death in many of these cases. He considered that this disease was often difficult to diagnose in young infants unless the smaller bronchi were carefully slit up with fine scissors, and that, therefore, many deaths which were incorrectly

[1] Dr. Frederick Taylor has recorded a case of lymphatic leukæmia associated with enormous enlargement of the thymus, but unaccompanied by any dyspnœa. The gland was found to weigh 586 grammes.

ascribed to the thymus were really due to broncho-pneumonia. Thursfield, in the paper quoted above, describes in detail four cases of sudden death which he collected at the Great Ormond Street Hospital. He favours the view that death is due to a "toxæmia," chiefly from the fact that one of his cases developed hyperpyrexia before death. Blumer, in the 'Johns Hopkins Reports,' as a result of an analysis of nine cases, has elaborated a similar theory. There are some who hold that vascular thrombosis is the cause of death in most of these cases. Mr. W. G. Spencer gives his support to both this theory and to the pressure theory. He contends that because there is no evidence of pressure on the trachea in the *post-mortem* room, we must not say, therefore, that such a condition did not exist during life! There is not, however, to my mind the slightest evidence in favour of the view of intra-vascular clotting. I only obtained negative evidence from *post-mortem* observations on my own cases of enlarged thymus. Thursfield and many others have arrived at a similar conclusion.

Thymic asthma, or Millar's asthma, or Laryngismus stridulus.

Thymic asthma has been described as a very severe dyspnœa which occurs in infants and very young children, and is due to an enlargement of the thymus gland which obstructs respiration by pressure on the trachea.

Many German physicians considered that the Laryngismus stridulus of English writers was really thymic, or Millar's asthma.

I will briefly refer to the opinions which have been expressed by the most eminent physicians in Europe and America as to whether such a disease as thymic asthma really does exist.

Prof. Strümpell writes as follows: "The old name of thymic asthma arose from the idea that the attacks were due to an increase in the size of the thymus gland, but this opinion is wholly unfounded."

Prof. Henoch, if possible, is still more emphatic on this question, viz.: "Anything else that has been written on the ætiology of laryngeal spasm is either hypothetical or positively incorrect, particularly the view that the disease arises from enlargement

of the thymus gland (Asthma thymicum), which view still has its supporters."

Prof. Osler has written by far the most exact summary on this important subject. I will refer to a few of the chief points to which he has drawn attention. "There can be, I think, no question that the ordinary laryngismus seen in rickety children is a convulsive affection, and is *not* the result *of compression*." "But a very greatly enlarged thymus may seriously hamper the structures within the thorax." He then refers to Siegel's and Koenig's cases, to which I have already referred.

Friedleben, whose name is so closely associated with the thymus gland, was the first to strongly oppose the view that the enlargement of the thymus gland was the cause of such dyspnœa. Prof. Osler completes his account of thymic asthma, after referring to Siegel's and Koenig's cases, as follows: "These are cases that go far to disprove Friedleben's dictum, *Es giebt kein asthma thymicum*."

Herard published a standard monograph on spasms of the glottis in 1847. He considered that the thymus gland bore no relation to sudden death.

There is no doubt that those German physicians who considered that thymic asthma and Laryngismus stridulus were synonymous terms were incorrect; but if we give our full attention to the subject we shall observe that both "symptoms" are very commonly associated with one common group of pathological phenomena, generally known as the lymphatic constitution.

One of my cases (No. 1, Table VII) died quite suddenly. The child, aged sixteen months, was seen sitting up in bed playing with her toys; about two minutes afterwards she was found to be dead. Many suggestions were made at the time for the cause of death, such as Laryngismus stridulus, enlarged thymus, etc.

I found at the autopsy, marked *rickets* and *hypertrophy of the lymphoid tissue throughout the body*. There was no evidence of intra-vascular clotting, and no distension of the right side of the heart with blood. The thymus gland was found to be absolutely normal. I doubt if any physician could accurately ascribe a cause for death in this case. Enlarged thymus is frequently found in such cases, although in the case in question the gland was normal. The relation which Laryn-

gismus stridulus bears to rickets has long been recognised. John Thomson writes: "Laryngismus occasionally occurs . . . . but in the great majority of cases it is met with in rickety children . . ."

Lymphatism.

The attention of the profession has been drawn to this important disease greatly owing to the work of Paltauf.

It occurs chiefly in children and young adults. It has been found that subjects of this affection die quite suddenly, or during the administration of an anæsthetic, slight operation, or while bathing. The sad death of Prof. Langerhans' son, as soon as his father had given him a preventative dose of anti-diphtheritic serum, was considered to be due to lymphatism. Prof. Osler relates one case of death under anæsthesia for adenoids. Some physicians consider that deaths during convalescence from infectious fevers are due to this condition.

Sometimes children are noticed to be unwell for a short time before "sudden death" occurs. They have either refused food or will not play with other children, or have suffered from slight sickness or diarrhœa.

Occasionally these children have had one or more convulsions before death. In four of my cases, convulsions are known to have occurred. In one case there was one convulsion, in two cases convulsions lasted for some few minutes, in the fourth case the child had one fit after another for a few hours, and was quite unconscious between each fit, till the fatal termination occurred.

The great objection to the diagnosis of lymphatism is chiefly owing to the fact that it has been made a "refuge for the destitute." There are some people who, as one observer remarks, "know more about lymphatism than they do about consolidation of the lungs." In fact, the lymphatic constitution is found to be almost a matter of every-day experience, somewhat similar to the so-called thymic abscess; but even in face of these facts there is no doubt that lymphatism is a most important disease.

We now come to the large group of cases known as "found dead." There is no doubt that many of these cases are examples of over-laying. Mr. Wynn Westcott and other coroners have done much to prove that this view is correct. On the other hand,

most of the children in my cases were found to have well-marked enlargement of the thymus. One of the most perfect examples of lymphatism recorded was No. 9 (Table VII) of my series.

I strongly oppose the view that all cases of "found dead" in infants are examples of lymphatism, but I must say I think that some of these cases are undoubtedly due to this affection. There is no need to discuss this question any further, as no one but the mothers of these babies can supply the true facts required, and they generally prefer not to do so.

[1] *Graves's disease and lymphatism.*

Sudden death is known to occur in Graves's disease. Hale White has recorded two examples of this calamity. At a discussion, at the Clinical Society of London, on 120 cases of Graves's disease brought forward by Prof. Murray, Dr. Hale White stated that he had found enlargement of Peyer's patches and of the lymphoid follicles of the intestine in certain cases of exophthalmic goitre.

In Dr. Seligmann's case, from which I obtained the thymus gland, it was proved at the autopsy that there was enlargement of the spleen, lymphatic glands throughout the body, lymphoid follicles and Peyer's patches of the intestine, thymus, and thyroid glands.

The patient was killed in a street accident.

We might therefore describe this case as an example of lymphatism occurring in Graves's disease in an adult man. Sections of the spleen which were examined in this case showed prominent Malpighian bodies, many of which had undergone hyaline degeneration. It appears, therefore, that certain cases of Graves's disease have the same pathological phenomena as are known to occur in lymphatism.

Conversely, it has long been known that in some cases of lymphatism enlargement of the thyroid has been found.

It will remain for pathologists in the future to trace the connection between all these various links, and to establish the condition known as "sudden death" on a pathological basis, instead of the hypothetical basis on which it now rests.

[1] The relation of the thymus gland to Graves's disease has already been referred to.

TABLE VII.—"*Sudden Death.*" "*Found Dead.*"

No.	Age.	Average weight of body.	Weight of body.	Weight of thymus gland.	Condition of thymus gland at autopsy.	Microscopical examination of thymus gland.	Result of autopsy.	Cause of death, etc.
		lbs.	lbs.	grms.				
1	$1\frac{4}{12}$	20	$15\frac{1}{2}$	7·770	Large, red, and firm.	Normal gland.	Rickets. Hypertrophy of the lymphoid tissue throughout the body.	Child died suddenly while in bed playingwith her toys.
2	$1\frac{5}{12}$	22	$14\frac{1}{2}$	22·106	Large, red, and firm, except the right lobe which contained a large abscess cavity, in which was thick reddish brown fluid,from which was obtained a pure culture of the pneumococcus. (*See* text for particulars.)	Gland appears to be normal.	Rickets. Over distended stomach. (Contained large quantity of potato skins.) Hypertrophy of the lymphatic tissue throughout the body.	Child taken ill quite suddenly with a sort of convulsion and fell back dead.
3	$\frac{3}{12}$	11	$9\frac{5}{16}$	28·060	Large, red, and firm.	Gland normal. Large numbers of eosins.	—	Found dead in bed.
4	$\frac{8}{12}$	18	$13\frac{1}{2}$	29·030	Large, red, and firm. Cultures from cavity in thymus gland were sterile.	Gland normal. Numerous eosinophils.	—	Found dead in bed.
5	$\frac{6}{12}$	16	$13\frac{1}{2}$	18·037	Large, red, and firm.	Normal gland. Enormous numbers of eosinophils.	Rickets. General lymphatic hypertrophy.	Death in convulsions.
6	1 yr.	20	$14\frac{1}{2}$	34·000	Large, red, and firm. Cultures from glands were sterile.	Normal gland. Numerous eosins.	Rickets. General lymphatic hypertrophy.	Sudden death.
7	$\frac{10}{12}$	$18\frac{1}{2}$	17	22·050	Large, red, and firm.	Gland normal. Numerous eosins.	—	Found dead in bed.
8	$\frac{9}{12}$	18	$14\frac{7}{16}$	31·050	Large, red, and firm. Cultures from gland sterile.	Large numbers of hæmorrhages, otherwise normal gland. Eosins plentiful.	—	Found dead in bed.

TABLE VII—*continued.*

No.	Age.	Average weight of body.	Weight of body.	Weight of thymus gland.	Condition of thymus gland at autopsy.	Microscopical examination of thymus gland.	Result of autopsy.	Cause of death, etc.
		lbs.	lbs.	grms.				
9	$\frac{5}{12}$	15	$10\frac{3}{16}$	47·050	Large, red, and firm.	Gland normal. Numerous eosins.	Rickets. General glandular hypertrophy. Enlargement of spleen and thyroid, etc. Some blood-clot in right side of heart, but not over-distended. No intra-vascular clot discovered. Hæmorrhages on both pleuræ.	Found dead in bed.
10	19 yrs.	Full-sized man; body well nourished.	—	17·250	Large, red, and firm.	Caclification of Hassall's corpuscles. Gland otherwise normal. No eosins seen.	None.	Death from tetanus.
11	$\frac{11}{12}$	12	$9\frac{7}{16}$	46·500	Large, red, and firm.	Gland normal. Large numbers of eosins.	None.	Sudden death.
12	$1\frac{1}{2}$	22	$12\frac{1}{2}$	10·820	Large, red, and firm.	Gland normal. Numerous eosins.	Rickets. Acute bronchitis. General enlargement of the lymphatic glands. Enlarged spleen. Enlargement of the solitary follicles of the intestine and Peyer's patches. Tonsillar hypertrophy.	—
13	$\frac{5}{12}$	Well nourished	—	35·070	Large, red, and firm. No hæmorrhages seen on surface of gland.	Normal gland. Numerous eosinophil cells.	Rickets. Enlarged mesenteric glands. Peyer's patches and solitary follicles of intestine enlarged. Enlargement of the spleen. General lymphatic enlargement. Thyroid not enlarged.	No cause for death. Sudden onset of convulsions terminated fatally in a few hours.

TABLE VII—*continued.*

No.	Age.	Average weight of body.	Weight of body.	Weight of thymus gland.	Condition of thymus gland at autopsy.	Microscopical examination of thymus gland.	Result of autopsy.	Cause of death, etc.
		lbs.	lbs.	grms.				
14	$\frac{5}{12}$	15	$12\frac{3}{4}$	20·400	Large, red, and firm. A culture from fluid in interior of gland was found to be sterile.	Normal gland. Numerous eosins.	Rickets.	Convulsion; death occurred in a few minutes.
15	$\frac{9}{12}$	18	$15\frac{7}{16}$	20·	Large, red, and firm. Cultures sterile.	Normal gland. Eosinophil cells numerous.	None.	Found dead in bed.
16	$\frac{4}{12}$	14	$9\frac{7}{16}$	11·	Large, red, and firm. Cultures sterile.	Normal gland. Large numbers of eosins.	None.	Found dead in bed.

TABLE VIII.

Showing average weights of the thymus gland obtained from various sources.

	Source.	No. of cases.	Average weight of gland.
1	Primary atrophy.	15	2·680 grms.
2	Secondary atrophy (tubercular).	26	3·065 „
3	Secondary atrophy (non-tubercular).	12	2·605 „
4	Acute diseases.	32	5·440 „
5	Fœtal specimens.	10	*6·53 „ (1) or 4·575 „ (2)
6	"Sudden death." "Found dead."	16	25·011 „

* This result is probably incorrect, as I have included the large thymus of the anencephalic fœtus. The second average is therefore more likely to be correct.

In conclusion, I wish to offer my best thanks to Mr. Shattock for the great interest which he has taken in this monograph and for much valuable help.

To the Staff of the East London Hospital for Children, with whom I was closely associated as pathologist, I have to express my gratitude for the full use of pathological material.

To Dr. Coutts, Physician to the Shadwell Hospital, for many valuable suggestions and for the great interest which he has always taken in this work.

Lastly to Dr. Rose, to whom I am indebted for some of the most valuable pathological material derived from the East End of London.

REFERENCES.

Acland, T. D.—'Transactions of the Pathological Society of London,' vol. xxxvi, 1884-85, pp. 491—494.

Blumer, George.—'Johns Hopkins Hospital Bulletin,' vol. xiv, No. 151.

Böhn, Davidoff, Haber.—'Text-book of Histology,' 1900, p. 188.

Branson, W. S. and Dudgeon, L. S.—"Pneumococcic Arthritis," 'Lancet,' August 1st, 1903.

Brouardel.—'Death and Sudden Death,' 1902.

Bruce, Alexander.—'Transactions of the Pathological Society of London,' vol. xviii, 1866-67, p. 263.

Cabot.—'Clinical Examination of the Blood,' 1898.

Caillé, Augustus.—'Archives of Pediatrics,' March, 1903, p. 180.

Cooper, Sir Astley.—'Anatomy of the Thymus Gland,' 1832.

Coutts, J. A.—"Some Aspects of Infantile Syphilis," 'Hunterian Lectures,' 1896, pp. 81—84.

Cunningham, D. J.—'Text-book of Anatomy,' 1902, p. 1156.

Demme.—"Isoliste primäre Tuberculose de Thymus," 'Futschritte der Medecin,' 1886.

Dubois, Paul.—'Gazette Médicale de Paris,' 1850, p. 392.

Ernst, P.—"Ueber Hyalin," 'Virchow's Archiv,' 1892, vol. cxxx, p. 377.

Ewing, James.—'Clinical Pathology of the Blood,' 1901.

Ewing, James.—'New York Medical Journal,' July 10th, 1897.

Fowler, J. S.—"Thymus Gland," 'Encyclopædia Medica,' pp. 243—249.

Friedleben.—'Die Physiologie der Thymusdrüse in Gesundheit und Krankheit u. s. w.,' Frankfurt-a-Main, 1858.

Hale White.—Discussion at Royal Medical and Chirurgical Society of London, 'Lancet,' December 13th, 1903.

Henoch.—"Lectures on Diseases of Children," New Sydenham Society's translation, 1889, vol. i, p. 108, and pp. 185—186.

Herard.—'Du Spasme de la Glotte,' Paris, 1847.

Hermann, G., and Tourneux, F.—'Dictionnaire des Sciences Médicales,' 1887, 3 série, pp. 415—443.

Hock, Schlesinger.—'Beiträge zur Kinderheilk.,' Wien, 1892.

Howden, Robert.—'Gray's Anatomy,' 1902, p. 967.

Jacobi.—"Contribution to the Anatomy and Pathology of the Thymus Gland," 'Transactions of the Association of American Physicians,' 1888, vol. iii, pp. 297—321.

EXPLANATION OF PLATE IV.

Illustrating Mr. L. S. Dudgeon's communication on "The Pathology of the Thymus Gland." (P. 151.)

FIG. 1.—An isolated area of thymus tissue lying in a mass of fat; in the lower part of the former tissue a Hassall corpuscle will be seen. From an old man. × 225.

FIG. 2.—Atrophied thymus gland from a case of general atrophy secondary to chronic disease, largely replaced by adipose tissue. × 225.

FIG. 3.—Atrophied thymus gland from a case of broncho-pneumonia. The dark areas represent hæmorrhagic foci. × 225.

FIG. 4.—Thymus gland from a case of simple marasmus. Numerous Hassall corpuscles are shown; some are of large size; the smaller (in the right half of the figure) have undergone hyaline degeneration. × 450.

FIG. 5.—A thymus gland in the lymphoid tissue of which an endothelial formation of cells has occurred; the latter, in the photograph, appear as lighter areas pervading the proper tissue. × 25.

FIG. 6.—Normal thymus of a child aged two years. × 25.

(From micro-photographs.)

TABULA IV.

Ad dissertationem "De Glandulæ Thymi Morbis" illustrandam.

L. S. Dudgeon. (P. 151.)

FIGURA 1.—Glandula thymus senis. Monstratur telæ lymphoideæ area telâ adiposâ circumtecta; in parte inferiori illius corpusculum Hassall videtur. × 225.

FIGURA 2.—Glandulæ thymi sectio, apud exemplum atrophiæ generalis morbo chronico causatæ. Infiltratio adiposa inter telam lymphoideam monstratur. × 225.

FIGURA 3.—Glandulæ thymi sectio, apud exemplum bronchopneumoniæ. Areæ nigræ sanguinem effusum repræsentant. × 225.

FIGURA 4.—Glandulæ thymi sectio, apud exemplum marasmi simplicis. Corpuscula Hassall plura monstrantur, quorum minima degeneratione hyalinâ affecta sunt. × 450.

FIGURA 5.—Glandulæ thymi sectio; tela lymphoidea cum telâ cellulis endothelialibus formatâ miscetur. × 25.

FIGURA 6.—Glandula thymus normalis ex infante annorum 2. Glandula ex telâ lymphoideâ passim constat. × 25.



Fig. 1



Fig. 2

Fig. 3.

Fig. 5.



Fig. 6

[illegible]ATE IV.

[illegible]mmunication on "The [illegible]d." (P. 151.)

[illegible] in a mass of fat, in the [illegible] will be seen. From an old [illegible]

[illegible] of general atrophy secondary [illegible] tissue. × 225

[illegible] a case of bronchopneumonia. The [illegible]

[illegible] marasmus. Numerous Hassall [illegible] the smaller (in the right half [illegible] [illegible]ation. × 450.

[illegible] tissue of which an end th[illegible] [illegible], in the photograph, appear a[illegible] [illegible] × 25.

[illegible] aged two years. × 25.

[illegible] [illegible]ro-photographs.)

TABULA IV.

[illegible] "De Glandulae Thymi Morbis" illustrandam.

[illegible] S. Dudgeon. (P. 151.)

[illegible] Monstratur telae lymphoideae area tela [illegible] in [illegible] illius corpusculum Hassall videtur.

[illegible] apud exemplum atrophiae generalis [illegible] inter telam lymphoideam monstratur. × 2[illegible].

FIGURA 3.—Glandulae thymi sectio, apud exemplum bronchopneumoniae. Areae nigrae [illegible] effusum [illegible] × 225.

FIGURA 4. Glandula thymi sectio, apud exemplum marasmi simplicis. Corpuscula Hassall plura monstrantur, quorum minima degeneratione hyalinâ affecta sunt. × 450.

FIGURA 5. Glandulae thymi sectio. Tela lymphoidea cum telâ cellulis [illegible] formata miscetur.

FIGURA 6. Glandula thymus [illegible] ex infante annorum 2. Glandula [illegible] lymphoideae [illegible] constat. × 25.

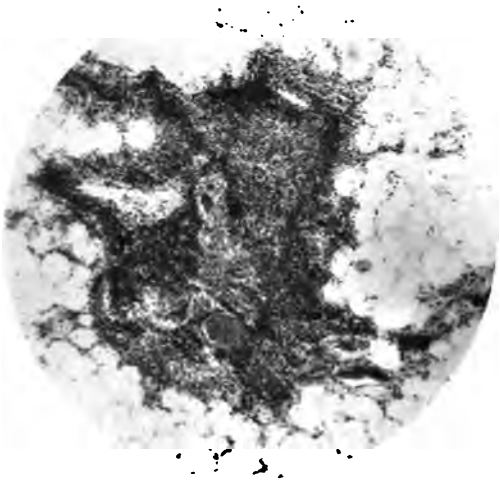

Fig. 1.

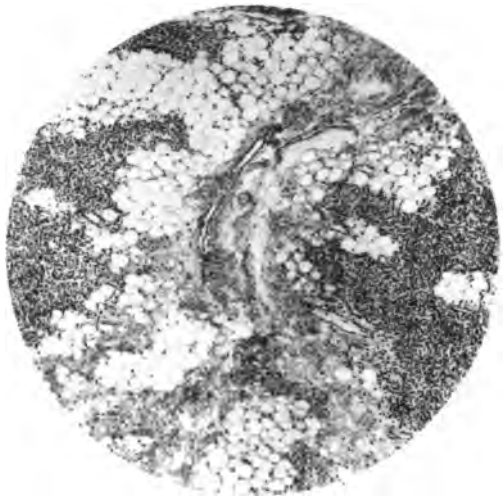

Fig. 2.

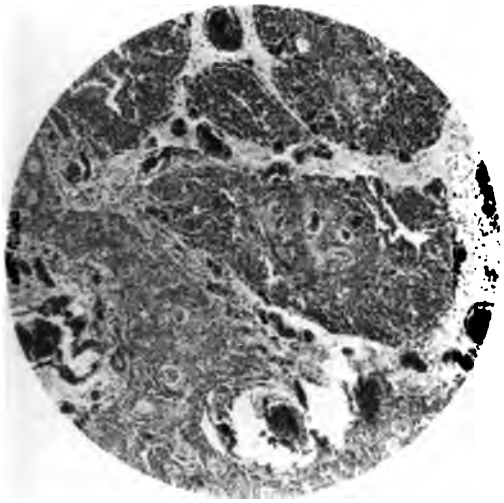

Fig. 3.

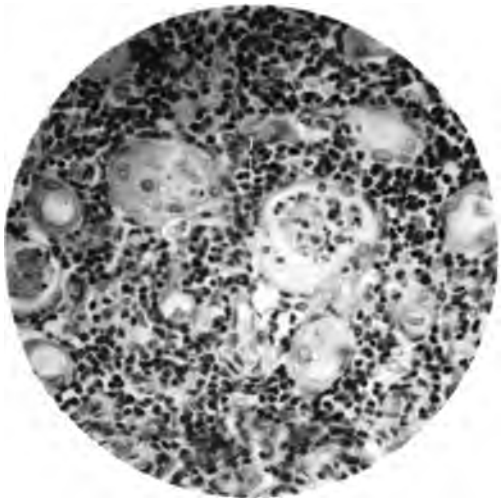

Fig. 4



Fig. 5.



Fig. 6.

Mackenzie and Edmunds.—'Transactions of the Pathological Society of London,' vol. xlviii, 1897.
Mallory and Wright.—'Pathological Technique,' 1901.
Mettenheimer.—"Zum Verhalten der Thymus drüse in Gesundheit. und Krankheit.," 'Jahrbuch für Kinderheilkunde,' 1897, Bd. xlvi, S. 55.
Morse.—'Boston Medical and Surgical Journal,' vol. cxxxvi, p. 369.
Osler.—'The Principles and Practice of Medicine,' 1902, pp. 843—844; pp. 826—827.
Parrot, J.—'La syphilis héréditaire et le Rachitis,' 1886.
Roberts, F. J.—'Allbutt's System of Medicine,' vol. iv, p. 89.
Robinson, Arthur.—"The Thymus Gland," 'Morris's Anatomy,' 1901.
Rolleston, H. D.—'The Diseases and Primary Tumours of the Thymus Gland,' p. 13. Medical Publishing Co., Ltd.
Ruhräh, John, with Stokes, W. R., and Rohrer, C. W. G.—"Relation of Thymus Gland to Marasmus," 'American Journal of Medical Science,' November, 1902, pp. 847—864.
Sanné.—'Dictionnaire des Sciences Médicales,' 3 séries, xvii, 1887.
Savill, T. D.—'System of Clinical Medicine,' 1903, vol. i, p. 123.
Schäfer, E. A.—'Essentials of Histology,' 1902, p. 31.
Shattock, S. G.—Discussion at Pathological Society of London: The Thymus Gland, 'British Medical Journal,' December 12th, 1903.
Simon, Sir John.—'A Physiological Essay on the Thymus Gland,' 1845.
Sollies, Paul.—'Twentieth Century,' vol. xii, p. 281.
Spencer, W. G.—Discussion at Pathological Society of London: The Thymus Gland, 'British Medical Journal,' December 12th, 1903.
Strümpell.—'Text-book of Medicine,' 1901, 3rd American edition, p. 153.
Taylor, Frederick.—Discussion on Lymphatic Leukæmia, Clinical Society of London, November 27th, 1903.
Testut.—'Quain's Anatomy,' 1896, vol. iii, p. 308.
Thomson, John.—'Clinical Examination and Treatment of Sick Children,' 1898, pp. 10 and 303.
Thursfield, Hugh.—'St. Bartholomew's Hospital Reports,' vol. xxxviii.
Vierordt.—'Text-book of Pathology,' Ludwig Hektoen, vol. ii, pp. 911—914.
Watney.—'Philosophical Transactions,' 1882, vol. clxxiii, part i, pp. 1064—1119.
Ziegler.—'Special Pathological Anatomy,' Sections IX—XV, English translation, p. 885.

December 1st, 1903.

---

20. *Cystic disease of the liver and kidney.*

By C. B. Blackburn.[1]

Some two years ago I was present at the *post-mortem* examination of a patient who was found to have extreme cystic disease of the liver and both kidneys. The fact that this was the third

[1] Thesis accepted for the degree of Doctor of Medicine, Sydney University.

occasion on which I had seen such a condition within eighteen months led me to make a careful microscopical examination of the organs, and to inquire into the literature of the condition. Since then I have had an opportunity of searching the records of the large hospitals of Brisbane, Sydney, Melbourne, and Adelaide, and I have at the same time made inquiries from medical men of long experience in the corresponding States. The result of my investigations has been the discovery of two further examples of the condition. One of them has been already briefly reported by Dr. Reid (1).

Of the literature on the subject much is unobtainable in Australia, or at least is not contained in the medical libraries in the States already referred to. I have, however, been able to get detailed accounts of a considerable number of cases, and these contain references to, and extracts from, those of the others that appear to have been considered likely to have any bearing on the pathology of the condition. All of these are merely reports upon cases, followed by a short reference to preceding accounts and a short discussion on the pathology.

It would appear that up to the year 1899 there had been thirty-six cases recorded—thirty-three in adults and three in very young infants. My cases—four in adults and one in an infant—will bring the total up to forty-one. Of the five, however, in but two (the infant and one adult) am I able to give an account of the minute appearances of both organs, while in one other case I was able to examine the liver microscopically.

Still I hope to show that the appearances shown in sections of the first case have a sufficient importance in regard to the whole question of the pathology of this curious disease to justify this article. Moreover, quite apart from the question of minute histology, the clinical histories and macroscopical appearances of the incomplete cases serve to show the urgent need, in Australia, at any rate, of a more general knowledge of the occasional occurrence of the lesions. But for the want of such knowledge, in two of the cases a surgical catastrophe would probably have been avoided, and a fatal termination considerably delayed.

Case 1.—I. P—, female, aged 42, admitted to Prince Alfred Hospital during 1900.

Sent to hospital as suffering from malignant disease of the liver. States that she was well till two months ago, except that she has had indigestion for several years. Illness began with pain over right hypochondrium, and jaundice; jaundice has steadily increased, and pain has continued moderately severe. Has lost weight during the last few months.

Previous history.—Good; no previous jaundice; special inquiries into urinary history not made; no potus; eight children, all alive and well.

On admission.—Looks exceedingly ill, emaciated, deeply jaundiced. Is somewhat drowsy and apathetic, lies persistently on her back; herpes round mouth; tongue dry and fissured. Temp. 103°·6. Pulse 152. Respiration 40.

Abdomen.—Full, somewhat tense, skin dry and scaly; superficial veins dilated and prominent; several petechiæ over right and left hypochondrium. Palpation was difficult owing to tenderness, but a large mass could be felt extending from the costal margin to near the level of the umbilicus, hard and irregular, with numerous soft swellings scattered over the surface. In both loins were large tumours extending well below the umbilicus, but their exact relations could not be made out owing to the tenderness.

Liver dulness extended from the level of the fourth rib to the lower margin of the mass felt in the abdomen.

Respiratory system. — No symptoms; nothing abnormal detected.

Circulatory system.—Cardiac dulness slightly increased outwards. A. B. in fifth space. Sounds, weak but clear. Vessels soft, not tortuous. Pulse small, low tension.

Nervous system.—Patient seemed drowsy and apathetic; reflexes present, but sluggish.

Cutaneous system.—Skin generally dry and scaly; a few scattered petechiæ over body. No œdema anywhere.

Genito-urinary.—No pelvic disorder. Passes a good deal of urine; has had no urinary trouble. Urine: Sp. gr. 1010, bile-stained; no albumen, no sugar.

Gastro-intestinal. — Anorexia, thirst, constipation; motions clay-coloured.

She gradually became weaker, the jaundice varying in intensity from day to day, and died one month after admission.

About ten days before her death rather severe diarrhœa set in and probably precipitated the fatal termination.

Autopsy.—On opening the abdomen a small amount of free fluid was found to be present. The kidneys presented as large tumours in the loins, and on examination the left and right were found to weigh respectively 24 and 17½ oz. They seemed entirely converted into cysts, which formed projections on the surface. The enlargement was uniform and the shape fairly well preserved. The cysts varied in size from a pea to a cherry, but a few were much larger, like mandarin oranges. Those that were incised were found to contain clear, viscid, semi-gelatinous fluid, containing much albumen and mucus. On incising the kidneys it was found that the whole substance was tough and permeated with cysts. A small portion was removed for microscopical examination, but they were preserved otherwise intact. There was no evidence of dilatation of the pelvis or ureters.

The liver weighed 84 oz., and was studded with cysts of various sizes, some as large as mandarin oranges. The contents were exactly similar to those in the kidneys. On section numerous small cysts were seen throughout the substance of the organ, which was leathery in consistence. The gall-bladder was shrunken, and contained gall-stones. Calculi were also present in the cystic and common ducts. The liver was also preserved as a museum specimen.

The spleen was large and firm, and showed signs of recent perisplenitis over the external surface. On the internal surface, about the hilum, were numerous small cysts about the size of millet seeds. They seemed superficial, and contained clear, watery fluid. This specimen was also set aside for keeping, but must have been returned to the body by mistake, as it afterwards could not be found.

The heart weighed 6½ oz.; the left ventricle was not hypertrophied, and the valves were healthy.

There was nothing of importance in the other organs, all of which were carefully examined for any evidence of malignant disease, with negative results.

Microscopical examination.—Portions of both kidneys and liver were selected where there was comparative absence of cysts, and several series of paraffin sections made and examined.

Liver.—On examining sections of the liver, the most striking feature was the enormous increase of connective tissue, which was abundant, not only in the portal spaces, but also between the lobules, and in places could be seen invading the lobules from the periphery, enclosing, and causing atrophy of the liver cells. In other parts large masses of the parencyhma were seen, completely cut off by fibrous tissue, and undergoing degeneration and absorption. Everywhere there was evidence of fatty de-

FIG. 33.

A group of dilated bile-ducts in transverse section; above them is an arteriole in longitudinal view. × 350.

generation of the secreting cells, and in some parts of the field this was very advanced. Sometimes, however, whole lobules could be seen much less affected, the cells being fairly healthy, with well-stained nuclei and only a few fat globules in their protoplasm. Nowhere was there any appearance of vacuolisation, either in or between the cells. Here and there, dark greenish spots of bile pigment were visible.

The hepatic veins and central venules were dilated and their walls thickened. In places the capillaries in the central zone of the lobules were somewhat distended with blood, and the surrounding liver cells appeared atrophic. In the larger portal

spaces the increase of fibrous tissue round the veins was often very marked, and the coats of the arteries greatly thickened.

The most interesting feature was the appearance presented by the bile-ducts. These were apparently more numerous than usual, and in places the section reminded one of biliary cirrhosis. Many seemed normal, except for some increase in surrounding fibrous tissue. Other ducts were dilated to a varying extent, and every gradation could be seen between simple dilated ducts

FIG. 34.

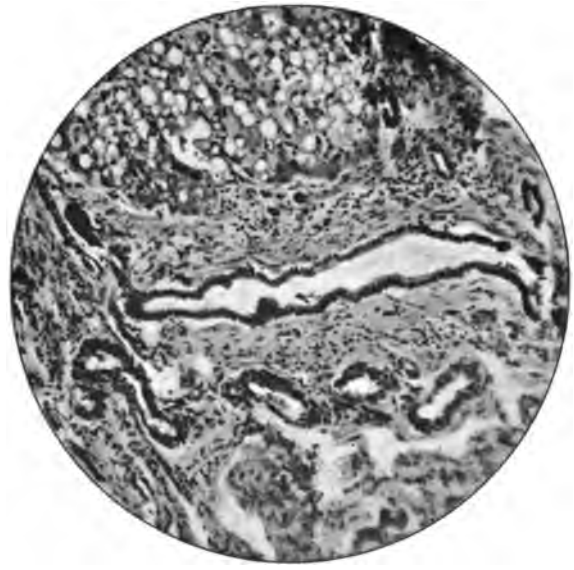

A dilated bile-duct, cut longitudinally. Above the left extremity is part of an undilated bile-duct. Marked fatty change in the hepatic cells. × 350.

and quite large cysts. Most dilated ducts and smaller cysts were lined by tall columnar epithelium, and many contained granular epithelial cells.

The individual cells had elongated, deeply staining neuclei at the base occupying about one third, and the remaining portion, projecting into the lumen, was clear and unstained. Many of the shed cells were swollen, had lost their nuclei and could be seen gradually losing their identity, and becoming a part of the granular or colloid material contained in the cysts. In some sections, where the bile-ducts were cut longitudinally, they were seen to be dilated throughout their whole visible length. Round

all these dilated bile-ducts there was obvious increase in the connective tissue. This was most evident in the large portal spaces, where it often formed dense fibrous rings. The tissue was fairly cellular, and often seemed more cellular round the ducts than round the vessels and other parts of the space. In several spaces one large ring of connective tissue enclosed several dilated ducts which showed evidence of fusion. In some parts of the field, where masses of liver cells could be seen cut off from the rest of the organ, and undergoing atrophic changes, apparently new bile-ducts could be seen appearing among the atrophic cells, and were in many instances dilated. In some parts it appeared as if cystic spaces were taking their origin from amongst these atrophic cells, as a distinct ring of cells, like small flat liver cells, could be seen surrounding a central space containing granular *débris*.

The cysts.—It was difficult to draw a distinction between a dilated bile-duct and a small cyst. In the case of larger cysts, the epithelial lining was either flattened or absent; in many medium-sized ones, it was cubical, and often there were several layers of cells; in others, again, it was of the columnar type already described. In some cases the cysts were quite spherical, but in others the cavity was irregular, smaller spaces opening into its lumen by narrow necks, as though fresh cysts were breaking into the first. Sometimes appearances like bile canaliculi could be seen in the walls of large cysts. All the larger cysts contained colloid material. In some places the cysts were undergoing degenerative changes, and being invaded from the periphery by small and deeply staining cells, apparently leucocytes. The margin of such cysts fused with the surrounding connective tissue, and it appeared that the whole cyst was being converted into fibrous tissue. In other places the change seemed more advanced, and masses of dense tissue were seen like nodules grouped round a central lumen. This tissue was stained badly, and showed no sign of cell elements. With the exception of these nodules, the connective tissue throughout the liver was richly cellular and stained well.

Kidneys.—Here, as in the case of the liver, the cirrhotic change was very striking, and all the sections showed a great increase in the connective tissue.

In the cortex the appearances in many respects resembled

those seen in chronic interstitial nephritis. Many glomeruli were apparently healthy, the nuclei of the epithelial cells staining well; others were atrophic, with the capillary tufts shrunken; while others, again, were becoming cystic. In some of the latter the capsule was dilated and the capillary tuft more or less completely changed into homogeneous colloid material, which was unstained. This mass was in some cases still attached at the base where the vessels entered, and here the nuclei still

FIG. 35.

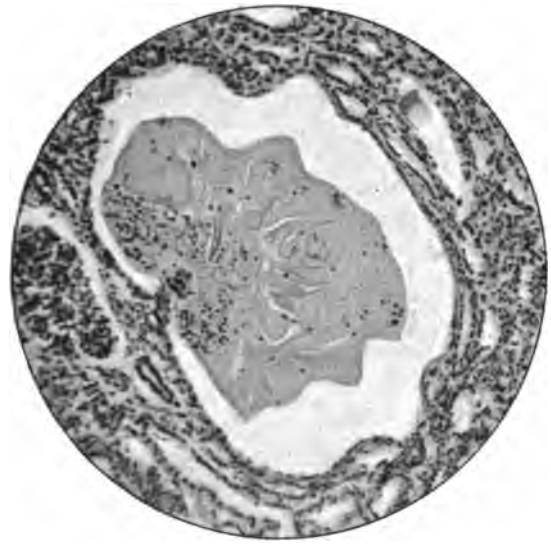

Showing a dilated capsule and contained glomerulus. × 350.

stained well; in others all attachment was gone, and the colloidal mass was free in the cavity. Around almost all the glomeruli there was a distinct increase in the connective tissue, and in some cases it formed a definite fibrous ring, especially when cystic changes were taking place. The convoluted tubules in most cases contained swollen granular epithelium, sometimes almost filling the lumen; others were atrophic; several contained colloid casts. In a few cases they appeared to be becoming cystic. In these the epithelium was proliferating, and several layers could often be seen, those projecting into the lumen being cubical and fairly large, with the nucleus at the base, and the rest of the cell clear and homogeneous. In such

cases, when the cells were being shed into the lumen these were swollen into ovoid masses of colloid material, and seemed to be fusing with like substance contained in the cyst. The arterioles had thickened coats, and were embedded in connective tissue, which was fibro-cellular in character and excessive throughout.

In the medulla the increase in connective tissue was even more marked. Here there were fewer stained nuclei and more fibrous strands. In some places there were dense masses of this tissue, with only here and there an isolated looped or straight tubule. In other parts of the field the changes were not so advanced, the connective tissue being more cellular and the tubules more abundant. Of these, many of the straight tubes were dilated, and some were distinctly cystic. The blood-vessels showed similar changes to those noted in the cortex.

The cysts.—Scattered through both cortex and medulla were numerous cysts of various sizes, containing as a rule unstained colloid material. In some cases this material appeared more granular and broken up. All had a definite fibrous capsule of variable thickness, and in most cases a lining of epithelium could be made out. In the larger cysts it was flattened, but in the smaller ones it varied, being sometimes cubical, sometimes flat. Many of those of the latter type appeared to be derived from Malpighian bodies. The section of the majority of cysts was roughly circular and the margin fairly regular; in a few cases, however, the edge appeared crinkled, so that cleft-like spaces branched off. Some of the smaller cysts had septa across them. In the case of several cysts the margin was ill-defined, and the surrounding connective tissue seemed to be encroaching on the lumen. In such cases the contained material was granular and showed numerous well-stained cells throughout, but most numerous near the edges where invasion was taking place. This was evidently a leucocytal infiltration. The surrounding tissue also showed countless nuclei and similar small cells. Where the change seemed more advanced all appearance of colloid material was lost, and a large mass of fibro-cellular connective tissue remained, containing often fat cells in the meshes.

Case 2.—E. B—, aged 43, female, single, was admitted to Prince Alfred Hospital in 1899. She had been a cook at the hospital up to a few months before her illness, and was admitted

for observation, as she was said to be showing signs of mental aberration. No history could be obtained owing to the mental condition.

On examination.—A sallow, anæmic woman, somewhat wasted. No jaundice. Restless, noisy, incoherent, with insane delusions. Heart dilated, sounds weak but clear. Pulse 120. Temp. 102°.

Abdomen apparently tender, somewhat full; muscles held on guard. In each loin could be palpated a large rounded mass the size of a small cocoanut.

Urine.—Acid, 1020. Loaded with pus and albumen. Quantity not recorded.

Death took place twelve days later with uræmic symptoms.

Autopsy.—Both kidneys were greatly enlarged and showed numerous cystic projections. The weight was not recorded. There was no perinephritic inflammation. The capsule stripped with some difficulty. On section both kidneys were found to be cystic throughout, the cysts varying in size up to that of a large walnut, but most were smaller, like marbles. They were lined with a smooth, shining membrane. There was very little kidney substance visible, and all trace of distinction between cortex and medulla was lost. The pelvis and calyces of both kidneys were dilated and contained pus, but no communication between the cysts and the calyces could be detected. There were no calculi present. The contents of the cysts varied; some contained pus, others viscid, turbid, non-purulent material.

The liver was enlarged, and a few scattered cysts were visible on the upper surface, varying in size from a pea to a cherry. On section the liver was tough, and a few more cysts were seen in its substance. The cysts contained straw-coloured watery fluid, and were lined with a smooth, shining membrane. The heart was somewhat enlarged, and the left ventricle dilated; the muscle was soft. The condition of the other organs is recorded as healthy. Unfortunately the specimens were not kept, and I can find no record of any microscopical examination having been made.

Case 3.—L. A—, female, aged 49, married, was admitted to Prince Alfred Hospital in 1899. She complained that for some months she had been losing weight, and attributed this to a swelling just under the ribs on the left side, which gave her

great pain. This pain would periodically become more severe, when the swelling would increase and become hard and tender. After a time a quantity of matter would be passed in the urine, and the pain would be relieved, with decrease in the size of the swelling. She had never had any pain in the right side, and had had no discomfort in passing her urine even when the matter was very abundant. Her previous health had been remarkably good, and she had given birth to fourteen children, the last eleven months before. Eleven children were alive and healthy, including the last.

On examination.—A wasted, sallow-looking woman, no signs of jaundice. Heart dulness not increased, sounds weak; first mitral slightly prolonged at the apex, but no definite murmur. Pulse 120. Temperature normal.

Abdomen lax, some resistance and tenderness in left loin, where a large mass was readily palpated in the position of the left kidney; it was firm, rounded, tender, and about the size of a small cocoanut. The right kidney could not be palpated.

The liver was readily felt, the lower edge reaching fully two and a half inches below the costal margin. In the right lobe, about two inches from the mid-line, and near the edge, a swelling could be felt about the size of a tennis ball, somewhat flaccid, and apparently thin walled, and close beside it a nodule about the size of a small cherry.

The urine contained albumen and pus, and had a specific gravity of 1020.

After fourteen days, during which the temperature was very irregular, and the amount of pus in the urine varied greatly, it was decided to evacuate the supposed hydatid cyst, and at the same time examine the condition of the right kidney.

On opening the abdomen over the cyst, the upper surface of the liver was found to be studded with small cysts, from the size of a grape to a split pea, while immediately under the incision was one larger one, about the size described above; this was aspirated and opened, and found to be a true cyst of the liver, and contained no sign of hydatid membrane. The fluid from the cyst was watery, faintly straw coloured, contained a trace of albumen, and did not reduce Fehling's solution. Under the microscope no hooklets or other evidence of hydatid could be detected. The right kidney was palpated and found to be

fairly large, but showed no sign of cystic degeneration. The left was imbedded in indurated perinephritic tissue and extremely hard.

Three weeks later, when the first incision was quite healed, the left kidney was excised and found to be a mass of cysts surrounding a central cavity containing a quantity of pus. It was impossible to remove the kidney intact, but an examination of the mutilated organ showed a number of cavities containing pus or turbid fluid, not communicating with the pelvis of the kidney, and of the nature of cysts. They were lined by a smooth, shining membrane. A microscopical examination was not made.

The patient made an uninterrupted recovery, the temperature gradually falling to normal, and after gaining considerably in weight, left the hospital, passing from two to three pints of urine in the day, with specific gravity about 1008, and usually a faint trace of albumen. I have not seen the patient since, as she lives in the interior, but she writes that she is now, three years later, much stouter and in excellent health.

Case 4.—I am indebted to Dr. Kilvington, of Melbourne, for the history of this case, and also for the microscopical specimens which he kindly allowed me to examine.

This was a monster born at full time. It was necessary to perforate in order to effect delivery, as a condition of hydrocephalus was present. The kidneys were found to be enlarged and cystic. The liver contained no macroscopic cysts, but under the microscope numbers were discovered.

The mother was apparently healthy, but had given birth about two years previously to another monster with a hydrencephalocele necessitating embryotomy. This fœtus also had cystic disease of both kidneys, but neither the kidneys nor the liver were examined microscopically.

Microscopic examination of the kidneys in this case showed a marked increase in the connective tissue throughout the organs. Embedded in this were numerous apparently normal tubules of the various types, and Malpighian corpuscles. Besides these there were numerous cysts, varying in size from what looked like dilated tubules to large cavities. Some of these were lined with cubical epithelium exactly like that of the normal convoluted tubules, and had almost certainly originated in them. In others

the epithelial lining was quite flattened, and as this form of cell wall was present in quite small cysts, it seemed likely that they were dilated Bowman's capsules. As, however, in none of them could any sign of the vascular tuft be detected, it was impossible to decide with certainty as to their origin. In all the larger cysts in which any evidence of epithelial lining remained this was more or less flattened in character. All the cysts had a definite wall of fibrous tissue rich in cells, and there was also a definite increase in fibrous tissue round many otherwise normal tubules and glomeruli.

In one section there was a tube cut lengthwise, which seemed rather unlike a normal tubule. There was a distinct basement membrane of fibrous tissue with a lining of several layers of epithelial cells, the deeper being flattened, while those projecting into the lumen were more or less cubical. About the middle there was a distinct dilatation, as though at this point it was likely to become cystic. In some parts, again, there was no sign of ordinary kidney structure, its place being taken by a mass of undifferentiated cellular tissue, much like that seen in some sarcomata, and in one place there was a central space surrounded by round-cells, outside which again was an encircling mass of spindle-cells, held together by a slender fibrous network. It was impossible to say if the appearance was due simply to some of the central cells falling out, or if here also there was a rudimentary cyst. There was certainly no evidence of a basement membrane.

In the liver there was also a striking increase in the connective tissue throughout the organ, which was likewise rich in cells, and was most abundant in the portal spaces, but also passed in between the lobules to some extent. There were numerous cysts, chiefly in the portal canals, but also between the lobules. They clearly originated in the bile-ducts, which were seen in all stages of dilatation. Many appeared normal, but scattered among them were numerous cleft-like spaces lined with columnar duct epithelium; wherever these were present there was an increase in connective tissue. They had a definite wall of fibrous tissue, and in nearly all a definite lining of epithelium could be seen. No distinct branching could be made out, though in places it appeared as though several had run together. In none of the cysts could any projections into

the lumen, like those seen in ovarian cystomata, be detected. The liver cells were healthy, and there was no evidence of vacuoles in or between the cells, nor were there any signs of bile pigment.

The veins in the portal spaces seemed more than usually full of blood, and their walls were thick; the capillaries in the lobules were dilated.

CASE 5.—This case was briefly reported in the 'Intercolonial Medical Journal' by Dr. J. A. Reid (1), who operated.

I was enabled to examine some mounted microscopical sections of the liver which were in the possession of Dr. Kilvington.

A male, aged 62, came under notice, complaining of pain in the region of the left lobe of his liver. There was a history that he had some years before coughed up material like hydatid cysts.

On examination the lower part of the thorax was considerably expanded and barrel-shaped. The area of liver dulness was much increased; the heart sounds were normal.

Urine not noticeably increased in quantity; trace of albumen.

Operation.—An opening was made in the abdomen, and a large cyst found in the upper surface of the liver, from which clear fluid was obtained in which there was no evidence of hydatid, neither cyst-wall, nor scolices, nor hooklets. The left kidney was felt to be enlarged, but was not interfered with; the right was not examined. The cavity was drained, and bile-stained fluid flowed from it for some days.

The patient died on the seventh day with uræmic symptoms.

At the autopsy he was found to have large cystic kidneys and cystic disease of the liver. The liver presented the usual honeycombed appearance, being riddled with cysts of various sizes up to the large one (the size of a fœtal head), which had been opened. The weight I was unable to ascertain, but the organ was said to have been considerably enlarged. The cysts were lined by thin, smooth walls, and contained clear, watery fluid.

Microscopical examination showed a condition precisely similar to that found in many other recorded cases.

There was an increase of interstitial tissue throughout, especially marked in the portal spaces of larger size. Around the

bile-ducts there was an excess of fibrous tissue richly cellular. Many of the ducts appeared to be normal, but others showed various stages of dilatation till they appeared as cysts with well-defined fibrous walls, fading off into the surrounding connective tissue. In the larger cysts no definite epithelial lining could be made out, but in the smaller ones it was usually evident, the cells varying from being flat to cubical, or even columnar in type. The nuclei stained well. Some of the cysts were somewhat irregular in shape, as though possibly formed by the fusion of two or three. In none of those I saw could any appearance of vegetations covered with epithelium, resembling papillary proliferations in ovarian cysts, be detected. The liver cells were fairly healthy in appearance, though many of them seemed smaller than normal; in some there were signs of commencing fatty degeneration. In none was there any evidence of vacuoles, nor were there any appearances like vacuoles between the cells. There was an increase of fibrous tissue round the vessels, and many of the venous spaces seemed unusually large. The capillaries in the central zone of the lobules, as well as those running between the lobules, seemed considerably dilated and were distended with blood. It was around these dilated capillaries that the liver cells seemed somewhat atrophied. At various points through the section were collections of dark material which seemed to be blood pigment.

Pathology.

In dealing with the pathology we are met with the difficulty that there is no apparent relationship between the two affected organs, and for this reason many writers have believed that the association is nothing more than a coincidence. It will be convenient, therefore, to first discuss the nature of the cystic changes liable to occur in the liver and kidneys separately, and later on to try and discover some common characters in the morbid changes found in this particular disease.

Cysts of the Liver.

Cysts of the liver of any kind, excluding, of course, those due to hydatid disease, are not common. A considerable number of cases have, however, been from time to time recorded.

Solitary cysts.—As a rule these have been solitary cysts, generally single, but occasionally two or three, or even more, have been present. In a case I saw at the Melbourne University there was one large cyst the size of a small orange, and about six others close to it; and Dr. Kilvington described to me a case of a girl dying after parturition (syphilitic), who had about thirty small cysts collected in one part of the liver.

Most of the cases described by earlier writers were regarded as due to dilatation of the bile-ducts. Dr. Budd (2) refers to cases, and speaks of their contents being tinged with bile. In some cases a direct communication with the bile-duct has been traced, in others a cause of obstruction has been found. Rokitansky (3) writes, "Cysts are rare. They are often clearly the result of dilatation of the biliary passages." Biliary staining is by no means constant, and in several cases all trace of bile has been proved absent by chemical analysis. Professor Frerichs (4) says, "Simple serous cysts with clear watery contents are not of frequent occurrence in the liver. I have repeatedly, however, observed isolated cysts in the organ, varying in size from a pea to a bean." Dr. Pye-Smith (5) mentions having seen a small cyst of this nature, the size of a marble, which he referred to Professor Virchow, who decided it to be due to obstruction and dilatation of a bile-duct, and to be in all probability congenital. During the last ten years two cases have been described in the 'Lancet,' in which large single cysts, not hydatid, required surgical interference; one of these was associated with cirrhosis of the liver. I have myself seen but one such cyst at a *post-mortem*, but I had an opportunity of examining microscopical sections of four specimens collected by Professor Allen during the period he has acted as Honorary Pathologist to the Melbourne Hospital, three being single cysts and the fourth the case above mentioned.

Microscopically there was a remarkable similarity in the sections, but it was impossible to determine the origin. The appearance presented was that of a cavity, lined by a fibrous capsule which was fairly thick and almost non-cellular. In one of the smaller cysts a few flattened epithelial lining cells could be made out. In all there was a definite increase in the connective tissue throughout the liver, especially in the portal spaces. This, unlike the walls of the cysts, was fairly rich in

cellular elements. In all the cases the condition of the capillaries in the central zone of the lobule was striking; they were dilated and full of blood, and the surrounding liver-cells seemed atrophied. Some of the veins were also engorged. Dr. Kilvington has noted this appearance in two other cases of liver cysts, while it was also present to some extent in the liver of the infant already described (Case 4). He was in doubt as to whether the condition was simply one of venous engorgement or if there was a vascular change allied to angioma. A similar condition is referred to by Dr. Bristowe (6), who, in describing the appearance presented by the liver in one of his cases, says: "In several places the network of the lobule was very lax, the meshes appearing larger than usual. The capillary vessels appeared stretched out, and the liver-cells disintegrated." So, again, Dr. Kennedy, "The capillaries in the central zone of the lobules were slightly distended with blood."

Reference has been specially made to this peculiar condition in view of the fact that Dr. Rolleston (8) speaks of degenerative changes in nævi as a possible, but not probable source of origin of simple serous cysts of the liver. In none of these cases, however, did the angeiomatous appearance extend beyond the small capillaries.

Nearly all writers incline to the opinion that these cysts are due to obstruction in some way of the bile-ducts, hence it is remarkable that they are so rarely met with in cirrhosis of the liver. Indeed, the case I have already referred to is the only one I can find mentioned. Even in long-standing biliary obstruction the effect on the bile-ducts is to cause atrophy, or gradual dilatation throughout their length rather than localised cyst formation, though in prolonged cases the bile is replaced by clear, mucous fluid. I have seen one remarkable specimen preserved in the Sydney University Medical Museum, where, as the result of primary carcinoma at Vater's papilla the gall-bladder and large ducts were enormously distended. The bile-ducts throughout the liver were greatly dilated, and those under the capsule presented an appearance like large varicose veins on the leg. By squeezing the gall-bladder and ducts and driving the contained fluid into the liver the whole organ visibly swelled, and the huge varicose ducts stood out all over the surface. Yet nowhere was there any sign of a definite cyst.

Pseudo cysts.—The so-called cysts due to softening of strangulated masses of cells in cirrhosis, and to breaking down of cancerous nodules, or tubercular deposits, need no more than passing mention.

Dermoid cysts.—I have Dr. Rolleston's (8) authority for saying that true dermoid cysts are not found in this organ.

Adenomata.—A few instances have been recorded of cystic adenomata of bile-ducts; some have reached a large size, and one has been successfully excised, the patient being alive eight years later. In all these cases the adenoma has formed a strictly localised tumour, showing no tendency to invade the rest of the organ.

Parasitic cysts.—Certain cystic conditions, due to parasites other than the echinococcus, deserve mention as having perhaps some bearing on the irritative theory of origin in the multilocular cystic condition to be next described. First among these must be mentioned the condition known as "coccidiosis," most familiar in rabbits, but occasionally seen in man. The cystic formation in this disease, however, has the appearance of an invading growth rather than a cyst simply destroying the surrounding tissues by its gradual increase. A still more interesting condition was briefly reported in the 'Lancet' of 1899, vol. i, p. 1093, in which a man dying of carcinoma of the pylorus was found to have a number of cysts in the region of the portal canals containing living "paramœcia." These cysts were smooth, with a wall of fibrous tissue, and apparently originated in bile-ducts.

Multiple cysts.—There remains to be considered the condition in which the liver is converted more or less completely into a mass of cysts, described by Dr. Rolleston (8), under the name of "Multilocular Cystic Disease." So far as I can ascertain, this condition has been found to be invariably [1]

[1] The only apparent exception I could discover was a case an account of which was read before the South Australian branch of the British Medical Association by Dr. Hayward in 1891. A female child, æt. 6½ years, was tapped three times for ascites, a large amount of fluid being removed on each occasion. Subsequently she was operated upon for cystic tumour of the liver, suspected of being a hydatid. The surface of the liver was studded with cysts of various sizes containing clear fluid. After death, four days later, general chronic peritonitis was found, with thickening of the capsules of the liver and spleen. The liver was greatly enlarged and firm. There were numerous cysts on the

associated with a similar, but usually more advanced, kidney change. The distribution of the cysts is by no means uniform; in one of the earliest cases recorded, that of Professor Frerichs (4), in the liver of an old woman dying of pneumonia, "numerous cysts from the size of a pea to that of a bean, with clear watery contents" were found in the neighbourhood of the falciform ligament. It may be worthy of mention that in this case only one kidney, the left, was cystic. It will be remembered that in Case 3 of my series, the cysts were only seen on the upper surface of the liver, while it was the left kidney which was removed, while the right was apparently not enlarged. Rindfleisch (9) records a case in which the cysts were most numerous in the anterior part, the free border of the left lobe being specially affected. Dr. Pye-Smith (5) speaks of his cysts being most numerous on the upper surface, and a similar note is made by Dr. Paterson (10) in regard to his case. In most of the other cases the disposition of the cysts has been fairly uniform. In all the cases, however, they have been very numerous, and in this respect, Case 2 in my series stands out as a rather remarkable exception, at least, as far as the macroscopical appearance can be taken as a guide.

As a rule the liver is somewhat enlarged, sometimes very greatly; in nearly all cases it is recorded that the weight is increased, and the consistence tough. The cysts vary greatly in size, but in all the adult cases some have been large enough to be at once detected by the naked eye. In infants, however, the cysts may be so small as to be readily overlooked, unless a microscopical examination be made. Thus Dr. Still (11) expressly states there were no cysts visible to the naked eye on the surface. In describing the liver he says, "It was pale, and its surface was not so uniform as normal, having a finely stippled appearance, as if there were minute depressions scattered over the surface," and "there was no gross irregularity of any kind." In my Case 4, Dr. Kilvington tells me there were no macroscopic cysts. I have had no opportunity of

surface, chiefly on the under surface, and Professor Watson, who made the autopsy, was of opinion that they took their origin from the capsule of the organ. It is therefore probable that they were derived from included portions of the peritoneum, in the same way as those cysts occasionally found upon the surface of other organs with a peritoneal covering. The kidneys were somewhat congested, but otherwise normal.

examining microscopically the liver of an adult in whom cystic disease of the kidneys alone had been present, but it is possible that systematic examination in such cases might lead to the discovery of an early condition like that in the infantile type. The contents of the cysts have varied greatly. In the majority of cases they have been clear and watery, and contained a small amount of albumen. Bile and bile acids seemed to have been generally absent. In other cases the fluid has been described as milky, muco-purulent (Budd) (2), waxy, reddish or buff inspissated material (Bristowe) (12). The cysts in five of my cases contained clear fluid, in the other colloidal material rich in albumen and mucin. Of other constituents of the fluid, urea is usually abundant, and blood-cells, cholesterin, and tyrosin have been found.

Microscopically the cavities have a wall of fibrous tissue, lined on the inside in the case of the smaller cysts with columnar, cubical, or flattened epithelium. In the larger ones all trace of epithelial lining is usually lost. These cysts are in nearly all cases principally found in the portal spaces. Here there is invariably a marked increase in the connective-tissue, rich in cellular elements, showing round, oval, and elongated nuclei, but it is not limited to the portal spaces, and spreads in between the lobules. Embedded in it are found bile-ducts in various stages, normal, atrophic, and dilated and filled with shed epithelium. Dr. Kennedy (7) noted that around some of the ducts in his case distinct rings of fibrous tissue of considerable thickness could be detected, and a similar condition was present in my first case. Besides what can be recognised as ducts, there are cysts of various sizes and shapes, some small and simple, others large, with evidence of broken down septa, pointing to the fusion of two or more smaller cysts into one large one. In the case of infants, irregular branching cavities are seen, surrounded by connective-tissue, especially abundant in the portal spaces, but by no means limited to them, and sometimes occurring inside the lobule amid normal liver-cells. Dr. Kennedy (7) describes one or two fibrous nodules, which he considers to be the contracted walls of cysts which have closed. With these may be compared the appearances described in Case 1, where the process of conversion into connective tissue is seen taking place in several parts of the field. In a few

instances the cysts have been found principally among the liver cells in the lobules, and away from the region of increase in the connective-tissue. These cysts have been associated with the vacuolation of the liver-cells to be presently described, and have a very narrow wall of fibrous tissue without epithelial lining.

The secreting cells of the liver vary greatly in the different cases: in most they appear comparatively normal, except when atrophied by encroachment of the connective-tissue, or by pressure on the cysts. In others there is more or less of a fatty change; in my case (1) this is very advanced. In a few instances distinct vacuolisation of the cells has been recorded. Dr. Pye-Smith's (5) case is perhaps the most remarkable example, and there appears no doubt that the vacuoles were definitely intra-cellular. In Professor Kanthack's (13) and Dr. Rolleston's (8) case the vacuoles were chiefly extra-cellular and inter-lobular, and these writers consider them as being dilated bile canaliculi. In some of the cases it is by no means certain that the appearance was not due to *post-mortem* changes. I have seen such an appearance myself, in the case of the liver of a man who died from an acute illness, there being cavities of an indefinite character, without distinct walls, scattered through the tissues, and the liver cells showed spaces of various sizes. Dr. Hale White records two cases which may come under this category, one being that of a man who died from yellow fever. Similar cases are said to have occurred in lunatics, and the spaces have been found to contain gas and micro-organisms.

Pathogenesis.

It is to be expected that many theories of origin should have been put forward to account for this remarkable condition. According to Dr. Still (11), the causes suggested are:

1. Cirrhosis, as the result of some irritating material leading to a connective-tissue overgrowth which is especially marked about the bile-ducts, pericholangitis of Dr. Rolleston, and results in their proliferation and dilatation.

2. Vacuolisation of the liver-cells, which by coalescence of the vacuoles leads to the formation of cysts.

3. A spontaneous proliferation of the walls of the bile-duct, occurring in adult life and giving rise to a biliary angioma.

4. New growth.

To these he adds a further suggestion, that the change is due to—

5. A congenital malformation.

The theory first mentioned is the earliest suggested, and has been most generally adopted, and as it is the one which seems to me to explain most satisfactorily my own cases, I shall discuss it after the others.

2. *Vacuolisation of the liver cells.*—In not one of the cases in which I had examined the liver microscopically was there any suggestion of vacuolisation of the liver cells, with the exception of that in which the appearance was obviously due to *post-mortem* changes. In the cases reported by Dr. Hale White it was suggested in the discussion that followed his paper at the time that the change might have been a *post-mortem* one. In Professor Kanthack's (13) and Dr. Rolleston's case, as already stated, the vacuoles were thought by the authors to be dilated bile canaliculi, and not in the cells at all, and to be due to obstruction from a condition of intra-uterine biliary cirrhosis, with dilatation of ducts. They compare the condition with a case of Icterus neonatorum, reported at the same time, without cysts, but with similar vacuoles filled with bile and well-marked biliary cirrhosis. Dr. Pye-Smith's (5) case then seems to stand practically alone as an example of cystic disease undoubtedly arising from this cause. It is possible that this case may belong to a different category altogether. Dr. Still (11) suggests that the vacuoles, admitted by the writers to be partly extra-cellular, may really be part of a developmental peculiarity, and thus belong to the malformation he suggests in his own case. For my own part it seems as easy to believe that the condition may be an unusual form of degenerative change, in some way dependent on, or due to, the same cause as the connective-tissue overgrowth found in other parts of the same organ. While, if the observations of Pflüger and Kupfer (Allbutt's 'System of Medicine,' vol. iv, p. 5) are correct, and vacuoles can be demonstrated in normal liver cells communicating by minute channels with adjacent canaliculi, it is conceivable that in the cases in which vacuolisation of the cells has been found, the obstruction of the channels has for some reason occurred nearer the cells than in those in which this feature is absent.

3. *Biliary angioma.*—The ingenious suggestion of Sabourin has met with little support. I have not been able to obtain the original article, but according to Dr. Kennedy (7) he describes dilatation of the small bile-ducts, and thickening of their walls, which he says is nodular and lateral, rarely angular. He lays great emphasis on the marked increase in the biliary canaliculi, and divides the formation of liver cysts into three periods: (*a*) New formation of canaliculi. (*b*) Dilatation and anastomosis of these to form "angiomes cavernes biliaries." (*c*) The breaking down of septa to form cysts. I have been unable to detect in my sections any evidence of anastomosis of the biliary canaliculi, and it is doubtful if atrophy and disappearance of liver-cells will not account for any apparent increase in the number of bile-ducts. There is certainly nothing to suggest biliary angioma.

4. *New growth.*—The form of new growth suggested is that of cysto adenoma of the bile-ducts, which are compared to those in the breast in which the cystic element is greatly in excess of the connective tissue. Janowski (16) considered his case to be one of tubular adenoma, with proliferation of the epithelium of the bile-ducts, and round-cell infiltration about them, with also proliferation of the liver-cells. As already mentioned, unquestionable adenomata, though rare, have been occasionally reported, but they have been always strictly localised to definite areas of the liver. Certainly nothing of the nature of such an infiltrating adenoma has been recorded in any other organ. Nor is there in any of my sections, nor in any drawing I have seen of others, anything to support such a theory.

5. *A congenital malformation.*—Dr. Still (11), in the most recent and most exhaustive account of the disease so far published, in reporting two cases in infants, contends that the cysts are the result of congenital malformation. Referring to the development of the liver in the embryo when the two diverticula of hypoblastic cells, growing from the ventral wall of the duodenum are making their way into the central mass of mesoblastic tissue between the abdominal wall and the duodenum and stomach, he finds the precursors of his cysts in some of the columns of cells which go branching and anastomosing to form the intricate network of which the fully-formed liver is eventually composed. Relying on investigations of most recent writers, who have shown that the columns of hypoblastic cells which are

formed from the duodenal diverticulum have a definite lumen at an early stage, he suggests that some of these columns are, through some irregularity, left with their original lumen. Granting this, it is easy to conceive such isolated tubes, lined with epithelium, gradually becoming filled with fluid, till they presented the appearance of "spaces lined with columnar, cubical, or subcubical epithelium."

Meanwhile the bile-ducts are normally developed, and perform their functions so that no jaundice is present. By a further assumption that there is a persistence of the fœtal mesoblastic stroma, the excess of connective-tissue is explained, as a malformation and not a product of inflammation. In support of this latter hypothesis Dr. Still (11) cites the fact that there is normally such a persistence of the mesoblast wherever the bile-ducts run, and hints that perhaps in some way each of the false ducts determines the persistence of a certain amount of the stroma around itself.

Such is the most recent theory of congenital malformation, and it is urged in support, that the presence of vasa aberrantia, or isolated duct-like spaces found on the surface of the liver in some parts, can only have been formed in some such way. Great stress is laid by Dr. Still (11) on the fact that his theory most satisfactorily explains the absence of jaundice.

1. *Cirrhosis.*—To turn now to the oldest theory, it may be noted that an increase of the connective tissue of the liver has been present in every case so far recorded, a fact which would certainly at first make us inclined to look for some irritation or inflammation as likely to be, at least, playing a part in the change. This first impression will be supported by the fact that many writers have proved to their satisfaction that it is from the bile-ducts that the cysts are derived, and that it is around them that the greatest increase in the connective tissue is found. Unfortunately for the theory, in cirrhosis of the liver, where a maximum of dense fibrous tissue is found, cysts are exceedingly rare, and, unless we accept the authors' view in Kanthack's (13) and Rolleston's case, that their cysts were due to obstruction from cirrhosis, have never been recorded as present in any number. Thus at the outset the irritation hypothesis would seem to be inconsistent with other observed changes in the liver. None the less most writers have clung to their

theory, and held that for some unknown reason the irritation acts differently in these cases.

In the first place, there is no doubt that cystic conditions of the bile-ducts do in certain instances result from irritative causes, using this term in the widest sense. The cases resulting from paramœcia, and those due to the coccidia may be cited as examples. Dr. Ewan Frazer (17), in speaking of observations made upon two well-marked cases of cystic disease of the liver, associated with cystic kidneys, states that he found that they were, in all probability, due to the action of *Bac. aërogenes capsulatus.* He does not describe the character of the cysts, but the fact that the micro-organism was found is worthy of note.

In Dr. Kennedy's (7) case, distinct fibrous rings were detected around the bile-ducts, and Sabourin (15) reports a like condition. When such an appearance is found to be present in connection with practically normal ducts, lying in an area in which are other ducts in all stages of dilatation, and cysts surrounded with a thick, fibrous capsule, it seems beyond all reasonable doubt that in such cases the one is the forerunner of the other, and that the gradual constriction of the one part of the duct has played at least a part in the dilatation of another. Granting this origin for the cysts, it is difficult to suggest any other cause for the fibrotic change about the bile-ducts than some irritant, probably a poison circulating in the blood and excreted by the cells of the liver or ducts themselves. Further, with our knowledge of the enormous variations in the changes produced in the same tissues by different toxins, it is not a difficult matter to conceive that the effect upon different parts of the liver may likewise vary, and that some toxic product may cause a simple overgrowth of the connective tissue, with resulting atrophy and degeneration of the secreting cells, while in another case the poison, while causing a perhaps more gradual connective-tissue change, may have some special action upon the epithelial cells lining the bile-ducts. The result of such an action might well be the formation of cysts, which, at first containing bile still running in from the secreting cells of the liver would later on, as they become more isolated, secrete their own contents from their lining cells. The microscopical appearance present in two of my cases simply repeat what has

been observed on many a previous occasion, but in Case 1 a condition is found quite different in many respects from anything I can find hitherto described. As will be seen from the micro-photographs and from the detailed description already given, we have here a condition of connective-tissue overgrowth in the portal spaces fairly rich in cellular elements, and embedded in it are bile-ducts in different stages. Some are apparently normal, others are dilated in varying degrees till all trace of their origin is lost and simple cysts remain. It is noticeable that many, even quite large cysts, have a well-defined lining of tall, columnar, epithelial cells. A remarkable point about all these cysts is the fact that, when the bile-ducts begin to dilate, mucoid or colloid material is found to be present in them, and the lining cells take on the characters of cells lining a colloid cyst. This is evidently a degenerative change, for mucoid or colloid changes in the cells of a natural duct or alveolus are usually degenerative in character (Sims Woodhead [18]), (Cornil and Ranvier [19]). Moreover, in some of the sections it is evident that in some cases, after reaching a certain size, the life of the epithelial cells becomes exhausted, leucocytal invasion takes place, and the whole cyst is gradually converted into a mass of fibrous tissue. In this liver, then, we have a condition of connective-tissue overgrowth with cystic degeneration of bile-ducts, which was clearly in active progress at the time of death. This can hardly be a congenital condition, for it is certainly not a malformation, and it is improbable that the change has been going on since birth, and has allowed life to continue to forty-two years, still leaving an enormous number of bile-ducts unaffected. Again, there seems no reasonable doubt that the condition is due to some irritative or inflammatory change which has acted especially on the bile-ducts. There is, however, one respect in which this liver differs from those in other reported cases. I refer to the gross obstruction of the large ducts by gall-stones. It may be suggested that these have caused the cysts. If so it will still be an instance of cystic liver, not of congenital origin; however, I do not think that the stones were more than an accidental complication, and would point out (1) that cystic conditions of the ducts have not been recorded as the result of gall-stones. (2) That the jaundice and pain were of only two months' duration, and that the connective-tissue overgrowth and

cysts could hardly have developed in that time. (3) That exactly the same degenerative change was present in both kidneys, in neither of which was there any gross obstruction of the nature of a stone.

I think, however, it is probable that the extreme fatty change in the secreting cells of the liver was at least partly due to this cause.

I think then I am justified in considering this case an instance of cystic disease of the liver, developing, after birth, as the result of degenerative changes in the bile-ducts, associated with extensive connective-tissue overgrowth throughout the organ, and that these conditions are both due to some irritative cause still acting at the time of death. If it is admitted that such is the case, it is likely that the condition is brought about in like manner in some at least of the other reported cases in adults, and further, that in the congenital form of the disease similar factors are at work.

Cysts of the kidney.

Omitting from the discussion hydatid cysts, cystic conditions due to obvious malignant or tuberculous disease, and hydronephrosis and allied states due to dilatation of the renal pelvis or calyces, we are left with four clases of cysts usually described.

1. *Dermoid cysts.*—A very few instances are on record of dermoid cysts in man, more have been observed in animals. They present the characters of dermoid cysts in other organs, and obviously have no bearing on the present question.

2. *Simple cysts.*—Cases are frequently met with, especially in old people, in which large cysts containing serous fluid are present in the kidney. As a rule they are single, occasionally several are present together. Even then, according to Mr. Henry Morris (20), one or two are usually large, with the smaller ones grouped about them. The large cysts vary greatly in size, and may fill the whole abdomen and be mistaken for ovarian tumours. Any part of the kidney may be involved, but one or other end would seem to be a favourite site. Whenever they have been small enough for a starting point to be determined, they have been thought to take origin in the cortex. The cyst walls are usually thin, smooth on the inside, and lined

by a layer of tesselated epithelium; occasionally they are dense and almost cartilaginous. They contain clear serous fluid, unless hæmorrhage has taken place into them, when it will be blood-stained. Usually there is a trace of albumen, and no sign of any urinary constituents. They are practically unknown before the age of forty years, and are generally admitted to be due to obstruction of either a tubule or a Malpighian corpuscle, with dilatation behind the obstruction.

3. *Cysts associated with chronic interstitial nephritis.*—Small, scattered cysts are often present in granular contracted kidneys, and may be seen at autopsies on persons dying from this disease. Such cysts are as a rule few and isolated but may be present in large numbers. Usually the kidneys are of the small atrophic type, both organs being affected, but by no means equally so. In looking through the records of more than two thousand *post-mortem* examinations at the Sydney Hospital, I found three cases in which cysts of granular kidneys were sufficiently numerous to warrant the description of cystic degeneration, and in one of the cases I had an opportunity of examining the organs. In each case only one kidney was affected, and it was atrophic to an extreme degree, weighing three quarters of an ounce. On section it was found to be riddled with cavities, the largest being about the size of a pea. There was no distinction between the cortex and medulla. The opposite kidney in all three cases was larger than normal, weighing from nine to ten ounces, and granular. It is worthy of note, that in two cases there was hypertrophy of the left ventricle, while in the other, an old man of 68, the heart only weighed 6½ ounces.

A few cases are recorded in which the cysts have been sufficiently numerous and large to cause slight increase in the bulk of the organs. The cysts have smooth walls of fibrous tissue, lined by flattened epithelium, and are embedded in connective-tissue, in which can be seen atrophied tubules and Malpighian bodies. They contain clear serous fluid, without trace of urinary constituents. All writers seem agreed that these cysts originate in the tubules and Malpighian bodies, chiefly the former, as the result of obstruction from constriction by the connective tissue, aided probably by plugging of the lumen with masses of epithelial *débris*.

4. *Polycystic diseases of the kidneys.*—We come now to what is

commonly known as large cystic kidney in contradistinction to the small type just described. In this condition the whole of the renal substance at first sight appears transformed into a mass of cysts. This metamorphosis of the kidney is by no means rare, and a considerable number of cases have now been reported.

On the other hand, it is not very common. In Prince Alfred Hospital, in twenty years, eight cases have been diagnosed, most of them on the operation table, or in the *post-mortem* room. In three of them the liver was affected with cystic disease, and in two cases the change was unilateral. Curiously, a careful search through the register of diseases and the *post-mortem* records of the Sydney Hospital has revealed not a single instance in a period of nearly fifty years.

Two forms of the disease are usually described, one in infants and the other in adults. The adult form is most commonly found after the age of 40, and usually before 50, though cases have been recorded in persons dying at over 80 years. The age of the youngest of my own cases was 33 years. I have seen the condition in a child aged 6, in the Warwick Hospital, Queensland, where he had been sent for observation. In each flank could be felt a large tumour, occupying the position and having the shape of the kidney; the surface of the tumour was slightly irregular, as though cysts were projecting, the right felt larger than the left. The urine was acid, pale, sp. gr. 1010, and contained a faint trace of albumen. Mr. Henry Morris (20) refers to two other cases of the disease in children over 3 years of age. In both these cases only one kidney was affected.

Sex.—The lesion in the kidneys is said to be more common in men, while the combined lesion is more frequently found in women. Of the twelve cases referred to by me in this paper seven were in women and four in men, and the sex of one I do not know. Of these, five had the combined lesion, and three were women; while four of the seven kidney cases were also women.

As a rule the condition is bilateral, but by no means always so. Thus in Professor Frerich's (4) and Dr. Wilks's (21) cases of the combined lesion, and in two of my twelve cases, only one kidney was involved. Dr. Dickinson, quoted by Mr.

Henry Morris (20), found only one case in twenty-six cystic kidneys where the lesion was unilateral.

The general appearance of the kidneys is much as is described in Case 1 of my series. They are greatly increased in size and weight, but the original shape is fairly well retained, the size is sometimes enormous, constituting in the fœtus a considerable proportion of whole body mass, and obstructing delivery. The largest one I can find recorded in adults was one of Dr. Hare's (22), which measured 15¼ inches in length, and weighed 16 pounds.

The tumours consist of a conglomerate mass of cysts, looking on section not unlike a coarse sponge. All trace of distinction between cortex and medulla was lost. The cysts vary in size from points just visible, to quite large swellings; one in Dr. Hare's (22) case contained more than half a pint. Those near the surface project as bosses, forming irregularities, which can be detected by palpation during life. The cysts have a smooth shining wall, and their contents vary greatly. Some contain clear watery fluid, or it may be blood-stained, or thick and semi-solid, as in one of Dr. Bristowe's (12) cases, sometimes it is viscid, much like that from an ordinary multilocular ovarian cyst. In a few instances the fluid has been recorded as being purulent, as it was in two of my cases (2 and 3). In the fluid may be found albumen, urea, uric acid, triple phosphates, cholesterine, fat globules, epithelium, blood cells, blood crystals, and occasionally crystals of leucin. The calyces, pelvis, and ureters are usually not dilated, except when there has been apparently accidental septic infection, as in two of my cases, and it has been especially noted in two or three instances that the ureters appeared small. To the naked eye there appears to be practically no secreting tissue left, but under the microscope it is found that there is a considerable amount in the strands which separate the cysts. Examination of stained sections shows considerable overgrowth of connective tissue throughout, as in cases of chronic nephritis. This is usually rich in cells which stain well, indicating active growth, and is common to both infantile and adult types. In the strands of tissue between the larger cysts there is a network of microscopical cavities which reproduce the naked-eye appearances of a section of the whole organ.

Scattered about through this network are numbers of tubules and Malpighian bodies. The connective tissue between the tubules is greatly increased, but irregularly so, so that some are obliterated, others dilated, and others again have their lumen filled with plugs of colloid matter. The glomeruli may be practically normal, cystic, or transformed into masses of fibrous tissue. In some parts every sign of renal substance may have disappeared, its place being taken by fibrous tissue, which may have fat deposited in its meshes.

The cysts have fibrous tissue capsules, the thickness varying considerably in different cases. In the larger cysts as a rule there is no sign of an epithelial lining, but in the smaller ones this is usually demonstrable, the shape of the individual cells being flat, cubical, or in some cases columnar. Occasionally there is evidence of papillary growths into some of the cysts, such growth being formed of processes of connective tissue covered by epithelium projecting into the lumen. In many cases, as already mentioned, commencing cystic changes can be seen in parts still recognisable as tubules and Malpighian corpuscles.

The vascular changes appear to vary, as in some cases no special thickening about the vessels was found, while in many others this was a marked feature.

Endarteritis is often evident, but some writers have found the arteries smaller than normal.

The above will serve as a general description of the pathological changes, but a few cases have presented some additional appearances. Some of these cases require special mention, as it is upon these special features that the observers have founded their theories of the pathology of the disease.

1. Dr. Still (11), in reporting his case, an infant, notes that his sections showed numerous dilated tubes, irregular in shape and lined by flattened cubical epithelium. These tubes were separated by trabeculæ of fibrous tissue, and it was evident that there was much more connective tissue than normal. Embedded in the fibrous trabeculæ of the cortex were glomeruli and a few normal tubules; the glomeruli were normal but for some flattening from pressure. There was no sign of inflammation round the glomeruli nor about the vessels. In the case of the infant that I have reported it will be remembered that in one part there was an appearance of a dilated tube not unlike those

described by Dr. Still (11), and in another part what might have been a cyst originating in a mass of unorganised connective-tissue. On the other hand, however, there was distinct evidence of inflammation round the glomeruli and renal tubules; and some of the latter at any rate were certainly cystic.

2. Mr. Eve, quoted by Dr. Ewan Frazer (17), by injecting colouring matter into the lymphatics of one of his cases of cystic kidney, was able to show that the lymphatic vessels were large, numerous, and dilated, and in places formed cyst-like spaces.

Similar changes in the lymphatics are said to be present in a specimen in the Museum of the College of Surgeons injected with Prussian blue.

3. In Case 1 of my series the changes are everywhere of a colloid character, and both glomeruli and urinary tubules can be seen undergoing this change. In other parts the cysts are degenerating and being converted into masses of fibrous tissue.

Pathogenesis.

Pathologists differ greatly in their theories as to the origin of this disease. I have been unable to obtain a copy of the article by Dr. James Ritchie (23), which is highly praised by Mr. Henry Morris (20), but have made use of Mr. Morris's account, which is largely drawn from this. In discussing the various views a difficulty arises, in the first place from the fact that the disease is found chiefly at the two extremes of life, or at least either in very early or in rather advanced life. Some hold that these are instances of two diseases of quite distinct origin, while others argue that the condition found in advanced life has invariably commenced before birth; in short, that all cases are congenital. A third group of pathologists assert that the change is pathologically identical, but occurs at different periods of life. The three main groups are again subdivided according to individual views of the exact details of the pathology. These conflicting views may most easily be discussed by considering first those cases which occur in newly-born infants, as they are undoubtedly congenital, and comparing with them the conditions found in adult life.

To account for them four distinct theories have been put forward:

1. That there is a congenital defect in the structure of the kidney.

2. That there is a local destruction of tissue, with cystic softening of the areas.

3. That the cysts are of the nature of a new growth.

4. That the condition is the result of inflammatory changes.

I. *Congenital defect.*—Of the theories of congenital origin, that first suggested by Mr. Shattock (24), in reference to the infantile cases, of a congenital defect in the kidney has obtained the greatest support. He considered the condition a malformation, due to the mesonephros blending with the metanephros in its development. Hence the cysts would be retention cysts, the result of slow dilatation in these remnants of the tubular Wolffian body. Dr. Still (11) strongly supports this theory, and would apply it to adult cases as well. He holds that the tubes seen in his case are not renal at all, but developed from the mesonephros. He explains the large amount of fibrous tissue as being also an irregularity of development, "survival of the fœtal condition in which great excess of mesoblastic stroma is the normal appearance." This theory, he urges, would account for the fact, otherwise difficult to explain, that numerous quite normal tubules and glomeruli are found embedded in the fibrous tissue. When rapid dilatation took place in such cases death would result early, but where the change was slower life would be prolonged till the number of renal tubules and glomeruli escaping pressure atrophy was insufficient to support life. The end might, however, be hastened by the superimposed inflammatory changes to which such kidneys would naturally be particularly liable. Mr. Bland-Sutton (25) is inclined to adopt this theory.

Dr. Ewan Frazer (17), while inclined to favour the fourth hypothesis, mentions three cases which seem to lend some support to Dr. Still's (11) theory. In the first place he refers to a specimen in the Museum of the College of Surgeons, where there is extensive cystic transformation in the kidneys of an anencephalous fœtus, in which, on microscopical examination, no glomeruli could be seen. In each of the other two cases, one described by Dr. W. Edmunds (26), and the other by Thoma (27), an encapsuled tumour composed of a congeries of cysts lined by cubical epithelium was found in the substance of one of the

kidneys. In Thoma's (27) case there was a similar formation in the vaginal wall. Dr. Still (11) also cites, in support of his theory, the fact that in several recorded cases of the disease in infants other congenital defects have been present.

Against this theory, at least as applied to all cases, it may be urged—

(*a*) That the majority of observers have found unmistakable evidence of the origin of the cysts in the renal tubules, and in my first case there is no doubt that some of the cysts arise from the glomeruli, which can be seen in all stages of colloid degeneration, the colloid change apparently commencing in the Malpighian tuft.

(*b*) That it is unusual for inclusion remnants to be so uniformly distributed throughout the tissues of an affected organ, as would appear to be the case in all the recorded instances of cystic kidneys, except the two above-mentioned cases, in which an encapsuled cystic adenoma was present in one organ only. These cases would certainly seem to be examples of such inclusion, but, in my opinion, tell rather against the theory, as applied to the other cases, than for it.

(*c*) There is, as Dr. Still (11) reasons, no ground for assuming that there is any essential difference in origin between the large cystic kidney of the adult and the congenital form, and it is remarkable that, in practically all cases, death has either occurred in the first few months of life, or been postponed for at least forty years.

(*d*) Further, if the cysts are congenital we should expect that, as Dr. Still (11) allows, the kidneys will be especially prone to inflammatory conditions. Hence acute nephritis might be expected to take the lives of at least a considerable number, yet I can find no record of such a case. I have searched the records of the Melbourne Children's Hospital, and Dr. Ewan Frazer (17) has looked through those of the South-Eastern Fever Hospital (London) to see if any children dying from acute nephritis might have been found to have cystic kidneys. In neither case was a single instance met with.

On the other hand, evidence of chronic interstitial nephritis has been apparently always found in adult cases, and it is certainly curious that, in nearly forty cases with cystic disease of the liver and kidneys, the kidneys should have always escaped

the risks of acute inflammation, to which they would be specially liable, and should have allowed their possessors to die, with symptoms precisely similar to those of chronic nephritis, at about the usual age of death from that disease. Associated with the nephritis the typical cardio-vascular changes of renal fibrosis have been present about as often as in the case of ordinary interstitial nephritis.

Other theories of congenital defect, but obtaining less support, are—

1. That of a malformation resulting from a failure of union of the excreting canals with the secreting tubules.

2. An excessive feebleness of the tubules which renders them incapable of bearing the normal intrarenal pressure; thus Bard [of Lyons] (28) compares the polycystic kidney with cavernous angioma.

3. A dilated condition of the lymphatic vessels and spaces.

Most of what has been urged against Dr. Still's (11) theory will have the same weight when used as arguments against these latter suggestions.

With regard to the lymphatic theory, there seems no doubt that, in some cases at any rate, dilated lymph spaces do account for certain of the cysts, but, on the other hand, many others are as certainly derived from the secreting structures of the kidney. Further, it is easy to believe that such dilatation of the lymph channels may be but another result of the interstitial changes.

II. That there is a local destruction of tissue with cystic softening of the mass.

This theory assumes that local destruction of tissue takes place and that the cysts form as the result of degenerative changes in the affected areas.

I have been unable to find any record of such appearances in any of the reports I have seen, and they were certainly absent in my cases, and in No. 1 the cysts can be seen in their very early stages.

III. *New growth.*—A considerable number of writers have advocated the theory that the condition is of the nature of a new growth, the starting-point being in the epithelium of the tubules, and the disease being of a true neoplastic nature. Some of these writers would class it with the adenomata, others call it a gelatinous degeneration of the epithelium. Rokitansky (3)

believes that the cysts spring from colloid metamorphosis of cells.

This hypothesis of the disease being of the nature of multiple adenomata or epitheliomata, using the term in a different sense from its ordinary acceptance, and meaning by it, a proliferation, with degenerative changes, of the cells lining the tubules and covering the Malpighian tufts, has much to support it. In my case (1) there is undoubted evidence of some such changes in the epithelium. Dr. Coats (29), referring to a case with colloid changes similar to my own, suggests that the condition is due to a perverted function of the epithelial cells, probably congenital in origin, and supports the theory of its being of the form of a new growth.

It must be remembered, however, that such colloid changes have not often been recorded, and again, that a colloid change in the epithelium of secreting structures is a common sign of partial obstruction, and, according to Dr. Sims Woodhead (18), may be present in the cysts found in granular contracted kidneys. Hence it is not hard to believe that the change may be only a part of a sclerotic change, and the condition of the epithelium in some way determined by slow strangulation of the tubular structures. Perhaps, in addition, the behaviour of the epithelium may depend to some extent upon the nature of the toxic agent at work.

IV. *An inflammatory change.*—We now come to the fourth theory, that the disease is an essential part of a cirrhosis, and that owing to the cirrhotic changes there is constriction of tubules, with backward dilatation of them and of the Malpighian bodies.

As long ago as 1855, Professor Virchow (30), in reporting two cases in infants, brought evidence to show that there had been a fœtal inflammation of the papillæ, causing atresia of them, so that there was no communication between the uriniferous tubules and the calyces of the kidney. The cut off tubules and glomeruli were converted into cysts. Many other writers have supported the view that the change is due to cirrhosis, among whom Bristowe (12), Rindfleisch (9), and Paterson (10) also, may be mentioned. Dr. Kennedy (7) thinks that in these cases the stress of the interstitial change is thrown on the medulla, and that this accounts for the difference from the ordinary form of interstitial nephritis. Others, again, while adopting this

hypothesis, combine with it that of an epithelial change allied to a new growth. It is the only theory which will at all satisfactorily explain the changes present in my own cases. In both those in which the kidneys were examined there was undoubted extensive interstitial change about the tubules and glomeruli, but the appearances of the secreting structures differed widely. In the one case there were small lining cells with clear fluid in the cysts, in the other the epithelium was swollen and undergoing colloid change, shedding into the lumen layers of altered cells which in various sections could be seen gradually swelling up, and seemingly fusing with the central colloid mass. In like manner the glomerular tufts became converted into similar material. Other minor differences in the behaviour of the epithelium are recorded in other cases; in some the tubules alone are affected, while others describe dilated Bowman's capsules "with glomeruli, easily distinguished, flattened against the wall" (Beckmann [31], Klein [32], Ranvier [33]).

It can hardly be supposed that we are dealing with a large number of distinct diseases, and assuming that most, if not all, the recorded cases are of similar origin, it will be well to lay hold of some character common to them all. One strikes us at once, and further investigation seems to show that it is the only one possessed by all. This common pathological change is the cirrhosis, which, with one [1] exception I have found present in all the cases I have investigated. Nor is it limited to the neighbourhood of the affected tubules and Malpighian bodies, but it is in evidence throughout the whole kidney substance.

We may therefore, I think, fairly conclude that the cirrhosis is an essential part of the disease, and that the changes in the secreting structures are, at least to some extent, due to, or it may be, result from the same cause as, the new connective tissue. This cause can hardly be other than something of the nature of an inflammation, and, for this to occur, some form of irritant must be acting. Further, it would seem that the changes which take place in the epithelium of the secreting structures interfered with may vary under different circumstances. What these circumstances are, we can only conjecture. It may be that when the fibrous tissue is formed first and chiefly in the medulla the cysts are more liable to form; as it spreads, it may perhaps lead

[1] See note, p. 240.

to secondary changes, perhaps diminution in the size of the cysts, and this may afford an explanation of the appearances found by M. Bar (34)[1] in his cases. Again, the site where the connective-tissue change commences, as well as the change undergone by the epithelium, may depend upon the particular agent at work, different poisons having perhaps different effects upon the epithelial structures.

That even gross obstruction to the escape of the urinary secretion may, rarely, lead to multiple cysts of the kidney is shown by a few recorded cases. Thus in Guy's Hospital Museum there is a large polycystic kidney with a renal calculus impacted in the upper end of the ureter. Seller (35) recorded two cases of such kidneys associated with traumatic obstruction; Littré (36), a case in which the urethra was congenitally obstructed. Mr. Bland-Sutton (25) mentions a remarkable case, in the fœtus, in which there was an imperforate urethra, dilated bladder, dilated left ureter, and a hydro-nephrotic left kidney. The right kidney had a small ureter and was a typical example of congenital cystic kidney. In such cases it would appear that the obstruction led to changes resulting in obliteration of the lumen of tubules draining into the calyces, and that cystic dilatation occurred behind.

Against the irritative or inflammatory theory of origin of the disease, Dr. Still (11) urges that in some cases it is expressly stated that the capsule was not adherent, as in his own. In such cases it is conceivable that the cirrhosis is chiefly in the medulla. Again, speaking of the congenital cases, he cannot believe "that in a kidney, which only reached its full development seven months before the child died, a nephritis could produce a fibrosis as extensive as that seen in an adult, who has suffered for years with chronic renal disease." In reply, I would suggest that we are not justified in judging of the effects of irritative causes upon embryonic tissues by their known effects on the same tissues when they have reached their full development. As instances of rapid fibrotic changes in such tissue may be

[1] M. Bar records three cases of polycystic kidneys in three successive children born of the same mother. In the first there was no sclerosis, in the third the sclerosis was very marked. The kidneys of the second child showed changes intermediate in degree. In the third child the abdominal walls were wrinkled as if the kidneys, primarily large, had become reduced in size under the influence of the sclerosis.

instanced, the condition of cardiac valves after intra-uterine endocarditis, and again the extensive changes in the liver at birth of some cases of congenital syphilis.

Granting, then, that the cystic disease of the kidneys is due to, and a part of, a cirrhotic change in the organs, the question arises, when does the process begin? Do the changes commence in all cases at the same time, or may they develop at any period of life?

Professor Virchow (30) held that all cases were congenital, the cysts growing less rapidly in those first recognised in adult life, than when it was found in the fœtus and new-born child. I have already ventured to suggest that the gap in the ages at which a fatal issue occurs is a remarkably long one, for if the fibrosis is due to inflammation, we might surely expect a progressive increase as life went on, and we can hardly believe that kidneys undergoing progressive cirrhotic changes could be able to perform their functions satisfactorily for forty, fifty, and even eighty years. He accounted for the fact that those cysts grew so large and thus differed so widely from those in the granular kidneys of adults, by assuming that the walls of the cyst formed in the fœtus possessed some latent power of developing later on. Such a condition can well be imagined; but that the isolated secreting structures should retain their functional activity for long is quite contrary to our knowledge of renal pathology. Yet in my case, as already pointed out, some of the glomeruli were only just becoming cystic and had still a part of the tuft functionally active, as shown by the condition of the capillaries and the deep staining of the nuclei of some of the cells over the base of the tuft.

On the other hand, if we grant that the change may commence at any period of life, we would anticipate that when the inflammation attacked fœtal tissues the disorganisation would be rapid and complete, leading to death *in utero*, or soon after birth. But when the fully-formed organs were invaded, we should expect the disease to commence at that period of life when fibrotic change is most common in the adult, and most insidious in its course. Hence the fact that, till near the end of life, the ordinary symptoms of kidney cirrhosis are less in evidence than usual would not prevent us from accepting this hypothesis, as it appears to Mr. Coats (29).

As a matter of fact there is one remarkable instance recorded which seems to strongly support the theory that cystic disease of the kidneys may, at least in some cases, commence in adult life. In this case (mentioned by Professor Osler [37]), a man, who died with huge polycystic kidneys, had his abdomen carefully overhauled three years before death in an examination for insurance, and was passed as having nothing abnormal present.

Before leaving this question of cystic disease of the kidney, it will be well to refer to the interesting fact that in a considerable number of these cases in infants, both with and without simultaneous changes in the liver, certain congenital abnormalities have been present. Thus horse-shoe kidney, cleft palate, hydrocephalus, meningocele, malformations of the urinary passages, polydactylism, have been recorded, and, as above mentioned, cystic kidneys have been found in an anencephalous fœtus. Dr. Still (11) welcomes these conditions as supporting his theory of congenital malformation, while Virchow (30) points to the association as a further instance of intra-uterine inflammatory changes. It may be noted in passing that similar abnormalities have not been noted in adults with this disease, if we may except the fact that cystic kidneys are stated to be unusually frequent among the insane, a statement which can only receive due consideration when the supposed cause of their insanity is known.

It certainly seems as likely that an intra-uterine inflammatory condition may cause simultaneous cirrhosis in one part, and arrested and abnormal development of another part of the fœtus, as that, because the mesonephros blends with the metanephros in the process of development, it is likely that an extra digit will be formed or an obstruction to the outflow of the cerebro-spinal fluid from the cerebrum take place.

It may be argued that the theory of inflammatory origin will only account for those cases in which the disease is bilateral, as it is hard to understand why one kidney should escape. Against this objection, I would bring forward the facts:

(1) That I have been unable to find any record of a case in which a microscopical examination of the second kidney was made and showed an absence of interstitial change.

(2) That in interstitial nephritis the disease is occasionally found very much more advanced in one organ than in the other.

(3) That cases are recorded in which one kidney has been excised for polycystic disease, after careful examination has shown the other to be apparently healthy, and yet within the year the latter has become greatly enlarged, and cystic, and caused death.

I would further suggest that it is possible that in some of these cases the interstitial change may act in one organ more as in ordinary chronic nephritis.

Cysts in other organs associated with cystic disease in the liver and kidneys.

Apart from the cystic conditions about the brain, such as hydrocephalus and meningocele already alluded to, I find that some writers refer to the presence of cyst in other organs. Thus Professor Osler (37) speaks of cysts having been found in the spleen and thyroid. Dr. Fitz (38) speaks of congenital cystic disease of the pancreas associated with cystic disease of the liver and kidneys, and Dr. Still (11) also mentions this lesion. None of these writers give references, and I have not been able to find any note of them in the reports of cases I have read, with the exception of Dr. Raymond Johnson's (39) case, in which he speaks of the presence of a caseous nodule in the spleen, microscopically very suggestive of a softened gumma. In one of my cases I mentioned that some small cysts were present on the internal surface of the spleen. We may therefore conclude that these appearances have only been found in isolated cases, for otherwise those who have had access to the reports could have hardly passed them over so lightly. Retention cysts are not uncommon in the thyroid, and are not very rare in the pancreas, so that it can hardly be considered remarkable that they should be found now and then along with cystic conditions in other organs. Probably it was a coincidence, but on the other hand it is quite conceivable that, where there was extensive fibrotic change in the liver and kidneys with cystic changes in the tubular parts, similar interstitial overgrowth might occur in other parts of the body. When such changes occurred in other glandular structures, containing alveoli and ducts, similar cysts might be expected to result.

The case is otherwise with the spleen. Here there are no

ducts and no alveoli, and cystic conditions are exceedingly rare.

With the exception of hydatids, dermoids, and blood cysts, the result of disease or injury of the vessels or blood spaces, the only cysts recorded are serous cysts on or near the surface of the organ. In such cases the capsule has been generally thickened and the cysts have been considered to take origin in either dilated lymphatic vessels or in some fragments of the peritoneal endothelium which have been included inside the thickened capsule and subsequently given rise to cystic spaces.

As already mentioned, a microscopical examination was not made upon the spleen in my case. As far as could be seen by the naked eye, the capsule was not much thickened, and the cysts were all apparently in or just beneath it. They were small and contained clear watery fluid. Macroscopically therefore no relationship could be traced between the condition of the spleen and that of the liver and kidneys.

Relationship between the cysts of the liver and kidneys.

In the first place, Is there any relationship at all? All the earlier writers considered the simultaneous condition as purely a coincidence, as was the opinion of Bristowe (12), Wilks (21), Pye-Smith (5), Frerichs (4). Dr. Kennedy (7), in discussing thirteen cases he had collected in 1890, hazarded a doubt as to whether a coincidence would be likely to occur so often. Dr. Ewan Frazer (17), in his paper on cystic kidneys, written within the last three or four years, says: "A considerable number of cases have been recorded where there have occurred, probably as a coincidence, cysts in the liver and the other organs."

The fact, however, that now more than forty cases of the associated lesions have been recorded, combined with our knowledge that cystic disease of the kidney is far from common, while multiple cysts of the liver apart from cystic kidneys are, with one doubtful exception, unknown, would seem to justify us in deciding that they are two different manifestations of one disease. Such is the opinion of Professor Osler (37), and Drs. Still (11) and Rolleston (8). According to Professor Osler (37), a similar condition is by

no means uncommon in the hog. It may be noted in passing, that this writer classes the cysts found in the combined lesion under a different category from those found in conglomerate cystic disease of the kidney alone, his "congenital cystic kidney," though he considers the former also congenital in origin. Other writers do not take this view, and unanimously seem to agree that there is no essential difference in the appearance of the kidneys, either macroscopically or microscopically, in the two cases.

Granting that there is a common cause for the diseased condition, there is much difference of opinion as to what that cause is. So far it has generally been assumed that the defect is a congenital one, and the details as to what the exact congenital fault may be, have in most of the accounts I have read been left over for further discussion. Dr. Still (11), however, has propounded an enticing and elaborate theory, which has been already more than once alluded to. He suggests that the only relationship between the two lesions is that both are the result of congenital malformation, and that the cysts are, in neither case, due to changes in normally existing secreting tissues of the organs. Instead, we have included remnants of embryonic tissues, which take on active properties and become converted into cysts. In the liver it is columns of cells with a central lumen, which have, so to speak, missed their vocation and not become converted into lobules and bile-ducts, and so become shut off in the substance of the otherwise rightly constructed liver. In the kidney, on the other hand, it is the Wolffian body that is at fault, and the mesonephros, instead of sinking into obscurity after its natural work is over, has become intricately blended with the metanephros in the construction of the kidney, and has later on assumed new vigour, become cystic, and gradually overwhelmed the natural secreting structures in its growth.

Against this theory, as has been already stated, it may be urged that there is no reasonable doubt, in many cases, that the cysts take origin from bile-ducts in the one organ, and from tubules and glomeruli in the other. Apart from this, however, it is hard to see what relationship there can be between the embryonic structures destined to form the kidneys and liver, which could bring about so remarkable a result as

that, in practically all cases in which the above-mentioned defect occurred in the liver, at least to any extent, there should be a blending of the mesonephros and the metanephros, and yet that in very many cases the latter malformation should occur without the liver being affected at all.

Failing this theory of malformation, there is seemingly nothing but a theory of some irritative or inflammatory lesion affecting both organs which can adequately account for the disease. Such lesion has so far been assumed to take place during intra-uterine life, and either develop rapidly, or remain practically in abeyance till late in life. Unfortunately those who support this theory are by no means definite in their statement as to what is meant by this latent power of forming cysts which is bestowed on certain of the structures of the liver and kidney. It would appear, however, that they hold some such view as that certain tubules, glomeruli and bile-ducts, become isolated and surrounded by connective tissue during fœtal life, and later on, usually in adult life, begin to proliferate and to form cysts. If this were so we should not expect any further active overgrowth of connective tissue, but merely a kind of progressive induration as pressure atrophy occurred, nor would we expect tubules, glomeruli, and bile-ducts, which had discharged their normal functions long after birth to, late in life, become endowed with similar properties to those possessed by the parts first affected. For one of the main objects of the theory of congenital origin was to account for the fact that the tubular structures, deprived of their natural outlet, develop into large cysts, rather than behave as in most cases of cirrhotic changes known to originate later in life, and simply atrophy, or, as in the microcystic kidneys of chronic nephritis, become converted into minute cysts. Hence the only changes we should expect such functionally active structures to undergo would be to atrophy from pressure and obstruction. Now, in Case 1 of my series—

(1) Both organs are in a condition of advanced and still advancing cirrhosis.

(2) In the liver many of the bile-ducts are in the early stages of cystic disease; they are surrounded by dense connective-tissue, and their epithelial lining is undergoing rapid prolifera-

tion, with colloid changes in the cells, while some of the larger cysts are lined with precisely similar epithelium, and have without doubt the same origin. In some parts new cysts are arising from among liver cells which are atrophying from pressure of the connective tissue.

(3) In the kidney many tubules and Malpighian bodies are just becoming cystic, and in some glomeruli the nuclei of some of the epithelial cells over the capillaries still stain, while the rest of the tuft has become converted into colloid material showing that the functions of the structure have been preserved till quite recently.

(4) The epithelial cells in the affected parts of both organs preserve their original form. Thus in the liver the cells of the ducts, though greatly enlarged, are still columnar, in most of the smaller cysts of the kidney apparently arising from tubules it is cubical, and in those formed from Malpighian bodies it is flattened.

From these appearances I venture to assert that in this case we are dealing with an irritative lesion in the liver and kidneys, which is in active progress and is leading to overgrowth of connective tissue and proliferative changes in the epithelium of both organs, and that the changes in the two organs are due to the same cause. Moreover the changes have been shown to differ widely from those which are usually found in congenital lesions, nor is it consistent with our knowledge of such lesions to believe that such a process, commencing *in utero*, and continuing in active progress, could have taken forty-two years to destroy life. Hence we may further conclude that the disease has in this case begun at some period after birth.

This is an important step in the pathology of the whole disease, for if one case has been proved to arise after birth there is no longer any need to assume a congenital origin for the other cases met with in adult life. On the other hand there is no need to assume that cases developed after birth have a different etiology from the congenital ones. There is so striking a resemblance between the microscopical appearances in the two forms, when allowance is made for the period of development of the two tissues, that it seems impossible to doubt that both are instances of the same disease.

What the irritating factor at work in these cases is, it is hard

to say. The observations of Dr. Ewan Frazer (17), already referred to in the discussion on the pathology of the liver, would seem to point to some micro-organism. In none of my cases, however, could any micro-organisms be discovered, though careful search was made for them in a large number of sections. Probably more than one toxic agent may produce the condition, and perhaps we may look to the differences in the nature of the poisons to account for minor differences in the pathological changes found. This may be why in one case we find vacuolisation of the liver-cells, in another clear serous cysts, and in a third a colloid change with marked proliferation of the epithelium.

Etiology.

This has been already largely dealt with, and it has been decided that as the result of some irritating material there is a chronic inflammatory change in the affected organs. Other subsidiary factors are—

Age.—The affection may commence *in utero,* but if not then seems not likely to occur much before middle life.

Sex.—The female sex seems to be much more liable than the male. Still (11) gives the proportion as three to one. In my cases there were three females to two males. This is interesting in view of the fact that cystic disease of the kidneys alone is said to be more frequent in males, the proportion being about three to two.

No causal relationship can be established with any other disease.

Symptoms.

The commencement of the disease is very insidious, and a large number of the cases have presented no indication of ill-health till shortly before death, which has most often resulted from uræmia. In very many the condition was only discovered *post mortem.*

In most of the cases diagnosed during life the symptoms have been referred to the kidneys. As a rule these have been somewhat the same as those commonly presented in chronic interstitial nephritis.

Polyuria has been noted in a few cases; in the majority the amount is not recorded. I can find no note of any great frequency or pain in micturition.

The urine has generally been pale, of a low specific gravity, about 1010, and acid or neutral.

Albuminuria has been present in the majority of the cases, though in a considerable number it has been recorded as absent. The amount of albumen is usually very slight, rarely rather considerable.

Pus was present in two of my own cases, but would appear to have been an accidental contamination due to pyelitis.

Casts, hyaline and granular, have been found, but have not often been looked for.

Hæmaturia is mentioned in a fair number of cases; it is usually intermittent and may be accompanied by colicky pains. In one case there was a history of the occasional presence of blood in the urine, extending over a period of twelve years.

Œdema and collections of fluid in serous cavities do not seem to be common, and when present are probably usually due to mechanical effects of the pressure. In my first case there was slight ascites.

Anæmia, weakness, and wasting are generally in evidence, and with the onset of the uræmic stage vomiting, distention, and constipation or diarrhœa may be found.

Mental disturbances were present in two of my cases, and in some others delirium and coma played a part in the final illness.

Increased arterial tension, arterial degeneration and hypertrophy of the heart have been noted in some instances. In several others it is expressly stated that there was no hypertrophy of the left ventricle. My own cases seemed to belong chiefly to the latter class. It may be that the poison has a local action on the affected organs in such cases, much as seems to be the case in a considerable number of cases of ordinary cirrhosis of the kidneys.

Local symptoms.—Often there have been none at all, so that quite large tumours have been overlooked during life. In other cases a swelling in one or both loins has been discovered quite by accident. A few of the patients have complained of an aching, dragging sensation in the back about the lumbar region. When a tumour is present it can be palpated in the loin, filling,

and extending more or less beyond, the kidney pouch. If there has been no perinephritic inflammation it can usually be moved about to some extent. It is liable to be rather tender, more so when there is secondary septic infection.

It may be hard and feel fairly regular, but more often has a tense semi-fluctuant "feel," with some slight irregularity of the surface. As a rule a swelling can be felt on each side, but sometimes it is unilateral.

Symptoms referable to the liver.—Usually there are none, and in only very few cases has the existence of the cysts been discovered before death. Jaundice has been almost invariably absent. In my case and in Dr. Budd's (2) it was apparently accidental and was due to gall-stones. A sallow, cachectic appearance is, however, very common, and Dr. Kennedy (7) found a slight icteric tinge on the conjunctiva; bile was not present in the urine, nor has it been recorded in any case except those above mentioned. In Dr. Kennedy's case (7) the patient, a woman, suffered for two months before death with symptoms pointing to deficient secretion of bile, "the fæces being pale and bad smelling." Theoretically there is no reason why the change in the liver should not be sufficiently advanced in some cases to cause symptoms. In such a case they might be expected to resemble those of the last stages of cirrhosis.

Where the cystic condition has been detected during life the organ has been found to be enlarged, and cystic swellings have been felt on the surface. In both cases in which I have palpated such a liver I was struck with the peculiar flaccid, not particularly tense impression they conveyed, which was very different from the "feel" of an ordinary hydatid cyst.

Diagnosis.

As in so many cases no symptoms are present it is not surprising that the correct diagnosis has but rarely been made during life. The diagnosis will largely depend upon the presence of the renal tumours. When with a sallow appearance, and urine of low specific gravity and containing a trace of albumen, a tumour is found in one or both kidney pouches, and the liver is enlarged with soft bosses on the surface, the diagnosis is fairly

certain. Without palpable enlargement of either organ it is impossible.

Rigors, high temperature and pyuria would make us suspect pyonephrosis, but are quite consistent with the disease, as is shown by two of my cases.

It is from hydatid disease that it is most important to differentiate. It is unlikely that hydatid would be present in both kidneys and the liver at one time. With hydatid of the kidney we should not expect urinary symptoms characteristic of chronic nephritis, and the swelling is likely to be more smooth and regular. If rupture occurs, cysts, scolices, and hooklets might be found in the urine. In the liver the hydatid forms a tense, rounded, regular swelling, rarely there may be more than one. In cystic disease, on the other hand, there are likely to be many soft, flaccid tumours of varying size, and the whole liver will be felt to be large and probably firmer than normal. When it is stated that apparently in only four or five of the cases a cystic condition of the liver has been diagnosed during life, and that in three of them an operation was performed under the idea that the cyst was hydatid, all being in Australia, it will be felt that here at any rate it is important to make a more accurate diagnosis. Two of the three died shortly after with uræmic symptoms, and the third probably only escaped a like fate from the fact that in her case the disease was unilateral. In all of them a correct diagnosis would probably have been made had the surgeon been prepared to deliberately discuss the possibility of cystic disease as one of the lesions to be excluded. For this reason I would advocate that in Australia, at any rate, steps should be taken to cause the disease to be better known amongst medical men. Many experienced practitioners to whom I have spoken on the subject have candidly confessed that they were not aware that such a disease existed. It should be an invariable rule in all cases where hydatid disease of the liver is suspected to carefully palpate the kidneys and to thoroughly examine the urine. Should any marked enlargement of the kidneys be present and the urine have a low specific gravity with or without a trace of albumen, an operation should not be lightly undertaken.

From malignant disease of the liver a diagnosis would be helped by the presence of the kidney tumours, though in my case (1) the masses (palpated with difficulty in a tender, swollen

abdomen, containing free fluid) were taken for huge secondary deposits in the retroperitoneal glands.

Prognosis.

This will chiefly depend upon the kidney disease, and the stage at which the patient comes under notice, as also on the rate of progress of the cystic change. When both kidneys are much enlarged the most that can be hoped for is prolongation of life for a year or two. Most cases have died soon after they have come under observation. When only one kidney is apparently involved the prospect is much more hopeful, and my third case is an instance where life has continued for three years after one kidney had been excised and a cyst of the liver opened. Death is usually attributable to uræmia, and this may be precipitated by anything that will upset the unstable equilibrium maintained by the damaged kidneys. Thus pneumonia, a drinking bout, an accident, undergoing an operation, have on different occasions been determining causes.

Treatment.

The results of surgery so far would seem to show that when both kidneys are affected no good can be anticipated from an operation. Where only one kidney is involved and it is giving much trouble, either from its size or, as in my third case, owing to a secondary septic infection, nephrectomy seems to be a fairly hopeful operation, and this view seems to be borne out by the results of surgery in the case of polycystic disease of the kidneys alone.

In the case of the liver, operative interference could only be justified by extreme magnitude of the cyst or by some complication. Hence the importance of a correct diagnosis from hydatids where early operation is so strongly indicated, and has such excellent results.

Medically the treatment will be such as is indicated in chronic interstitial nephritis, our aim being to avoid all strain upon the kidneys, such as is due to exposure, chills, ingestion of irritating materials, etc., to keep the other excretory channels acting freely, select the diet judiciously, and generally throw as little work on the damaged organs as possible.

REFERENCES.

1. *Reid.*—'Intercolon. Med. Journ.,' vol. i, p. 90.
2. *Budd.*—'Diseases of the Liver,' New Syd. Soc.
3. *Rokitansky.*—'Path. Anat.,' Bd. ii, S. 263.
4. *Frerichs.*—'Diseases of the Liver,' Dr. Murchison's translation, vol. ii, p. 223.
5. *Pye-Smith.*—'Trans. Path. Soc. Lond.,' vol. xxxii, p. 112.
6. *Bristowe.*—Ibid., vol. vii, p. 229.
7. *Kennedy.*—'Lab. Reports Royal Coll. Phys. Edin.,' vol. iv, p. 177.
8. *Rolleston.*—"Cysts of the Liver," 'Encyclopædia Medica.'
9. *Rindfleisch.*—'Path. Histology,' New. Syd. Soc.
10. *Paterson.*—'B. M. Journal,' 1890, vol. ii, p. 735.
11. *Still.*—'Trans. Path. Soc. Lond.,' vol. xlix, p. 155.
12. *Bristowe.*—Ibid., vol. x, p. 174.
13. *Kanthack and Rolleston.*—'Virch. Archiv,' B. 130, S. 488.
14. *Hale White.*—'Trans. Path. Soc. Lond.,' vol. xxiv, p. 1.
15. *Sabourin.*—'Archiv. de Physiol.,' Paris, 1882, second series, vol. x, pp. 63, 213.
16. *Dmochowski u. Janowski.*—'Beitr. z. path. anat.,' Jena, xi.
17. *Ewan Fraser.*—'Report on two Cases of Cystic Disease of Kidneys.'
18. *Sims Woodhead.*—'Practical Pathology,' p. 286.
19. *Cornil and Ranvier.*—'Manuel d'Histologie Pathologique.'
20. *Henry Morris.*—'Surgical Disease of Kidney and Ureter,' vol. i, p. 646.
21. *Wilks.*—'Trans. Path. Soc. Lond.,' vol. vii, p. 235.
22. *Hare.*—Ibid., vol. iii, p. 131.
23. *James Ritchie.*—'Lab. Rep. of Royal Coll. Phys. Edin.,' vol. iv.
24. *Shattock.*—'Trans. Path. Soc. Lond.,' vol. xxxvii, p. 287.
25. *Bland-Sutton.*—'Tumours, Innocent and Malignant,' p. 476.
26. *W. Edmunds.*—'Trans. Path. Soc. Lond.,' vol. xliii.
27. *Thoma.*—Reference not given by Dr. Ewan Frazer (17).
28. *Bard of Lyons.*—Reference not given by Mr. Henry Morris (20).
29. *Coats.*—'Manual of Pathology,' p. 975.
30. *Virchow.*—Paper entitled 'Ueber Congenitale Nierenwassersucht.'
31. *Beckmann.*—'Virch. Archiv.,' vol. ix, p. 221.
32. *Klein.*—Ibid., vol. xxxvii, p. 504.
33. *Ranvier.*—'Journ. de l'anat. et phys.,' Paris, vol. iv, p. 445.
34. *Bar.*—Ann. des maladies des org. genito urinaires,' Juillet, 1899, p. 723.
35. *Soller.*—'Lyon Medicale,' vol. xxxv, p. 333.
36. *Littré.*—'Mem. de l'Acad. des Sciences Ann.,' 1705, p. 3.
37. *Osler.*—'Principles and Practice of Medicine,' p. 898.
38. *Fitz.*—Allbutt's 'System of Medicine,' vol. iv, p. 274.
39. *Raymond Johnson.*—'Trans. Path. Soc. Lond.,' vol. xlix, p. 165.

Other cases not referred to in this article.

40. *Mahomed.*—'Trans. Path. Soc. Lond.,' xxxiv, p. 182.
41. *Michalowics.*—'Dégénérescence Kystique des reins et du fois,' Paris, 1877.
42. *Courbis.*—'Kystes du fois et des reins,' Paris, 1877.
43. *Nauwerck u. Hufschmid.*—'Beitr. z. path. anat.,' Jena, xii, p. 9.

44. *Caresme.*—'Bull. de la Soc. anat. de Paris,' vol. xl, p. 133.
45. *Chantreuil.*—Ibid., vol. xlii, p. 439.
46. *Jaffroy.*—Ibid., vol. xliii, p. 231.
47. *Komorowski.*—Ibid., vol. li, p. 12.
48. *Chambord.*—Ibid., vol. liv, p. 614.
49. *Babinsky.*—Ibid., vol. lviii, p. 341.
50. *Demanké.*—Ibid., vol. lxix, p. 323.
51. *Claude.*—Ibid., vol. lxxi, p. 109.

May, 1904.

21. *An anatomical criticism of the procedure known as total prostatectomy.*[1]

By Cuthbert S. Wallace.

De opere chirurgico, prostatectomiâ totâ ut dicitur, anatomice discusso.

Summarium.

Prostatis pluribus perauctis indagatis, reperitur augmen naturæ esse adenomatosæ.

Hoc augmen adenomatosum aut partes modo quasdam aut glandulam totam implicat.

In prostatectomiâ pars prostatæ extrema semper, ut credo, superest, et in corpore ægri relinquitur.

Hoc ego præcipue conjecto opere chirurgico indagando quod post mortem adversus prostatam prægrandem confectum est.

In operatione ita confecta, lacuna ex quâ prostata ablata est reperitur parietem habere definitam quam scrutatio microscopica lacunas glandulares continere demonstrat.

Hæc paries ergo constare debet ex parte prostatæ extremâ super molem augescentem attenuatâ.

Si hujus parietis sive capsulæ lamina interior in operando aufertur, tunc apparet moles tegmine fasciculato circumtecta: si hujus capsulæ nihil aufertur apparet moles ablata tuberosa aut lobulata.

Evenit, igitur, ut in hac operatione neque ad fasciam rectovesicalem nec ad venarum plexum prostaticum attingit chirurgi digitus.

Hæc capsula repræsentat plus quam tegmen fibro-

[1] A previous paper by the author on the same subject appeared in the 'British Medical Journal' of March 29th, 1902, p. 764.

musculare normale quod Shattock "corticem" prostatæ appellavit; atque appellari potest, ut opinor, "capsula chirurgica."

Figuræ 42, 43, 44 hæc quæ hic contendo demonstrant. Hanc conclusionem confirmavit scrutatio microscopia partium relictarum in ægro quodam post prostatectomiam (totam, ut dicitur) mortuo, scrutatione a Thomson Walker confectâ ('Transactions of the Royal Medical and Chirurgical Society,' vol. lxxxvii).

Post mortem repertum est adenoma minutum in parte "capsulæ" anteriore in cadavere relictâ.

Etiam si fasciculi musculares striati in "capsulâ" quæ glandulam ablatam circumdat inveniantur, hoc probare haud sufficit prostatectomiam esse totam. Fasciculi enim tales inter glandulæ normalis acinos extremos pertendunt, qui fasciculi e musculo ab Henle descripto oriuntur (*vide* Figs. 58, 59.)

In casibus singulis, igitur, ut probetur prostatectomia histologice esse tota, demonstrare necesse est telam glandularem a partibus relictis in cadavere abesse.

The Normal Prostate.

A short description of the normal prostate is necessary in order to make one or two points of comparison with the organ in its diseased state.

Fig. 36 shows the appearances of a section of an adult prostate taken at right angles to the urethra; it has been enlarged by half so as to show the arrangement of the glandular and fibrous portions. There is no indication of any division into lobes. The fibro-muscular tissue is most marked in the following situations: (1) At the circumferential portion of the gland, where there is an absence of gland tissue; (2) behind the urethra, from which place it radiates in all directions to join the outer non-glandular area; (3) in front of the urethra, where it forms the so-called anterior commissure.

The gland tissue is fairly evenly distributed in the posterior part of the gland, both at the sides of and behind the urethra. The amount of gland tissue behind the urethra varies very much in different specimens, as has been pointed out by Griffiths. This variation has an influence on the type of enlargement, as will be pointed out later in this communication.

Outside the non-glandular area is the fibrous covering of the organ, which is derived from the recto-vesical fascia. This covering is not a dense definite structure, as is the fascia lata of the thigh or the arm, but consists of a series of areolar planes in which on the lateral and anterior aspects is embedded the prostatic plexus of veins. It is a structure in which extravasation

FIG. 36. (Enlarged by one-half.)

of fluid could take place, and would form the wall of the cavity left if a prostate were completely ablated.

In speaking of prostatectomy and of the presence or absence of a "capsule" it is very necessary to define the terms used.

The term "sheath" as used by Sir H. Thompson is the fibrous covering derived from the recto-vesical fascia, and contains the venous plexus. The term "capsule" as used by the same observer is the thin outer non-glandular portion of the organ, and is really only the outer portion of the stroma of the organ; it contains both muscular and fibrous tissue.

In 'Quain's Anatomy' the term "fibrous capsule" is used to express the fibrous sheath derived from the recto-vesical fascia. There is no "capsule" in the sense of a separable membrane such as invests the kidney, nor can the prostate be shelled out from its surroundings like a lymphatic gland or the thyroid body.

Mr. Shattock has suggested that the outer non-glandular

portion of the organ be termed the "cortex," which title seems to adequately represent the facts.

I propose, then, that the investment from the recto-vesical fascia be called the "sheath," and that the outer part of the gland proper be called the "cortex."

Let us now study the organ in its pathological state:

Fig. 37 represents a specimen that I removed by the so-called operation of total prostatectomy. It was taken from a man, J. M., aged 77 years, who had suffered from complete retention for six years. The intra-vesical projection was circular, and of

FIG. 37.

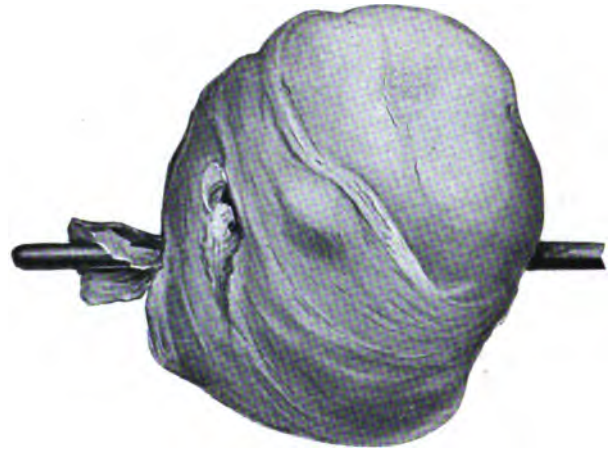

a character that I ventured to compare with the projection of the uterus into the vagina, and to which I shall refer hereafter as the "os uteri" type of projection. The weight of the specimen was 152 grams (4¼ oz.). The so-called "capsule" is seen to be composed of transversely-coursing bundles. The upper or vesical part of the specimen is smooth and rounded. Connected with the inferior part of the gland is a torn portion of the membranous urethra, which projects 13 mm. and partially surrounds the catheter which has been passed through the canal. The prostatic urethra is intact within the tumour.

Fig. 38 is a cross section of the same made through the middle of the organ at right angles to the axis of the urethra. It shows that the adenomatous tissue has practically surrounded the slit-like urethra, the wall of which is very thin and could not be

separated from the adenomatous mass without rupture. At the circumference of the specimen and completely surrounding it

FIG. 38.

can be seen the thin so-called "capsule." This may be considered a typical example of the parts removed by the so-called total prostatectomy.

FIG. 39.

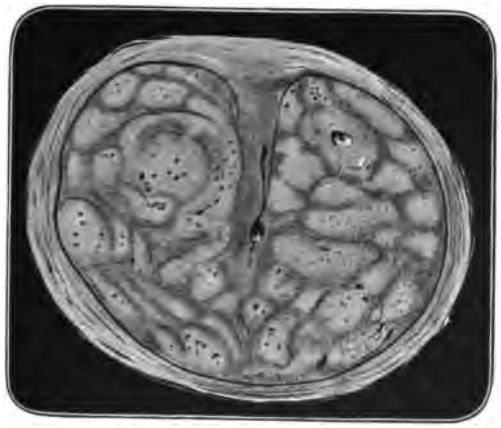

With this specimen compare the following, obtained after death:

Fig. 39 represents a section at right angles to the urethra of the prostate of a man, H. H., aged 60 years, who was admitted

for the impaction of a stone at the junction of the prostatic and membranous urethra. The stone was removed by supra-lithotomy. The patient died suddenly on the fourth day after operation. After death the prostate and bladder were removed from the body, hardened in alcohol, and examined by means of sections cut at right angles to the urethra.

FIG. 40.

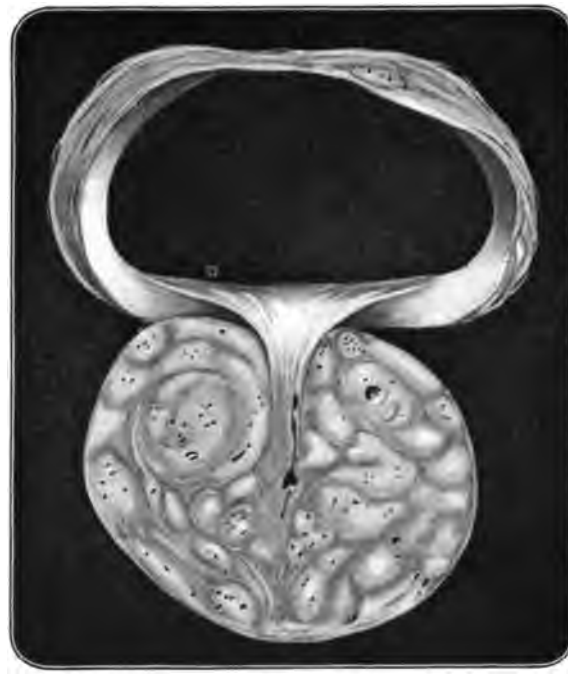

The projection of the prostate into the bladder was of the "os uteri" type. The "posterior lip" was more prominent than the anterior. The whole organ viewed from the outside forms a globular swelling without any indications of division into lobes. The greatest transverse diameter measures 6 cm.; the urethra along its length also measures 6 cm. The cut surfaces show a distinct envelope, and within this a glandular mass. The average thickness of the envelope is 0·3 cm. It is an exceedingly definite structure, and is distinctly laminated to such a marked degree that it admits of artificial cleavage for considerable distances along its lamellæ.

In the section taken through the centre of the enlargement the urethra is a vertical slit measuring 1·5 cm., and lies 2 cm. from the posterior and 1·5 cm. from the anterior border of the organ. The glandular substance is arranged in somewhat ill-defined lobules, absent on the anterior aspect of the urethra. In the last-named situation there is a septum of fibrous or fibro-

FIG. 41.

muscular tissue surrounding the urethra, and continuous above or in front with the "envelope." Towards the inferior or distal end of the organ this fibrous septum is less distinct, being broken up by processes of gland tissue.

The median projection behind the urethral orifice is shown on a transverse section, carried through this part, to be inseparably continuous with the lateral portions.

Fig. 40 shows the separation between the envelope and the

glandular portion. The central mass containing the urethra has been shelled out from the "envelope." This can be repeated in every section of the organ, so that ultimately the organ is divided into two parts, namely, the "envelope" and a contained glandular mass, in which lies the urethra, the only line of continuity between the two being the thick anterior fibrous septum, which is continued in from the "envelope" to join the peri-urethral tissue.

I think that no one can fail to be struck with the similarity of these two specimens (Figs. 38 and 39), the first obtained as the result of a surgical procedure, the other in the *post-mortem* room. The only difference is the thickness of the surrounding envelope; the central portions are identical; in fact, they appear to represent the same pathological change in different individuals.

In the specimen removed in the *post-mortem* room, the nature of the envelope can be studied. Now, this contains gland matter, as shown by the lenticular mass seen in Fig. 40, and by the fact that a microscopic section taken at a point which is entirely fibro-muscular to the naked eye reveals the presence of flattened gland spaces (Fig. 41). This envelope therefore represents more than the outer non-glandular part of the organ. It can be studied further in Fig. 42.

This figure represents the bladder and enlarged prostate taken after death from a man, F. H—, aged 83 years, who died of uræmia. The front of the bladder and of the prostate has been removed by a coronal section.

The two lateral adenomatous masses have been removed by digital separation, which was accomplished without any difficulty. The left of these masses has been replaced, but the line of its separation is indicated in the drawing. The lateral wall of the urethra was closely adherent and removed with it. It will be seen that there is a medium ridge left after the removal of the lateral masses; this is the posterior wall of the urethra, and is still covered with mucous membrane. At the summit of the ridge and projecting into the bladder in the position of the uvula vesicae is a small rounded eminence formed by a small adenoma. The walls of the bilocular cavity left after the removal of the lateral adenomatous masses have a very considerable thickness. This is especially the case behind the urethra on both sides, as seen in the lowest portion of the drawing.

FIG. 42.

EXPLICATIO FIGURÆ.

Vesica una cum prostatâ perauctâ viri annorum 83, post-mortem ablata. Ex parte dextrâ enucleata est moles prostatæ adenomatosa; capsula ex telâ fibromusculari ac glandulari constans superest. Molis ablatæ superficies teres atque tuberosa erat.

On the left side behind will be seen a portion of the prostatic plexus of veins. A further examination of the specimen showed that the walls left after the ablation of the lateral masses were capable of a further division. With the finger and a blunt

FIG. 43.

EXPLICATIO FIGURÆ.

Specimen idem. Moles adenomatosa tota enucleata est; insuper autem capsula diffissa est, laminâ extremâ solum relictâ. (*Vide* figuram sequentem.)

dissector the division was carried out until the part of the envelope immediately surrounding the lateral masses was completely isolated. The result of this isolation is shown in Figs. 43, 44.

With this portion of the envelope has come away the posterior

wall of the urethra, and with it, of necessity, the terminal portions of the ejaculatory ducts. This shell or envelope shows naked-eye evidences of gland tissue, for it contains the adenoma at the uvula vesicæ; and a microscopic section of the envelope taken from the right side, where only fibrous tissue is visible to the naked eye, reveals the presence of flattened gland spaces lined with columnar epithelium (Fig. 45).

FIG. 44.

EXPLICATIO FIGURÆ.

Monstratur capsulæ lamina interna e specimine præcedente extracta.

The outer surface of the envelope shows circularly coursing bundles of fibres. A drawing of these fibres has not been made, but a reverse of the outer surface can be seen in Fig. 43, which represents the parts after the removal of the envelope described. The wall of the now unilocular cavity left by the removal of the adenomata and of the envelope is still a definite structure, and has an appreciable thickness even at its thinnest part, while behind it measures 0·6 cm. in plane of section. The texture at this spot is spongy, and a microscopic section shows the presence of a considerable amount of flattened gland tissue which is not much altered from the normal (Fig. 46).

Still more externally can be seen the prostatic plexus. If the two adenomatous masses were replaced in their envelope, it would be seen that the whole would resemble the parts that are often

FIG. 45.

EXPLICATIO FIGURÆ.

Sectio microscopia laminæ in figurâ præcedenti monstratæ. Lacunæ glandulares eam ex telâ prostaticâ constare probant.

FIG. 46.

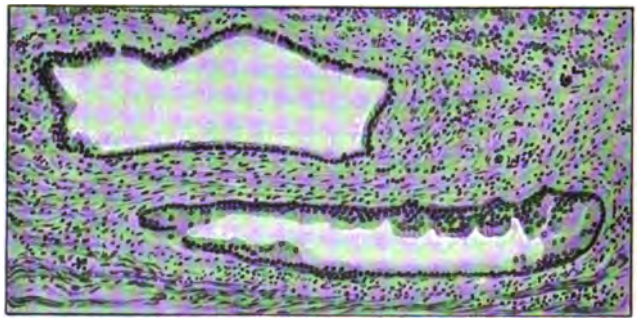

EXPLICATIO FIGURÆ.

Sectio microscopica laminæ extremæ in prostatectomiâ relictæ. Lacunæ glandulares eam ex parte prostatæ extremâ constare demonstrant.

removed in the so-called total prostatectomy, namely, two lateral adenomatous masses encompassed by an envelope that is most strongly marked at the equator of the mass, and presenting transversely coursing fibres.

The two specimens removed after death show that the enlargement of the prostate consisted of adenomatous masses enclosed in an envelope, the urethra being so closely adherent to the adenomata that its separation for any extent was impossible without laceration. The development of the adenomata and envelope will now be traced.

The Growth of the Adenomata and the Formation of the "Capsule."

The first indication of a change in the prostate in the process of enlargement is seen in the altered relations between the fibro-muscular and glandular portions. Small white areas become visible, and tend to assume a rounded outline. These

Fig. 47.

areas may be single or arranged in groups. At the same time the arrangement of the fibrous tissue is altered. It no longer runs out in straight lines from behind the urethra, but the strands take a wavy course, and arrange themselves round the growing glandular masses. There can often be seen in the same specimen normal prostatic tissue areas showing whitish spots, ill-defined lobulated masses.

As time goes on the normal gland tissue becomes less and less

obvious, disappears from the centre of the organ, and is only seen at the periphery of the organ. The whitish areas increase in size, and become recognisable as adenomatous masses, and as seen in the preceding specimen.

Fig. 47 gives a view of an enlarged prostate removed by the author.

A bristle has been passed through the urethra. The mass is bilobed. Anteriorly it is circularly ridged, the rest of the surface, with the exception of one area, being slightly rough. The area referred to is that shown towards the upper part of the drawing on the right lateral lobe. This represents the exterior of the most posterior part of the glandular mass shown in the

FIG. 48.

right-hand side of the section in Fig. 48. The anterior end of the urethra lies on the right-hand side of the drawing.

Fig. 48 represents a transverse section of the specimen shown in Fig. 47. The urethra is triradiate, the long arm being the anterior. The divided surface presents several areas of glandular tissue; these show a tendency to form compound circumscribed masses.

The more rapidly growing areas increase at the expense of the more slowly growing ones, which are compressed and stretched over the surface of their more quickly growing neighbours. The tissue between the adenomata, composed partly of the fibro-muscular septa of the normal organ and partly of the stretched prostatic tissue, becomes circularly disposed round the gland masses (Fig. 49).

The adenomata may be either single or compound; that is to say, they may be composed of several adenomata bound together

by one common envelope, or one adenoma may contain two or more smaller ones.

By the time that the adenomatous changes have become well marked the external form of the organ has undergone a change. The antero-posterior measurement approaches, then equals, the lateral, so that the organ not infrequently becomes globular in

FIG. 49.

outline, and its cross section circular instead of being transversely elongated.

There does not appear to be any definite relation between the size of the organ and the progress of the adenomatous change.

This is well shown if Figs. 37 and 38, representing a specimen weighing 150 grams and having an antero-posterior measurement of 5·5 cm., are compared with Figs. 50 and 51, representing a specimen weighing 20 grams (5 drachms) with an antero-posterior measurement of 3·5 cm. In fact, the second specimen is a miniature of the first.

The latter was removed by the author from a man, L. C—, aged 65, who was admitted to St. Thomas's Hospital in August, 1903, with a dribbling retention. Its weight was 20·4 grams

(5 drachms). It is hardly, if at all, larger than the normal organ. The appearances are those usually presented by the specimens removed by the so-called total prostatectomy.

FIG. 50.

The view is that of the anterior surface, and shows the transversely coursing bundles of fibro-muscular tissue. Above and projecting beyond the rough transverse fibres are seen the smooth rounded eminences of the lateral glandular masses. Below are the portions of the torn membranous urethra, the longest of which measures 2 cm. The catheter is placed in the urethra, the wall of which has been removed with the tumour.

FIG. 51.



Fig. 51 represents a transverse section of Fig. 50. The adenomatous growth is situated at the sides of the deepened slit-like urethra. In front and behind there is no abnormal growth of gland tissue. On the circumference of the specimen

can be seen the laminate envelope, which differs in thickness in different parts. No part of the prostatic plexus of veins has been removed.

FIG. 52.

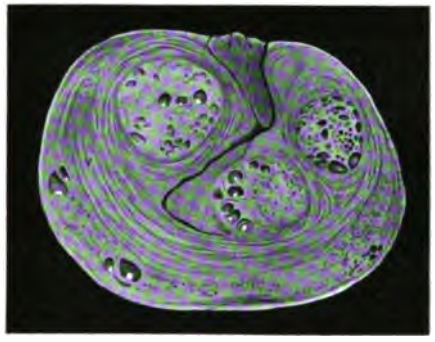

From the disposition of the gland tissue in the normal prostate it follows that the adenomata can develop in any situation round the urethra except immediately in front of the canal, where lies the anterior commissure. If the adenomatous change starts in

FIG. 53.

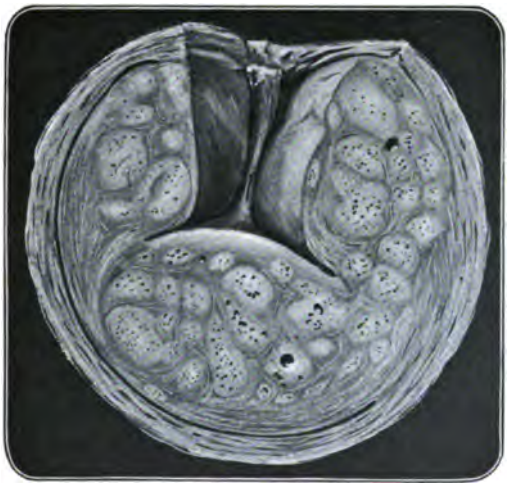

either side of the urethra it will form lateral masses of adenomatous tissue. On the other hand, should the change affect all the glandular portion of the organ alike, the growth will surround the urethra everywhere except the front and even

here by its growth may eventually displace the fibro-muscular anterior commissure. The projection of the gland into the bladder will in this case be equal round the whole circumference of the urethra, or in other words the projection will be of the "os uteri" type.

Should the adenomata, however, develop more rapidly in the portion of the gland behind the urethra and above the ejaculatory ducts, there will be formed what has been called a median lobe, but this is as a matter of fact always continuous with one lateral mass as shown in Fig. 52, or with both, as in Fig. 53.

If situated near a free surface, the adenomata grow in the direction of least resistance, and form the nodular masses so often met with on the vesical surface of the prostate or in the interior of the prostatic urethra. This can be seen in specimens Nos. 4331 and 4340 A in the Museum of the Royal College of Surgeons; a short account of these specimens is inserted here.

No. 4331, *Royal College of Surgeons.*—"The prostate is generally enlarged, and the parts that project into the bladder and urethra are irregularly knobbed. Part of the right lobe projects as a short thick nipple-like process into the neck of the bladder in front of the enlarged middle lobe. Part of the left lobe projects as a broad, but rather flattened, process into the urethra directly over the caput gallinaginis, so as to be in contact with the opposite wall. The middle lobe forms a deep and broad transverse and trilobed ridge across the neck of the bladder." The patient was aged 70 years. A vertical, almost transverse, section along the course of the urethra shows the following points: On the urethral aspect it presents three rounded eminences which correspond with the same number of imperfectly circumscribed adenomata. External to these there lies a thin layer of more or less normal spongy prostatic tissue, and beyond this, without any line of separation, lies the prostatic plexus. The section of the right lateral lobe shows the nipple-like process to be separated from the main mass by a fibrous septum. The rest of the mass presents two adenomatous foci; elsewhere it is spongy, but for the most part less so than the normal gland. The outer surface of the lateral lobe can be separated from the muscular and fibrous tissue enveloping it; the surface of the envelope thus raised is transversely striated from the presence of muscular fibre.

No. 4340A, *Royal College of Surgeons,* shows a similar condition in which the adenomatous enlargement occupies a median position behind the urethral orifice. Microscopic sections taken from these adenomatous areas show, besides a fibro-muscular stroma, a large proportion of gland tissue.

To recapitulate, it may be said that the increase in the organ is due in the first instance to an increase in the glandular elements. This growth usually affects the greater part of the organ, but often leaves small portions almost unaltered. Within the changed area the alteration of the glandular element may be of very varying degree, consisting in some cases of small discrete points, while in others well-marked adenomatous nodules occur. These adenomata are often, indeed usually, compound, and may occupy the whole space within the "envelope" (Figs. 38 and 39). The overgrowth of the prostate in these cases is therefore best described as an adenomatous hypertrophy, and is comparable to the adenomatous form of goître.

In order to ascertain the changes that occur in enlargement of the prostate many specimens have been examined, and in nearly every instance the changes described above have been seen. There are, however, other forms, such as the fibroid and carcinomatous, with which this paper does not deal.

The formation of the so-called "capsule" proceeds *pari passu* with growth of the adenomata.

This specimen (Fig. 54) was obtained after death from a man, E. S—, aged 63, who died of a duodenal ulcer. There was no

FIG. 54.

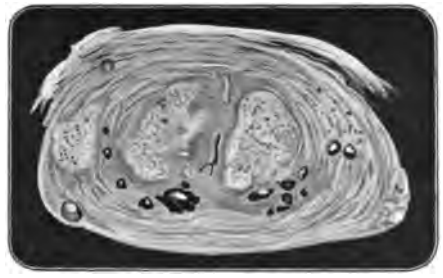

history of prostatic trouble. The section shown in the drawing was taken at right angles to the urethra and through the middle of the organ. Above can be seen the recto-vesical fascia. In the

centre is shown the prostatic urethra, somewhat distorted. On either side, though not in actual contact with it, are two commencing adenomatous masses. Surrounding the two central masses can be seen the outer part of the organ. The fibres have already taken on a circumferential direction, and except at one place to the left of the urethra, where an adenomatous mass is visible, no gland tissue is discernible to the naked eye, though its presence is indicated by the occurrence of numerous prostatic calculi. It will be seen that an increase in the size of the central adenomata would have in time led to the condition seen in Fig. 40, namely, a central adenomatous mass surrounding the urethra, accompanied by an envelope containing at one spot a mass of gland tissue. The rapidly growing gland tissue

FIG. 55.

No. 4312, Royal College of Surgeons.

stretches and expands the circumjacent tissue over and around itself. The radiating fibro-muscular bands lose their original disposition and run in a wavy course between the adenomata. The normally diffuse, spongy nature of the gland is lost. As the adenomata grow the circumferential part of the organ comes to be laminated, the fibres being driven to take a more or less circular course when seen in a cross section of the organ (Fig. 55).

In this specimen, which is in the museum of the Royal College of Surgeons, and which was taken from the body after death, the centre of the lateral mass of the prostate is occupied by an adenoma; around it can be seen the remnants of normal gland tissue, the stroma being concentrically arranged. Outside, again, can be seen the plexus of veins embedded in the recto-vesical fascia. This is a fairly early stage, but it can be seen that with

the growth of the adenoma the circumferential tissue would be more and more thinned and come to resemble the envelope seen in Figs. 38 and 39.

The urethra, as seen in cross section, is at first crescent-shaped. It next becomes triradiate (Fig. 48), the radii being placed one anteriorly and two laterally. The next change is the disappearance of the lateral radii and the elongation of the anterior until the urethra is a simple slit. If both lobes develop at the same rate, the urethra in cross section will be linear, but if one lateral lobe increases disproportionately to the other, the canal will be correspondingly curved.

Not only is the prostatic urethra increased as measured along the catheter, but it is considerably increased in the antero-posterior plane, as can be well seen in Figs. 38 and 51. Even if the adenomata first show themselves towards the middle of the lateral masses, they soon come into close relation with the urethra, and lie immediately alongside the walls of the canal.

The increase in dimensions of the urethra both in length and in the antero-posterior plane caused by the growth of the adenomata leads to a thinning and stretching of the urethral wall, so that in most specimens examined the urethra is represented by a mucous membrane so thin and delicate that it cannot be raised for any distance from the surface of the adenomata without rupture. This necessarily leads to a removal of the urethra on the adenomata. Whether the adenomata are removed singly or as one mass in a surgical "envelope," the mucous membrane is demonstrable on their inner surfaces, though its thinned condition makes this a matter of some difficulty unless a microscopic section is cut.

The tags of urethra that are seen to project from the inferior extremity of the specimens (Figs. 37 and 50) obtained by the so-called total prostatectomy are really derived from the membranous portion of the canal, and their continuity with the prostatic urethra within the tumour can be traced.

Enucleation of the Adenomata and the so-called Total Prostatectomy.

I think that it can easily be shown that the nature and appearance of the parts removed depends on two factors—

1. The situation and extent of the adenomatous change.

2. The point at which the finger enters and cleaves the envelope.

It has been shown that the glandular portion of the prostate represented in Fig. 39 could be shelled out from the envelope. If the separation were carried out over the entire organ as it has been done in the section shown in Fig. 40, there would have been removed a glandular mass containing the urethra, the surface of which would have been smooth and somewhat nodular; in other words, it would have resembled the surface of the adenoma. Now the envelope is laminated, and can be split in any part of its thickness. If the finger had entered in the middle of the cut surface of the envelope, as shown in the section, the adenomatous mass would have come out surrounded with an envelope, the fibres of which would have formed circularly-disposed bundles, and the surface would have resembled that seen in the specimen represented in Figs. 37 and 50.

The amount of capsule removed with such a tumour will then simply depend on the thickness of the envelope and depth to which the finger happens to have been penetrated in the process of enucleation. Figs. 42–44 demonstrate that in such an enlarged prostate as this each adenoma could have been removed separately provided that the finger had reached to the surface of the adenomatous masses. If the finger penetrated less deeply and entered the envelope, the parts removed would have consisted of two lateral adenomatous masses bound together by the innermost layers of the envelope.

By the help of specimens removed from the dead body, the growth of the adenomata, the formation of a definite laminated envelope, and the alteration in the shape and environment of the urethra have been traced. It has been shown that the glandular masses surrounded by the innermost layers of the envelope enucleated from the parts removed after death correspond accurately to those removed by the so-called total prostatectomy in the living subject. It must be concluded, therefore, that the parts left behind in these two procedures correspond.

Now, in the case of the parts removed after death, after a removal such as that just described, there is left behind a definite envelope. This envelope has been shown to contain glandular tissue, and therefore to have been formed by the periphery of

the organ, and to represent more than the outer non-glandular cortex of the prostate. External to this envelope the prostatic plexus has been shown to lie. It therefore follows that after the so-called total prostatectomy an envelope formed of expanded prostatic tissue is doubtless left behind, and bounds the cavity formed by the removal of the tumour. From a study of these facts, corroborated by others not referred to for want of space, the following conclusions may, I think, be drawn:

Conclusions.

1. That the usual form of prostatic enlargement is an adenomatous one.

2. That the adenomatous tissue may surround the urethra or form masses, in the lateral parts of the organ, behind the urethra, or in all three positions.

3. That the parts removed may consist of adenomatous masses from the lateral parts, or of an adenomatous formation more or less completely surrounding the urethra.

4. That there is always left behind a definite laminated envelope containing glandular tissue, derived from the expanded outer portion of the organ.

5. That the amount of envelope left on the surface of the tumour after removal depends on the depth at which the enucleating finger cleaves the envelope.

6. That the recto-vesical is not opened, nor the prostatic plexus of veins injured.

7. That though it is impossible to remove a small adenoma from the centre of the lateral part of the prostate without extensively injuring the urethra, yet this canal is removed *in toto* when the adenomatous growths are extirpated in their envelope, and the lateral walls come away adhering to the adenomata when these are of any considerable size.

I would, in conclusion, suggest that the term "surgical capsule" should be applied to the envelope formed from the prostate by the expansion of the adenomata. It is a pathological formation, and represents more than the outer non-glandular portion, to which Mr. Shattock has given the name "cortex." To its presence is due the small amount of bleeding and the absence of urinary extravasation. Indeed, in the so-called total prostatec-

tomy the enucleating finger never passes outside the limits of the prostate, and therefore cannot enter the recto-vesical fascia or tear the prostatic plexus of veins.[1]

Since the above was written the following case has come to hand.

The specimen shown in Figs. 56 and 57 was obtained from R. O—, a male, aged 81 years, who was admitted to St. Thomas's

Fig. 56 (slightly reduced).



Hospital in November, 1903, suffering from retention of urine. The bladder had been twice opened for retention. The patient was extremely ill, and beyond giving relief by a third suprapubic opening, nothing was done. Death followed in a few hours.

[1] All the figures illustrating the paper are drawn to the natural size except in the case of figures 36, 56, 57, and 59.

At the necropsy there was found intense hæmorrhagic cystitis, double hydronephrosis, and dilatation of the left ureter. The

FIG. 57 (slightly reduced).

bladder with its enlarged prostate was removed from the body, the membranous urethra being cut across at its commencement. The bladder was then opened on its anterior surface. The intravesical projection of the prostate was of the *os uteri* type. The

operation of so-called total prostatectomy was then performed on the parts in an exactly similar way to that adopted in the living subject. The process of enucleation was very easy.

Fig. 56 represents the mass enucleated; it measures 9·5 cm. in transverse diameter, and 6·5 cm. in a vertical direction. Its surface is lobulated, but here and there shows portions of a transversely fasciculated envelope. The prostatic urethra is intact within the mass. A finger introduced into the canal shows the tumour to consist of two lateral masses joined together in front and behind the urethra. The projection from the top of the tumour is a strip of the vesical mucous membrane.

Fig. 57 shows the bladder and the surgical capsule left after the removal of the adenomatous mass. The capsule is a very definite structure; a portion of the front wall of this has been removed, and through this opening can be seen the space left after the ablation of the tumour. Above this cavity communicates with the bladder by an opening having a diameter of about 4 cm.; below can be seen the opening of the membranous urethra, shown in the drawing as a triangular aperture. At one spot in the capsule, traversed by the section exposing the interior, can be seen a white lenticular mass. This is shown on the right and lower part of the drawing. A microscopic section of this mass shows it to consist of glandular tissue. Flattened recesses of similar tissue occur in the adjoining portion of the capsule. Lying outside the surgical capsule could be seen the layers of areolar tissue forming the recto-vesical fascia, and lying between the planes the veins of the prostatic plexus.

ADDENDUM.

On the deductions to be drawn from the presence of striated muscle-fibre in the "capsule" of the parts removed by "total prostatectomy."

Mr. THOMSON WALKER, in a recent communication read before the Royal Medical and Chirurgical Society (March, 1904), has drawn attention to the presence of striped muscle-fibre on the anterior aspect of the prostate. He describes it as surrounding the apex of the organ, and then as passing up on the anterior surface of the gland between the "capsule" and the posterior layers of the recto-vesical sheath of the prostate. (The prostate

plexus of veins lies between the layers of the recto-vesical fascia; consequently there will be a layer of the recto-vesical sheath between the veins and the layer of striped muscle.)

In another part of the same paper, when discussing the "capsule" on a specimen removed by prostatectomy, it is stated that striped muscle-fibre was found in the anterior part of the

FIG. 58.

A microscopic section of the peripheral part of a normal prostate from a boy aged 18 years, showing a certain number of striped muscle-fibres penetrating between the glandular acini. The fibres in question are derived from those above described as lying in front of the prostate and are situated at the inner or deep aspect of the recto-vesical sheath. They are distinct from the levator ani.

EXPLICATIO FIGURÆ.

Sectio microscopica partis extremæ prostatæ normalis pueri annorum 18. Monstrantur fasciculi musculares (striati) inter acinos glandulæ pertendentes. Hi fasciculi ex eis oriuntur qui sub fasciâ recto-vesicali musculoque levatori ani super glandulam jacent (auctoris Henle musculus).

"capsule." From this it was argued that the line of cleavage in the process of enucleation must have passed outside the confines of the gland, and that therefore the prostatectomy was complete.

In microscopic sections of the normal prostate, made at right angles to the long axis of the urethra and midway between the extremities of the gland, the following features in the relation of this striated muscle may be noted. At the most anterior part of such a transverse section the striated muscle-fibres take a transverse or horizontal direction. The bundles are well marked, and are separated from each other by a little fine areolar tissue. Near the urethra the bundles become more widely separated, and between them are seen to lie well-marked fibrous tissue and unstriped muscle-fibres. Traced outwards towards the lateral parts of the prostate, the striped muscle-fibres lose themselves in the

FIG. 59.

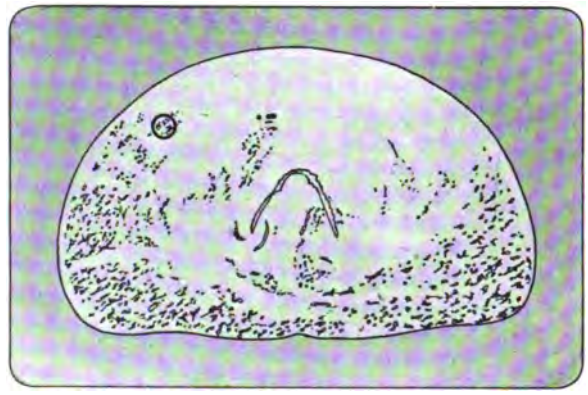

An outline of the transverse section of the prostate from which the preceding microscopic figure is taken. The section includes the whole of the gland, the microscopic field being marked within the circle shown. × 3.

EXPLICATIO FIGURÆ.

Sectio microscopica per prostatam præcedentem scissa; × 3.
Pars in figurâ præcedente monstrata lineâ circumdatur.

substance of the organ. Passing inwards towards the urethra, the striped muscle-fibres become more and more widely separated by the fibro-muscular stroma of the gland, until at length the latter predominates, the striped fibres becoming fewer and fewer until they cease altogether. Some time, however, before this happens the gland tissue makes its appearance, so that striped muscle-fibre, fibro-muscular stroma, and gland tissue are found in the same field; and it is in certain cases possible to see

gland tissue with striped muscle-fibres lying on both its central and peripheral aspect, so intimately is the striped fibre insinuated into the peripheral portion of the gland.

It thus follows that the presence of striped muscle-fibre in the "capsule" of an enucleated prostate is not to be taken as an irrefragable proof that the line of enucleation has passed outside the confines of the gland and that therefore the prostatectomy is complete; the completeness, as in other cases, can only be established by a microscopic demonstration of the absence of gland tissue in the parts left behind. *May*, 1904.

22. *The glomerular lesions of diffuse (parenchymatous) nephritis.*

By W. P. Herringham and J. H. Thursfield.

(With Plate V.)

The changes observed in the glomeruli in this disease have given rise to much difference of opinion as regards their significance. The difficulty lies in the fact that the microscopic appearances are most easily interpreted as due to the formation of fibrous tissue within the capsule, whereas the cells within the healthy capsule are of the epithelial type, which does not in other situations give rise to fibrous tissue.

Various explanations have been given. The capillary tuft was formerly thought to lie in a connective-tissue stroma. The older pathologists ascribe to this stroma the origin of the supposed fibrous tissue: its existence is now, however, disputed, and the whole explanation is in consequence abortive.

An actual metaplasia of epithelial cells into connective tissue has been suggested (Ziegler, 'Arch. f. Klin. Med.,' vol. xxv; von Recklinghausen, 'Verhandl. der x. Internat. Cong., Berlin, 1890,' vol. ii, abth. 3, p. 99).

Another hypothesis is that the basement membrane of the capsule itself sends out processes which run inwards; and further, that a rupture takes place admitting a small-celled infiltration from without (Böhm, 'Virch. Arch.' vol. cl, p. 52).

In a clear and careful paper, H. Engel describes under the

name "glomerulitis adhæsiva" the lesions in dispute, giving at the same time a good history of previous work on the subject. His descriptions are, according to our observations, extremely accurate, but we differ from his interpretation. ('Virch. Arch.,' vol. clxiii, p. 209.)

It is, in the first place, to be remembered that the degree of the glomerular affection varies greatly. We have examined minutely about thirty cases which during life and after death were diagnosed as diffuse nephritis, and in two of them have been unable to find any evidence of glomerular disease. In the others, the number of glomeruli attached, and the extent of the changes, have varied much. In some there is hardly a sound glomerulus to be seen; in others, those attached form but a small proportion of the whole number. It must always be borne in mind that the amount of kidney tissue examined is of necessity an extremely small fraction of the organ, and ill-fortune may have directed us to unaffected areas. But further we would liken the conditions of this form of nephritis to those of an eruptive fever, and would say that the variations above mentioned are no more striking than those observed in the eruptions of variola or scarlatina, which sometimes involve much, sometimes little, of the skin, and even occasionally in scarlatina fail to appear at all. We do not, however, suppose latent scarlatina to be a different disease because there is no rash, nor a discrete variola to be due to a different poison from that of the confluent form. We see no reason for supposing that "glomerulo-nephritis" is a separate type of disease, and we hold glomerular changes to be as essential a part of the morbid anatomy of diffuse nephritis as is the rash in the case of an eruptive fever.

The lesions observed fall into two groups—

I. Those of the capsule.

II. Those of the tuft.

I. *The changes in the capsule and cell-proliferation.*

A. *Cells.*—Between the layer which lines the glomerular capsule, hereinafter called the parietal layer, and that which is reflected over the capillary tuft, hereinafter called the visceral layer, a number of epithelial cells collect. That they are epithelial is proved by their size, their staining reactions, and by the division

which seems to be taking place in the epithelial cells of the above two layers, especially of the parietal.[1]

In different cases, and in different glomeruli of the same case, the arrangement of the proliferated cells varies.

Form 1. All the cells lie in a confused mass, sometimes in enormous numbers, within the capsular space.

Form 2. The inner cells show some tendency to a concentric arrangement, while those in the outer portion of the space are still disordered, or collected in spaces, forming "nests" of epithelial cells.

Form 3. All or nearly all the cells have become arranged in layers, some being long and flattened out, others still large and plump.

Form 4. All are in layers, and all are elongated and thin.

B. *Liquid effusion.*—There is in all cases an inflammatory effusion of liquid, which lies around and between the cells. The proportion of the two elements varies; in some cases there are few cells, and much effusion. In our series this has been most marked in the seven cases in which diffuse nephritis coincided with an infective endocarditis. In others the mass of cells is so large as to conceal the effusion altogether. The effusion appears to be lymph. It does not give the staining reaction (Weigert) of fibrin; at a later stage it stains deeply with fuchsin (Van Gieson). It does not give the iodine or aniline reactions of lardacein.

The visceral layer of the capsule adheres to it, and is often torn off the tuft when the latter shrinks with the hardening reagent.

The effusion is seen in several forms—

Form 1. It forms a large mass between the capsular layers, and a few cells lie in it, in spaces evidently shaped to fit them, but too large, an effect probably due to shrinkage during preparation. The same cause accounts for the tendency of the effusion to form wide bands or irregular masses.

Form 2. Owing to the tendency of the cells towards a concentric arrangement, the effusion itself lies in concentric layers between them forming an elongated network in the spaces of which the cells lie.

[1] NOTE.—Since this paper was written Lyon ('Journ. of Path. and Bact.,' vol. ix, p. 400) has described renal changes experimentally produced. He believes these cells to be regurgitated from the convoluted tube. We do not.

Form 3. Occasionally there are a number of broad laminæ with few cells.

Form 4. Occasionally there is a network of very fine fibrils, each space of which contains an elongated cell.

It will be readily understood that forms 3 and 4 of the cell arrangement and form 4 of the effusion lend themselves to the interpretation that true connective tissue is present. The extreme degree produced that impression upon us. We ascribed it, as does Engel, to a splitting of, or new formation from, the basement membrane of the capsule. But we found that not only in different cases, but also in the same case, many of the forms above described were found side by side, and we became convinced that they represent, not different processes, but different stages of the same process. There is no doubt whatever that the first forms represent an ordinary inflammation of epithelium; and careful examination has convinced us that the gradual transformation of the products of this inflammation can be traced through all the forms up to the last, and that at no stage can any additional factor be recognised. We have entirely failed to confirm Böhm's description of an invasion of the capsular space by small round cells from without.

The question still remains, What is the force which produces the concentric lamination and the flattening of the cells and effusion. The answer we find in the pressure exercised by the capillary tuft. It is remarkable that in the glomeruli altered in any one of these different ways, or as we should put it, degrees, the capillary tuft still invariably exists, though sometimes damaged. So far as we can judge it is always in fair condition; its nuclei are as numerous and stain as well, and are of the same size and shape, as in the tufts of a healthy organ. It seems probable, therefore, that it is still pervious to the blood-current. Where the effusion first takes place, the tuft is crushed into a smaller space; but as the activity of the inflammation subsides, the blood-pressure tends to expand the tuft. As it expands, it exercises pressure upon the capsular contents, crushing them against the outer wall. The inner portion of the effusion is the first to feel the effects of this pressure, and hence the concentric lamination is first seen in the inner layers, while the outer cells are still in loose order. The more the tuft expands, the greater the degree of lamination, until ultimately a few rows of linear

EXPLANATION OF PLATE V,

Illustrating the communication by Dr. W. P. Herringham and Dr. J. H. Thursfield on "The Glomerular Lesions of Acute (Parenchymatous) Nephritis." (P. 283.)

FIG. 1.—The glomerular tuft is surrounded, and its lobes separated, by a mass of cells and liquid effusion. This mass is bounded on its inner face by the visceral layer of the capsule, which, in process of hardening, has in places shrunk away from the tuft, and is adherent to the effused mass. The outer boundary is the flattened layer of cells which forms the parietal layer of the capsule. The cells in the inner part of the mass have a slightly laminated arrangement. Those in the outer part are in nests and show no sign of pressure. From a woman aged 20 who died of dropsy and uræmia after pregnancy. Case 1 in Series II, 'Path. Trans.,' vol. lii, p. 104. × 150.

FIG. 2.—The effusion in this case has very few cells in it. Along the right-hand border of the glomerulus the cells of the parietal layer of the capsule are dividing and forming small nests. From a woman aged 16, who died of septic endocarditis. × 180.

FIG. 3.—From the same patient as Fig. 2. The visceral layer of the capsule is traceable on the upper right-hand lobe of the tuft. × 180.

FIG. 4.—The tuft is surrounded by a mass of effusion which, at first sight, resembles fibrous tissue, but is only the liquid effusion pressed into layers and slightly shrunk by hardening. Nests of cells may still be seen in the outer layers on the left-hand side. In other glomeruli the effusion was similar to Fig. 1. The line of the parietal layer is fairly clear above and below, not so clear to the left. This is owing to the great disease of the surrounding tissue. There is no sign of any irruption of cells from without. From a man aged 26 who died with septic endocarditis and chronic diffuse nephritis. × 180.

FIG. 5.—The process has gone further, and the resemblance to fibrous tissue is greater. But other glomeruli show a condition like Fig. 1, others are like Fig. 4, and others, again, intermediate between them. From a woman aged 23, who was picked up unconscious in a fit and died soon after admission. She was six months pregnant, and had a single large kidney in the hollow of the sacrum. It was the subject of advanced diffuse nephritis. The glomeruli are large, up to 260 μ across. The fatal attack was probably uræmic. × 130.

FIG. 6.—The tuft is surrounded by an effusion resembling that in Fig. 4. The tuft retains its shape perfectly, but has become transformed into a hyaline mass, of which only the central parts show cells. It stains faintly pink with van Gieson, and gives no amyloid reactions. From a man aged 58 who died of chronic diffuse nephritis. The kidneys weighed 14 oz. together, and were contracting. × 170.

The photographs were taken by Mr. Albert Norman. They should be examined with a lens.

Fig 5.

[illegible] CASE V.

[illegible] Dr. W. P. Herringham [illegible] Lessons of Acute [illegible]

[illegible]

[illegible]

[

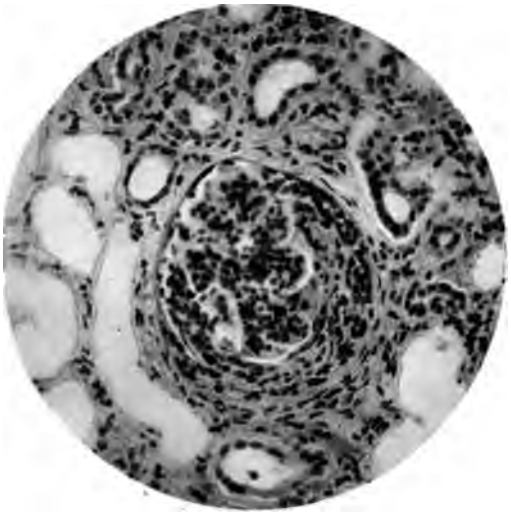

Fig. 1.

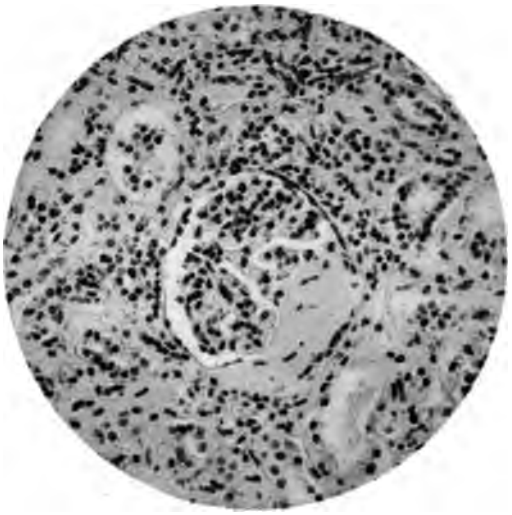

Fig. 2.

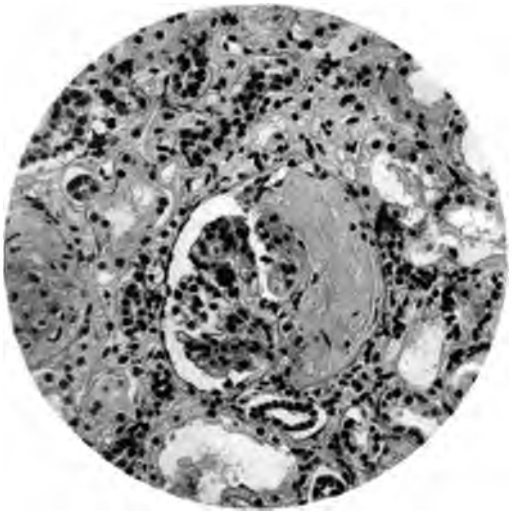

Fig. 3.

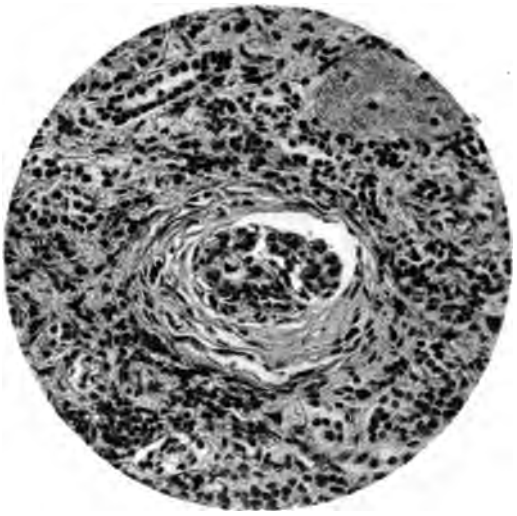

Fig. 4.

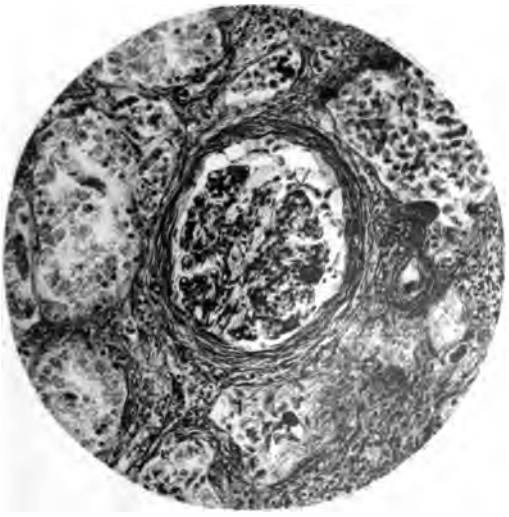

Fig. 5.

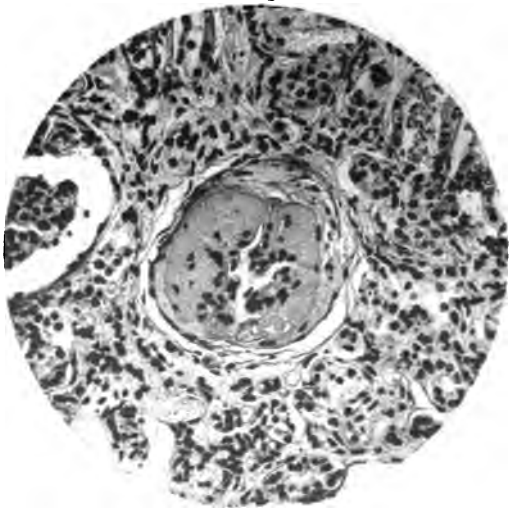

Fig. 6.

cells and a fine fibrillar network with cells in it will represent the proliferated epithelium and the liquid effusion of the first stage. For this process the persistence and the permeability of the tuft is necessary, and these appearances are met with only when the tuft is visible. When the tuft itself degenerates, a different picture is found.

II. *Changes in the capillary tuft.*

It is probable that in every case where effusion takes place the capillaries sustain some damage, though with our present methods this is unrecognisable. But it seems clear that as a rule the damage is insufficient to cause the death of the tuft, and that as the inflammation subsides, the blood again flows through the capillaries. In these cases the tuft is seen lying surrounded by the products of the capsular inflammation.

But it is not unusual to find in place of the glomerulus a body in which none of the normal structure remains. In its final form such a glomerulus consists of a homogeneous matrix with a few cells scattered in it at irregular intervals. There is no epithelial capsule, and no capillaries. It is certainly incapable of function. This condition is difficult to explain satisfactorily. The degeneration is obvious, but its causation obscure. It has been suggested that the inflammatory products in the capsule press on the stalk of the tuft, and cause its degeneration by cutting off its blood-supply. With this suggestion we cannot agree, first, because with Engel we can find no evidence that the pressure begins or is greatest at the stalk, and secondly because blood is often visible in the few remaining capillaries of a tuft already largely degenerate. The process is evidently gradual. Sometimes one loop alone is degenerate, while the rest of the glomerulus is apparently normal; more commonly the degeneration affects all the outer parts of the tuft, while the central portions remain unaffected. The surrounding effusion may still be seen separate from the tuft. Ultimately the degeneration is complete, and coalescence of the degenerate tuft with the inflammatory products produces a structureless mass surrounded by a fibrous ring.

As we cannot admit that the process depends upon ischæmia from pressure within the tuft, so we find no evidence that pres-

sure upon the arteriole leading to the tuft is the cause of the degeneration. There is no sign of thrombosis, or of obliteration of its lumen; on the contrary, the vas afferens is often conspicuously normal. The conclusion to which we are compelled is that no mechanical cause will account for the degeneration, and that some slow chemical or bacterial poison is the efficient agent of the change. *May 17th*, 1904.

---

23. *A case of leukanæmia with great hyperplasia of the spleen and prævertebral hæmolymph glands, and with increase of connective tissue in the bone marrow.*

By F. Parkes Weber.

By leukanæmia (W. von Leube[1]) I understand a morbid condition in which clinical symptoms found in pernicious anæmia are combined with blood changes and anatomical changes in the organs characteristic of leukæmia or pseudo-leukæmia, whether of the "lymphocytic" or "mixed-cell" type. The present case seems to combine certain features of pernicious anæmia with those of a "mixed-cell" pseudo-leukæmia. I intend first to give an account of the case, including the anatomical-pathological findings, and then to draw what conclusions I can as to its pathological nature.

The patient, P. von. E—, a German, aged 58 years, was admitted under my care at the German Hospital on December 10th, 1903, suffering from great anæmia, progressive weakness, anorexia, and tinnitus.

History.

The history was that he had enjoyed fairly good health till twelve months ago. In fact, he seems to have been able to insure his life about one year before admission. The symptoms of his

[1] W. von Leube, 'Deutsche Klinik,' Berlin, 1902, No. 42; and J. Arneth's hæmatological account of Leube's case in 'Deut. Arch. für klin. Med.,' Leipzig, 1901, vol. lxix, p. 331; also H. Luce, "Ueber Leukanämie," 'Deut. Arch. für klin. Med.,' Leipzig, 1903, vol. lxxvii, p. 215. "Leukanæmia" is obviously a term coined out of "leukæmia" and "anæmia," and will, I believe, be found well suited as a clinical term for the present class of cases.

illness, wax-like pallor and weakness, with anorexia, commenced about that time—that is to say, about the end of 1902; but at first there seems to have been improvement under treatment.

He had never suffered from malaria or been out of Europe. He had lived in England since 1865. He had had attacks of gonorrhœa, and in 1868 had had a chancre, but apparently without any signs of secondary syphilis. He had never had any kind of hæmorrhage.

Condition after admission, in December, 1903.

The patient is somewhat fat, flabby, and very pale. His faint-yellowish wax-like pallor and puffy appearance are such as Addison described in pernicious anæmia. There is no evidence of anything abnormal in the heart or lungs, except a soft systolic murmur at the cardiac apex, and a few crepitations at the base of the left lung. The liver and spleen are greatly and uniformly enlarged. The hepatic dulness commences above at the sixth rib in the right nipple line, and in the same line the lower edge can be felt at the umbilical level. The splenic dulness commences above at the eighth rib in the left axillary line, and the organ is so enormously enlarged that its lower edge can be felt in the hypogastrium below the level of the anterior superior iliac spine, and in the front of the abdomen its right margin is felt considerably to the right of the navel. No distinct ascites. Some œdema of lower extremities and loins. Urine, of specific gravity 1016, free from albumen and sugar (see later note). Bowels open regularly. No vomiting. No cough. Pulse about 88 per minute, regular. Radial arteries somewhat thickened.

After-history.

In spite of treatment the patient steadily lost strength. The œdema increased and became very noticeable in the face. At last he hardly had strength to swallow, and died quietly early on January 15th, 1904.

There was slight fever (about 100° F.) during the first days in the hospital, but afterwards the temperature seldom rose above 99° F. The pulse, as recorded on the chart during the last days of life, varied between 76 and 96 per minute.

The *urine* was of specific gravity 1014 to 1020, pale, acid, and

free from albumen and sugar. On only two occasions was a lower specific gravity noted, and on only two occasions was a trace of albumen detected. The amount of urine was at one time below the normal, but during the last period reached about 1800 c.c. per diem.

The blood.—On admission (Dr. Campiche, December 11th, 1903), the red corpuscles numbered 1,800,000, and the white cells 3,000 per cubic millimetre, the hæmoglobin was 25 to 30 per cent. of the normal, and there was a good deal of poikilocytosis. The following differential count of the white corpuscles was made by Dr. G. L. Eastes, January 7th, 1904: Small lymphocytes 49·4 per cent., large lymphocytes 9·6 (total lymphocytes 59·0), polymorphonuclear leucocytes 37·5, eosinophile leucocytes 0·5; myelocytes 3·0; no eosinophile myelocytes. During the count of 400 white cells, 30 erythroblasts (24 normoblasts, 2 microblasts, and 4 megaloblasts) were seen. There was poikilocytosis and polychromatism (neither extreme) and likewise leucopenia. On January 14th (the day before death) a rough blood count was made, the red corpuscles being estimated as about 1,200,000, the white cells as about 12,000 in the cubic millimetre, and the hæmoglobin richness as about 25 per cent. of the normal. During the last days of life, therefore, the number of white cells appears to have considerably increased.

Necropsy (*January* 15*th*, 1904).

Brain.—Examination not permitted.

Thorax.—The heart showed nothing noteworthy, and weighed 11 oz. (312 grams). There were some pleuritic adhesions over part of the left lung and great hypostatic congestion of the left lower lobe, but otherwise the lungs appeared free from disease. There was a moderate amount of serous fluid in the pericardium and both pleuræ.

Abdomen.—There were many small peritoneal petechiæ.

The spleen was enormously enlarged, weighing 66 oz. (1,872 grams), and its capsule was slightly thickened. On section the splenic substance appeared normal to naked-eye examination, excepting that it contained one pale nodule below the capsule, of about the size of a large cherry, which subsequent microscopic examination showed to be an infarct.

The liver was uniformly enlarged and weighed 88 oz. (2496 grams), but to naked-eye examination showed no cirrhosis or other distinct structural changes.

The kidneys were of normal size, and weighed together about 10 oz. (256 grams). The cortical substance was not diminished and the capsules stripped fairly well. At one or two spots below the capsules there was slight increase of connective tissue (that is, by subsequent microscopic examination). The right kidney contained a few small cysts. In the left kidney was a minute cystic papillary adenoma, with the remains of a hæmorrhage into it.

Nothing abnormal was found by naked-eye examination in the pancreas, supra-renal glands, stomach, or intestines, excepting a few small petechiae in the gastric mucosa.

The lymphatic glands generally were not obviously enlarged, but the prevertebral tissue about the bifurcation of the aorta was studded with small red hæmolymph nodes. Most of these were small and oval in shape, about 3 mm. by 4 mm., but their sizes varied and some were much bigger (10 mm. by 20 mm. or so), and some alongside of the aorta, owing to their elongated shape, or because they lay close together end to end, might almost be compared to leeches [2] in appearance.

Bone marrow.—The left humerus was sawn through longitudinally, and the whole of the fatty marrow of the shaft was found to have undergone transformation into a red substance (red metaplasia) of unusually firm consistence. Owing to the markedly firm texture of this bone marrow no good films were obtained for microscopic examination. (For the examination, however, of microscopic sections see later.)

Microscopic examination.

Sections were stained with eosin and hæmatoxylin, and hæmatoxylin alone, and by Ehrlich's triacid stain, Mann's long eosin-methyl-blue method, and by some other blood stains.

The bone marrow (from the shaft of the left humerus) was almost destitute of the normal fat vesicles. It showed a stroma of a kind of loose connective tissue containing blood, myelocytes,

[1] This comparison of the appearance of very long prevertebral hæmolymph glands to leeches has been borrowed from Dr. H. D. Rolleston.

non-granular large mononuclear cells,[1] and abundance of erythroblasts. The erythroblasts, conspicuous by their deeply and almost homogeneously stained nuclei, were not uniformly distributed, but, as usual, occurred here and there in greater numbers—that is, in clusters. They were of various sizes, some large, some small, but mostly of medium size (normoblasts). Many of them possessed more than one nucleus or a partially divided nucleus, and often the nucleus appeared to have been split up into many fragments or droplets. There were likewise a good many giant-cells in the bone marrow, and a few coarsely granular eosinophile cells were seen. The fibrous stroma was best seen in a portion of bone-marrow which was paler than the

FIG. 60.

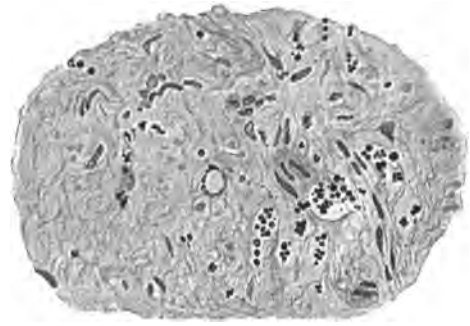

Illustrating the connective-tissue change in a portion of the bone marrow. The nuclei and fragments of nuclei of erythroblasts are represented by deep black dots. × 220.

rest, and contained less blood. In this portion (see Fig. 60) the bone marrow had been practically converted into a kind of loose connective tissue containing conspicuous groups of erythroblasts. I regard this connective-tissue change in the bone marrow as one of the most remarkable features in the case.

The liver.—Microscopic examination revealed a very remarkable condition, which, however, was not equally well marked in all parts of the organ. The columns of hepatic cells were separated and seemed to be pressed on by groups of cells, which on the whole were similar to those described later on as forming peculiar "clumps" in the spleen. The groups of cells which thus separated the columns of hepatic cells were chiefly com-

[1] I do not use the term "large mononuclear cell" in the limited special sense often attached to it.

posed of myelocytes, non-granular large mononuclear cells and erythroblasts (or the nuclei only of erythroblasts), but scattered about here and there were likewise coarsely granular eosinophile cells, and (in some parts) giant cells. The presence of these giant cells in some sections of the liver (they were not found in the spleen) formed one of the conspicuous features of the case (see Fig. 61). The cell accumulations just described occupied the positions normally occupied by the intra-acinous hepatic capillaries. In some places the cells seemed to be actually within the walls of capillaries, but in other places they seemed to form regular "growths"; and that they could not have been in the circulating blood stream at the time of death is proved not only

FIG. 61.

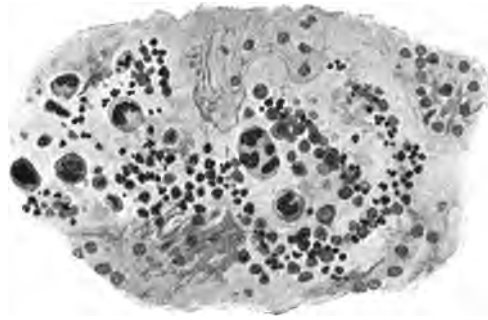

From a section of the liver, showing erythroblasts (their nuclei and fragments of nuclei are represented by deep black dots), giant cells, and white corpuscles accumulated together in an irregular space between the hepatic cells. × 220.

by the examination of the blood shortly before the patient's death, but also by the appearance of the blood as seen in rather larger blood-vessels in the microscopic sections. Moreover, no similar accumulations of cells were present in or about the capillaries of the pancreas and kidneys. It is difficult to imagine how the circulation in the liver could have been carried on during life, seeing that the spaces normally occupied by the hepatic capillaries were stuffed by the cell accumulations of which I have been speaking. This difficulty was especially noted by Mr. S. G. Shattock, whom I have to thank for kindly looking through the microscopic preparations of the case with me. It must be remembered, however, as I have already stated, that not all parts of the liver were affected to the same extent.

The spleen.—In regard to the small infarct, I need not add anything to what I stated in the account of the necropsy. The Malpighian corpuscles (and the lymphocytes in them) appeared normal. The splenic pulp, however, was permeated with erythroblasts and mononuclear cells similar to those found between the columns of hepatic cells. Here and there were coarsely granular eosinophile cells. All these kinds of cells were fairly equally distributed throughout the splenic pulp, just like the red blood-corpuscles were, excepting at certain spots where they occurred, without admixture of erythrocytes, crowded together in dense circular or elongated clumps. Some of these "clumps"

FIG. 62.

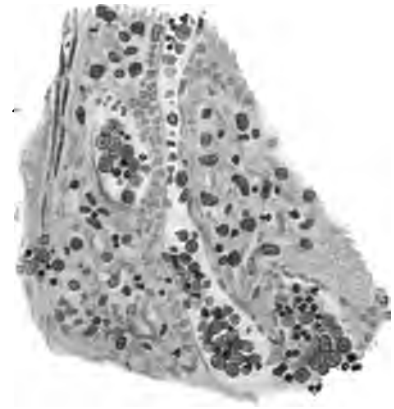

From a portion of the splenic pulp showing erythroblasts (deep black nuclei) and other cells (nuclei only represented) occupying a splenic capillary and sinus. To the left of the capillary is one of the small "clumps" referred to in the text. Red corpuscles are only faintly indicated. × 220.

were evidently within splenic capillaries and blood sinuses (see Fig. 62), whilst others appeared to be filling up mere clefts in the splenic stroma.

The sections of the kidneys showed nothing noteworthy beyond what has already been mentioned. The pancreas appeared not to be diseased. The hæmolymph glands resembled lymph glands in structure excepting for the presence of blood in the sinuses. Besides lymphocytes and erythrocytes they contained erythroblasts and large mononuclear cells apparently similar to those permeating the splenic pulp; also a few coarsely granular eosinophile cells and a few giant cells.

Sections of the different organs were also stained with methyl-violet for amyloid changes, but with negative result. Microchemical tests failed to show the presence of free iron in sections of the spleen, liver, and kidney.[1]

Remarks.

The main features of the case may be summed up as follows:

1. Progressive waxy pallor and asthenia with maintenance of subcutaneous fat.

2. Changes in the red blood corpuscles rather similar to, but not so extreme as, those met with in true pernicious anæmia.

3. Absence of true leukæmic changes in the blood, but presence of slight myelocythæmia and presence of the inverted proportion of lymphocytes to polymorphonuclears which is found in cases of lymphatic pseudoleukæmia (Hodgkin's disease, etc.).

4. No abnormal amount of pigment in the urine.

5. Changes found after death in the hæmopoietic tissues similar to those which occur in cases of "mixed-cell" leukæmia or pseudoleukæmia.

6. Abnormally firm consistence and increase of connective tissue in the bone marrow from the shaft of a long bone.

7. Absence of enlargement of the ordinary lymph-glands, but great hyperplasia of the spleen (hæmal gland) and prevertebral hæmolymph glands.

8. Absence of any reaction in sections of the spleen, liver, and kidneys for free iron such as is found in pernicious anæmia.

Charcot-Leyden crystals were not noticed in the bone marrow, etc., but were not specially looked for.

In spite of the poikilocytosis the disease in the present case seems not to have been secondary to any excessive hæmolysis, but to have been primary in the bone marrow, and I would regard it as a myelogenic form of splenic anæmia of adults, doubtless allied to what French authors[2] have termed "anémie splénique myéloide." Therefore the case cannot be adduced as an example of pernicious anæmia being followed by or becoming

[1] No Prussian blue reaction was obtained by the "long" method employed by Abbott for pieces of tissue which had been lying in formalin (*vide* 'Path. Soc. Trans.,' 1900, vol. li, p. 76).

[2] *Vide* Vaquez and Aubertin, "Nature de l'Anémie Splénique Myéloide," Société de Biologie, Paris, May 14th, 1904. Also Weil and Clerc, "Splénomégalie avec Anémie et Myélémie," Soc. de Biologie, June 4th, 1904.

transformed into leukæmia, though it is probable that similar cases have been erroneously supposed to illustrate such a course of events. It is also highly probable that similar cases, owing to enlargement of spleen and liver, have been clinically regarded (in spite of the poikilocytosis) as examples of Banti's disease.

In the German cases, I believe, enlargement of hæmolymph glands was not noted.

It is very tempting to suggest that in the present case both the spleen (hæmal gland) and the prevertebral hæmolymph glands were actively engaged in supplementing the erythrocyte-forming functions of the diseased bone marrow, but I have no conclusive evidence to support such a supposition. From what has been lately written on the subject[1] it seems that no really satisfactory evidence has been brought forward to show that in adults erythrocytes are produced in the spleen and hæmolymph glands either in health or in disease. *May 17th,* 1904.

---

24. *Sarcoma of the stomach.*

By Redcliffe N. Salaman.

[With Plate VI.]

Sarcoma of the stomach is a subject which has awakened a fitful interest in the medical world for many years, but at no time has it excited the same interest as carcinoma of the organ; nor has it ever attained the distinction of more than a passing reference in the text-books; in fact, Ziegler in his last edition dismisses the subject in the following words: "Die Bindesubstanz Geschwülste spielen unter den Magentumoren eine sehr unbedentende Rolle. In seltenen Fallen Kommen Knotenformige Sarkome, Lipome, Fibrome (auch Nervenfibrome) und Myome zur Beobachtung die meist nach innen, selten nach aussen vorragen"—words which are not only misleading but also incorrect.

Other prominent books do not even do as much justice to the

[1] See especially "The Pathology of Pernicious Anæmia with special Reference to the Changes occurring in the Hæmolymph Nodes," by Dr. A. S. Warthin, 'American Journ. Med. Sci.,' 1902, vol. cxxiv, p. 674.

subject as Ziegler; Hektoen and Riseman say of the stomach tumours, "Lipoma and myoma are rare and of little importance; sarcomas are also rare. Very common are carcinomas," etc., etc.

The insufficient attention given in the text-books, as well as the two cases, each illustrating very different types of the complaint, is my reason for treating the entire subject in some detail.

CASE 1.—F. R., aged 42 years, died October 22nd, 1902.

Clinical history.—Five years ago the patient, who was then a grocer's assistant, was seen by Mr. Mansell-Moullin, on account of water brash; both during and between meals a flow of fluid would regurgitate into the mouth, often leading to sickness. After medicinal treatment and false teeth the trouble entirely ceased and the patient remained, except for the oncome of deafness, perfectly well till seven weeks before his admission to the London Hospital on October 10th, 1902.

The following is abstracted from the hospital clinical notes:—The patient is extremely thin and emaciated, a condition that started only seven weeks ago and steadily increased. He complains of pain in the epigastrium radiating to the back, and worse on the left side. The pain is persistent, not collicky, and has no definite relation to the ingestion of food.

Examination revealed a tumour in the upper part of abdomen on the left side, which did not move with respiration. No examination of the blood was made.

On October 15th Mr. Moullin performed a median laparotomy, and finding that along both curvatures were great masses of gland of a malignant nature, he decided to close the abdomen. A week later the patient came to autopsy.

Extract of post-mortem notes.—The body was that of a very wasted man of middle age. The cervical glands on the left side were markedly enlarged. The stomach is of enormous size; beneath the serous coat on both surfaces are large rounded swellings. The length of the organ, *i.e.* from cardia to pylorus, is 11 inches, its antero-posterior diameter six inches, whilst the walls are on an average one inch thick. The glands lying around the cœliac axis are immensely enlarged, and have come to lie in the gastro-hepatic omentum, whence they become continuous with the thickened walls of the stomach. The greatest

thickness of this united mass (Fig. 63) is no less than six inches. On cutting through the mass from behind it is seen that for about four and a half inches of the central part of the lesser curvature the fusion is quite complete between glands and stomach, and it is only by careful examination of microscopic

FIG. 63.

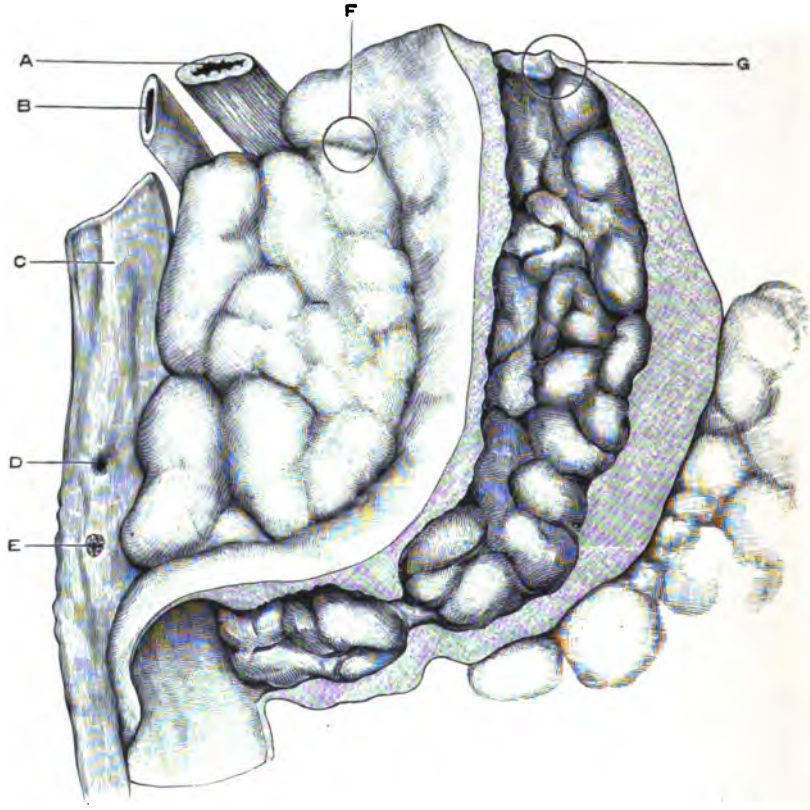

A reduced drawing of the stomach and cœliac glands of Case 1. The stomach is opened along the greater curvature to show the irregular growth of the tumour in its walls. A. Œsophagus. B. Aorta. C. Inferior vena cava. D. Renal vein. E. Rupture of growth from the cœliac glands into cava. F and G. Points from whence sections were cut, and referred to in text.

sections that traces of elastic fibres and muscles and nerves are seen indicating the former site of the stomach wall.

The stomach when opened was seen to possess no longer a potential but an actual cavity, and it could, not inaptly, be compared to a boiler with furred walls. The hypertrophy of the

wall extended into the duodenum for a distance of two inches. The inner surface of the walls were coated with a ragged greenish mass of slough and slime. Near the cardia was an islet of normal mucous membrane (G, Fig. 63) remaining. Similar islets occurred near the pylorus and along the greater curvature.

This patch of mucous membrane (Fig. 64) lies on a muscularis mucosa and muscular coat, which present to the naked eye no abnormalities, and which under the microscope exhibit only round-celled infiltration. The mucous membrane is very much atrophied and necrotic, but this is not due to any growth in it, but is part of the gangrenous gastritis seen everywhere. Certain

FIG. 64.

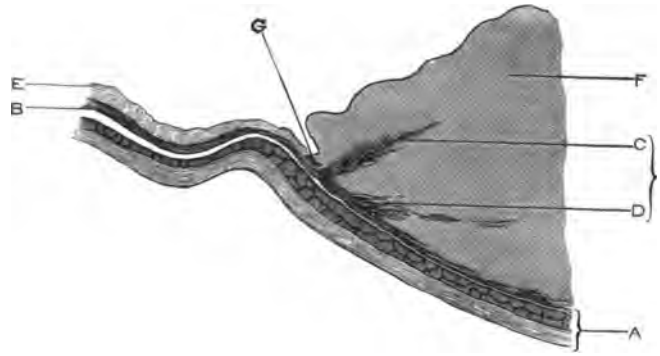

Diagrammatic drawing of a section from a spot (G, Fig. 63). The sudden transition from normal to infiltrated portion of the mucous membrane is seen, as well as the splitting up of the muscularis mucosæ by the invading growth. A. Muscular and serous coats. B. Muscularis mucosæ. C and D. Separated portions of muscularis mucosæ. E. Normal mucous membrane. F. Tumour. G. Lymphatic laden with tumour cells.

lymphatics appear to be infected with tumour cells, but this will be referred to later.

The glands of the gastro-hepatic omentum and greater omentum, as well as the cœliac glands, were filled with a greyish-white deposit. The tonsils were hypertrophied and contained similar tumour substance to the glands, as did also the cervical glands. The pancreas was firmly adherent to the stomach, and was bound up in the tumour substance which formed the posterior wall of the latter, but was not otherwise seriously affected.

The most interesting *post-mortem* find was a number of raised ulcers of the intestine (Fig. 66). There were three in the jejunum, ten in the ileum, and one in the cæcum at the attach-

ment of the appendix. These ulcers varied in size from that of a pea (Fig. 65) to one which, entirely surrounding the gut, reduced its diameter to less than half an inch over a length of one and a half inches. The edges were raised and hard, sharply marked off from the surrounding normal mucous membrane. The centre was sloughy in all except the quite small ones, which had a smooth covering; outside the larger ones the peritoneum was slightly thickened and roughened.

In the spleen were two small infarcts. The other organs showed no changes of pathological interest, except the left lung, in the basal lobe of which was a hardened nodule of darkish colour suggesting an infarction.

Microscopical examination of the stomach, ulcers of the intestines, glands and nodule in the lung, showed all to be of the same nature. The infarcts of the spleen contained no tumour formation. Unfortunately, the marrow of the long bones was not examined.

Examination of the specimen (Fig. 63) removed *post mortem* after hardening brought one important fact to light, viz. that at a point just below the entrance of the renal veins into the inferior vena cava the enlarged glands of the cœliac axis group which were firmly adherent to the vein had broken through it (Fig. 63, E). The spot is capped by a small mass of clot. Microscopically one sees how the tumour cells have got between the elastic and muscular laminæ of the vein wall, thinning these out, and have ultimately reached and pierced the elastica interna, the actual gap being comparatively a small one as compared with the cap of fibrin overlying it. In relation to this rupture into the inferior vena cava it is of interest that the only secondary growth found other than in glands is that in the lung, where around a central focus of clot a zone of actively growing tumour cells was found, which may be readily supposed to have taken origin from the rupture into the inferior vena cava.

The aorta was embedded amongst the enlarged glands, as also were the portal vein, superior mesenteric and splenic veins, all of which were lying within the great mass of post-peritoneal glands but were not in any way affected.

Section of the thickened stomach wall showed that the growth infiltrated the entire thickness of the wall, the peritoneal coat being in parts entirely and in others partially replaced by

growth, whilst of the mucous membrane nothing could be seen. In the more peripheral parts traces of the musculature of the stomach wall were seen, as well as vessels whose perilymphatic spaces were filled with round cells. The growth itself (Pl. VI, Figs. 2, 3) is composed of round cells about the size of multinuclear leucocytes with a single nucleus rich in chromatin and varying in shape from circular to elliptical. The cytoplasm forms a thin coat round the nuclear membrane and is extended into fine processes which fuse with those of neighbouring cells and give rise to the stroma. Mitoses in every stage, and apparently of a normal type, can be seen amongst them; such dividing cells have more protoplasm than the others and appear to have withdrawn their protoplasmic processes. Besides these, there are some very large cells of at least two types—(*a*) a large cell with an enormous single indented nucleus containing but little chromatin, and (*b*) still larger cells, giant cells, containing several (4 to 8) nuclei arranged centrally, generally of a spherical or elliptical shape and very poor in chromatin. Occasionally some of these cells, which are especially numerous in the neighbourhood of necrotic and hæmorrhagic foci, of which several are present, contain in their protoplasm the nuclei of other cells lying in vacuoles. They would appear to have a phagocytic nature.

The capillaries in the main mass of the growth were very small and scanty; they are lined by a single layer of elongated cells whose nuclei are elliptical and contain but very little chromatin and whose protoplasm seems to become continuous with the stroma of the growth.

These fine capillary vessels were frequently blocked by tumour cells; whether these cells ever originated *in situ* from the lining cells of the capillaries or the latter from tumour cells could not be definitely determined; it was the exception, however, for the lining cells not to be quite distinct from the tumour cells filling the capillary. No mitoses were observed in the lining cells of the capillaries.

Numerous small hæmorrhages were seen, but what pigment these formed was for the most part free in the stroma, though some granules could be seen lying in the neighbouring round cells and in the multinuclear giant cells.

Section of that part of the stomach wall (Figs. 63 and 64)

which is not infiltrated with the growth is interesting as showing how abrupt the change from normal to sarcomatous stomach wall is. The actual demarcation is made by a zone of small round cells which forms a vanguard to the oncoming growth, and more especially to that in the lymphatics (Fig. 63, G) which are crammed with sarcoma cells.

The main growth is seen here to lie beneath the muscularis mucosæ (Fig. 63, *c* and *d*) which it has split in various directions, and to have pressed forward and destroyed the mucous membrane.

The circular musculature in the infiltrated portion (Fig. 63) is much hypertrophied, but here also the tumour cells are beginning to penetrate. The innermost portion of the stomach wall is macerated and necrosed and for a depth of one millimetre the cells show no nuclei; the cell outlines, however, remain intact, and winding in all directions between them are fine threads which stain by Gram as well as by the ordinary reagents. These threads are in places coiled up into balls and lie in the cavities of small vessels and at other times in the perivascular lymph space. That the threads are not fibrin is shown by the fact that they stain a strong blue both by hæmatoxylin and eosin and tolindene blue, and that they occur quite apart from hæmorrhages. Their anatomical character, viz. their perfectly even outlines, the winding and coiling in all directions without forming a meshwork, is evidence in the same direction. Dichotomous branching, though not common, undoubtedly occurs amongst these filaments, and it is seen that by Gram's method the staining is not absolutely uniform and that in the course of the thread numerous unstained and refractile areas of the size of a small coccus exist. It is suggested that it may be some ascomycete, perhaps thrush. I have met the same type of growth in a case of medullary carcinoma of the stomach. The structure of the stroma of the stomach growth has been described, but it is necessary to consider the question somewhat further.

That the stroma consists merely of the cell processes of the tumour cells themselves is true of the thickened wall of the stomach internal to the muscular coat (Pl. VI, Fig. 3). It is also true of the stroma in the larger malignant ulcers of the intestine.

The stroma of the tumour composing the great mass of glands

in the lesser omentum, however, is definitely reticular; it is composed of fine processes uniting at all angles to form a meshwork; these processes are seen to be the attenuated protoplasmic bodies of cells with, for the most part, elongated pale nuclei. Sometimes these reticular cells are triangular and richer in protoplasm, whilst many are not to be distinguished from young connective-tissue fibres. The similarity of these cells to the cells lining the fine capillaries in the growth everywhere is very striking.

The quantity of stroma derived from these reticular tissues is a very variable one. Where there has been plenty of delicate fibrous tissue, as in the serous coat of stomach and wall of lymphatic gland, there the stroma is abundant and it is seen distinctly to take its origin from pre-existent tissue.

Pathologically the case described presents many great difficulties, both in its histological and macroscopic characters.

Of great interest in respect to the origin of the secondary growths in the intestine is the nature of their stroma. In the larger ulcers, as already stated, the stroma is the same as in the stomach. But in the minute polypoid growths it is otherwise, and resembles in all respects the stroma of the glands. Why this difference exists is explained by the fact that whilst in the small growths the reticular cells, though showing evidence of degeneration, are still present (Pl. VI, fig. 5), in the larger ones the sarcoma tissue proper has grown so rapidly that the reticular cells have perished, and even if they did increase at all have not kept up to the actively dividing round cells which now exist without them.

In sections of the stomach wall at a distance from the great gland mass at a point such as fig. 1, F., it is seen that there remain considerable vestiges of the muscular, serous, and subserous layers, though all are densely infiltrated and widely separated by sarcoma-cells. Here the old connective tissue is acting as a stroma, but as one proceeds inwards, so this tends to become less and less evident, whilst the cells and processes which give rise to it atrophy and disappear.

Daniels (11),[1] whilst asserting that all sarcomata have a stroma, states that this stroma may be derived in infiltrating growths from the pre-existing vessels and connective tissue, but that in others it is supplied by the sarcoma tissue itself.

[1] The numbers next to authors' names refer to the bibliography.

The glands are uniformly infiltrated with growth and the reticular structure of the stroma of the gland is to a large extent retained. In places, thrombosis of the vessels and necrosis of the tumour-cells, with secondary invasion of leucocytes, have taken place.

Sections of the growth stained with Pappenheim's plasma stain (pyronin and methyl green) (Pl. VI, fig. 2) bring out strikingly two facts—(*a*) that the ordinary cells of the growth possess considerably more protoplasm than does the ordinary lymphocyte, and (*b*) that the large uninuclear cells have a special affinity for the pyronin stain, and in that respect resemble endothelial cells, and still more closely the large cells of lymphadenoma. No granulation in these large cells was observed. The cells of the endothelium of vessels running through the growth are differentiated from the ordinary tumour-cell by their more intensive pyronin staining, which much more closely approaches that of the large cells. All cells in a state of mitosis stain strongly with Pappenheim's reagent.

The small solid nodule in the basal lobe of the left lung seems to be at the same time an infarction and a secondary growth.

In the centre the vessels are thrombosed, the circumvascular lymphatics filled with sarcoma cells, the alveoli are filled by large round cells and giant cells similar to those of the growth in the stomach. These cells, by the shape of their nuclei, the richness of chromatin, and the presence of mitoses, are readily distinguished from the alveolar cells which are here and there shed into the alveoli.

The growths in the intestine, fifteen in all, resembled to the naked eye ordinary primary malignant growths of the gut except that there was only a slight diminution in calibre of the latter.

Small ones (Fig. 65) are seen to be polypoid in shape and to be covered completely by mucous membrane.

The reticular tissue between the intestinal glands is packed with sarcoma cells similar to those already described, and these are seen to be continuous with the main mass which lies below the muscularis mucosæ and between this and the peritoneum, which latter has undergone but little change. The communication in a very small secondary tumour between the growth above and below the muscularis mucosæ is seen to be by means of

lymphatic vessels laden with tumour-cells. The muscularis mucosæ itself is much thinned out. The lymphatics in the subserous coat are in some cases clearly blocked with sarcoma cells.

In the larger ulcers (fig. 66) the mucous membrane either falls towards the centre and definite ulceration has taken place or it is extremely thinned out and only traces of the muscularis are to be seen. There is also a slight local peritonitis. The veins are all thrombosed, and in the larger ulcers the thrombi appear

FIG. 65.

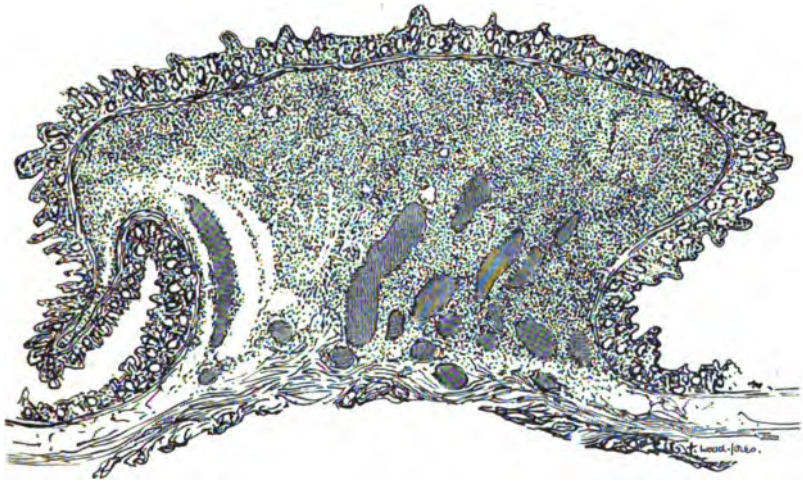

Small polypoid projection into the lumen of the small intestine. It is composed of tissue similar to the growth in the stomach and lies below the muscularis mucosæ, and is covered by normal mucous membrane.

to be older than those in the smaller ones. In both cases, however, the thrombi do not appear to be as old as the growth itself.

The formation of these secondary intestinal growths is of interest from the point of view of their causation. Their arrangement and form might give rise at first to the impression that they have arisen from direct infection through the mucous membrane; against this, however, is the fact that the secondary growths are covered at first by mucous membrane and attain considerable dimensions before the epithelium is seriously attacked; and though it might be assumed that either the tumour-

cell itself or a possible "tumour germ" entered by the mucous membrane and settled in the lymhatic nodes of the intestine, there is no evidence in the literature, nor is it at all necessary to assume such an hypothesis.

The appearance of these growths suggests that they are sarcomatously enlarged lymph nodules: the condition of muscularis mucosæ as well as the reticular structure of the stroma in the smaller ones point in the same direction.

FIG. 66.

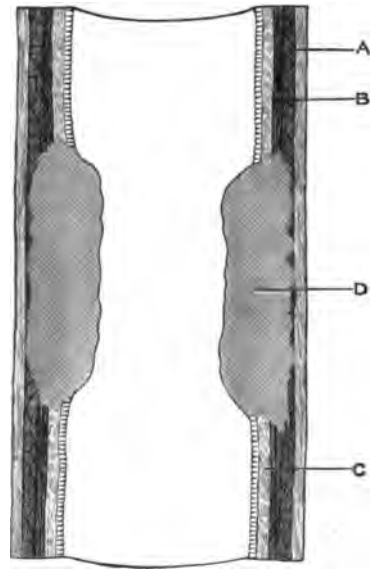

Diagrammatic section of the small intestine, showing the annular mass of growth situated in the mucous and submucous coats. A. Circular muscular coat. B. Muscularis mucosæ. C. Submucosa. D. Growth.

The occurrence of a large growth around the attachment of the appendix where so much lymphatic tissue is present may be explained in the same way. In all parts of the stomach, even where the growth is an inch thick, and also in the growths in the intestine, the nervous elements seem to have held their own. In sections at the point (fig. 1, F) large branches of the vagus are cut, whilst in all the ganglion cells which lie between the circular and longitudinal muscle coats, both in the stomach and the intestines, are very well preserved.

It is of interest that clinically the pain was very great and continuous, but was not of a colicky nature.

The irritation of the ganglia and nerve trunks, rather than of the peripheral endings in the mucous membrane, which must have been lost in the fungating and ulcerating interior of the stomach, may be perhaps correlated with these facts.

CASE 2.—D. L—, aged 51, died April 9th, 1903.

The second case is of a different type, and the description of its clinical and pathological appearances is now given.

The clinical history was only of two weeks' duration, during which he experienced some shortness of breath, and vomited after food during the last three days. The abdomen was swollen, and eight pints of hæmorrhagic fluid were removed before death.

Post mortem there was found to be in the abdomen an enormous increase in volume of the omentum, appendices epiploicæ, and outer wall of small and large gut, whilst the stomach, instead of appearing as a flaccid organ, was much enlarged, and its walls thickened to such an extent as to make its cavity an actual rather than a potential one; and scrapings from the stomach wall and epiploicæ showed the thickening to be made up of small round cells.

The glands of the lesser omentum were somewhat enlarged, but except for that there were no metastases. The spleen was small and natural.

The stomach appeared to be the primary seat of the disease for the following reasons. Whilst in the remainder of the gut the infiltration affected the serous coat and its appendages only, in the stomach the muscular and mucous coats were affected; and opposite the attachment of the spleen the growth in the stomach wall had advanced so far that all trace, to the naked eye, of differentiation between the three coats of the stomach was lost, and its wall was over one inch thick.

The stomach is 8½ inches long and 4½ inches deep between the two curvatures. The mucous membrane is not lost anywhere, although near the attachment of the spleen the glandular crypts are so embedded in growth that destruction of the secreting epithelium would appear to have been not far distant. In the middle of the stomach the mucous membrane is very well preserved, the crypts with both acid and ordinary cell are intact,

whilst between contiguous crypts a loosely packed adenoid-like tissue, similar to the rest of the growth, exists (Pl. VI, fig. 1).

FIG. 67.

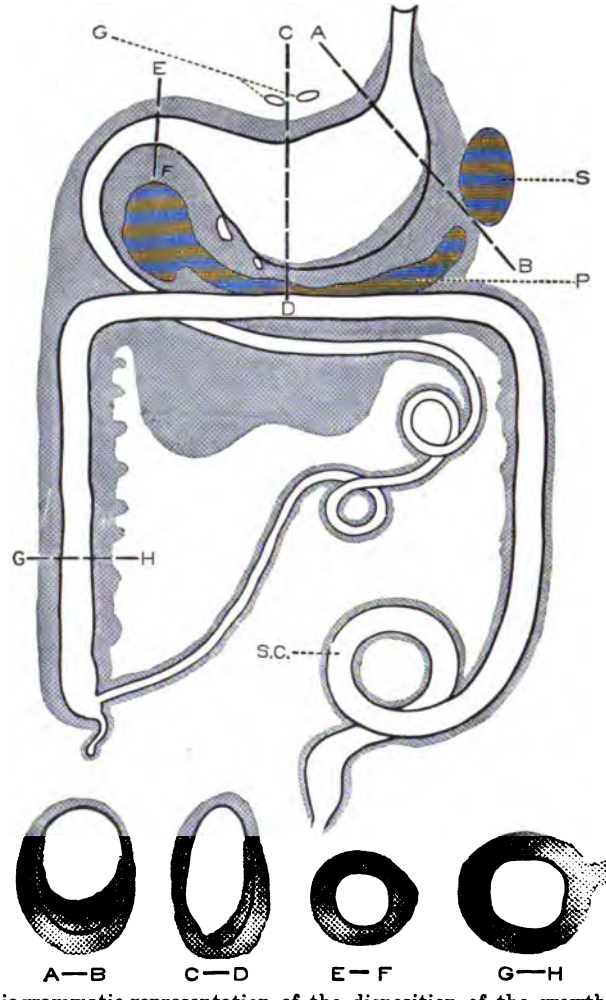

A diagrammatic representation of the disposition of the growth in Case 2. The dark line represents the muscularis mucosæ, and the shading the growth. S. Spleen. P. Pancreas. S.C. Sigmoid colon. A B, C D, E F, G H, are diagrammatic sections through the portions of the alimentary tract marked by the interrupted lines bearing the same letters. The left side in all four sections represents the anterior surface.

The stomach wall was thickest at the point of attachment of the spleen, where it measured 1½ inches: from here the in-

filtration spread towards the pylorus along the greater curvature, involving the posterior rather than the anterior surface. A thin but continuous spread of the infiltrating growth existed from the stomach to the small gut, where its thickness increased, and it was continued thence to the rectum (Fig. 67).

Microscopically it is seen that the main development of the growth in the stomach is in the areolar tissue between the muscular coats and the muscularis mucosæ. In the small and great intestine the mucous and submucous coats are free whilst the serous is infiltrated.

The microscopical appearances (Pl. VI, fig. 4) of the growth are remarkably uniform. It consists of small round cells, with large nuclei and almost no cell body, contained within a fine reticular stroma. The stroma is almost identical with that of a lymph gland, except that one misses the large endothelial cells that rest on the reticular framework. The latter, however, are a very variable quantity even in normal glands.

The individual cells of the growth differ from the lymphocytes of normal lymphatic tissue in being somewhat bigger, and not all absolutely round; whilst the protoplasm, though usually minimal, is occasionally present in considerable quantity. The nuclei are often deeply indented at one spot on their circumference. Cells with more than one nuclei are but rarely met with. Mitoses are rare, and although the nuclei are very rich in chromatin it is surprising how relatively few examples one finds. The cells are probably not so highly differentiated as the normal lymphocyte. The contrast between the normal lymphocyte and the tumour cell is very well seen when one compares the lymphoid follicles of the large intestine, which are not swollen, with the infiltrating growth of the serous coat of the same.

The enlarged follicles of the intestine, which in the majority of cases are bounded by a sheath derived from the muscularis mucosæ, possess cells which, both in size and appearance of their nuclei, are in a condition between those of the small follicle and those of the growth in the serous coat.

The muscular coat in the parts of the stomach wall most affected is much damaged, its fasciculi being split in all directions and some doubtless atrophied by pressure; in the remainder of the stomach the muscularis is but little affected, though between the main bands of muscle-fibres collections of tumour-cells are

seen. In the small and large gut, where the whole weight of the infiltration has fallen on the serous coat, the muscle coat has been almost entirely spared.

The condition of the enlarged lymph glands is extremely puzzling. No tumour infiltration *en bloc* is to be seen, nor do the cells differ much from the normal except that, on the whole, they are somewhat bigger and the nuclei are often indented. The structure of the gland, however, is much altered, the distinction between medullary and cortical tissue is lost, germ centres (Keimzentren) are here and there still recognisable, but do not help to make the striking picture that the normal gland should.

The gland seems to contain so great an increase of lymphocytes that its normal structure is partly hidden and partly replaced by their presence.

The glands are bound together by a fibrous adenitis, and are embedded in an adipose tissue which is itself infiltrated with growth and has exactly the same histological structure as the appendices epiploicæ. The cells of the growth in the adipose tissue are so similar to many in the gland that it is impossible to state whether the two are morphologically distinct; what differences can be made out suggest rather that the cells of the gland have retained more distinctly the true lymphatic type than the cells of the infiltrated tissue, which are somewhat larger and more irregular.

The case would thus seem to be one of diffuse lymphosarcoma beginning in the submucous coat of the cardiac end of the stomach, and spreading thence through the lymphatic channels of the serous coat throughout the whole of the gut.

Careful dissection of the abdominal organs showed that though the growth probably arose in the submucous coat of the stomach it was by no means limited to this position, and it passes from mucous to submucous, and thence to the muscular and serous coats, involving at the cardiac end of the stomach all of them, at the middle of the greater curvature all three behind, and only serous and muscular coats in front (Fig. 67), whilst in the small, and more especially in the large gut, the growth limits itself to the serous coat with only slight involvement of the muscular.

This fact, viz. the variation in one and the same case of the actual distribution of the growth, weakens the classification

adopted by Newton Pitt, in which round-celled growths in the submucous layers are designated lymphadenomata, and those involving all or the muscular and serous coat are lymphosarcomata. I have examined, thanks to the courtesy of Dr. Newton Pitt, all the sarcomatous growths in Guy's Hospital Museum of stomach and intestine, both macro- and microscopically, including the case referred to in (26), and I have been able to satisfy myself that all the lymphadenomata so called are really lymphosarcomata (App. I), and that most of the "sarcomata" are the same except one (App. IV), which is similar to Case No. 1 here described.

My second case is an almost typical example of Kundrat's lymphosarcomatosis or diffuse lymphosarcoma, of which he has collected so many examples, and the definition of which I shall give later when discussing the classification of sarcomata of the stomach. This type of growth is not limited to the stomach for its origin. It may begin in a set of glands, preferably the mesenteric, rarely the axillary, or it may still more commonly start in the pharynx and spread downwards. Common to all examples is the tendency exhibited by these growths, once they have gained a footing in the intestinal tract, to spread along it, causing dilatation of the lumen.

In not all cases is the spread so obviously continuous; thus in Newton Pitt's case (26) the growth spread continuously from cardia to the second part of the duodenum, but in the intestine there were numerous polypoid submucous growths, whilst around the appendix was a mass of growth the size of an apple.

In a case in Guy's Museum (App. I) the main growth was in the intestine, but there were several other patches in the gut. Specimen 936 of Guy's Museum is another example of multiple invasion of the gut by lymphosarcoma.

Although the cases just cited are examples of apparently multiple discrete lymphosarcomatous infiltrations of the walls of the intestinal tract, it is quite possible that they are connected by continuous chains of lymphatics.

The Peyer's patches and lymph follicles of the gut are not picked out in lymphosarcomatosis of the gut and converted into isolated tumours, as was found in Case 1 and the class of growth it represents. This fact was pointed out by Kundrat, and it seems to be generally true. It was very striking in Case 2 to

[illegible]

[illegible]

[illegible]

notice the entire absence of swelling in all the follicles or lymph patches in the intestines, although the serous and muscular coats were loaded with lymphosarcomatous elements.

That the lymph follicles and Peyer's patches are not involved in Case 2, and the fact that they are in all cases but rarely so, would seem to suggest that lymphosarcomatosis is in reality an infective process, which spreads from its origin by the most direct lymph paths to other lymph stations, and that as the follicles of the intestine subserve the functions of the mucous membrane and not of the serous coat, they are not on the direct path of infection, and hence escape. Similarly the sequence of the involvement of the remaining lymphatic glands of the body when the disease has begun in the neck or axilla is an orderly one following the nearest and easiest paths, crossing to the opposite side by means of the mediastinal or mesenteric groups. In short, whatever may be the *causa causans* of lymphosarcomatosis it is not one which at its inception affects all glands alike.

A consideration of the pathological relationships of the growths represented by Cases 1 *and* 2.

In case 1 it is necessary to define the primary seat of the disease as well as its nature.

The colossal size of the cœliac glands fused together and indissolubly blended with the stomach makes it highly probable that the disease began in the glands rather than in the stomach itself. For in a case reported by Thursfield (34), which is undoubtedly a local primary round-celled sarcoma of the stomach, the glands are not affected at all; in my case, moreover, although the growth in the stomach was of such great proportions, nowhere except at the attachment of the cœliac glands was the serous membrane transgressed. Features in the histological picture, which will be considered in detail later, also lend support to this view. Tilger (35) recognised and defined the characters of a group of sarcoma of the stomach which arises from the lymph glands without; as discriminating characteristics he gave the following:

(1) The secondary sarcomata of stomach are much more malignant.

(2) Many organs are affected.

nph
oats

ved
so,
an
nost
the
ous
rect
of
ody
rly
the
ps.
na-
nds

ls

he

nd
ole
ch
n-
h,
gh
re
n-
h
w.
of
ls
g:
re

EXPLANATION OF PLATE VI,

Illustrating Dr. R. N. Salaman's communication on "Sarcoma of the Stomach," p. 296.

FIG. 1.—Case 2. A transverse section of the stomach wall from the centre of the greater curvature. The tumour-cells infiltrate mainly the submucous tissues, but have in some places penetrated the muscularis mucosæ, and come to be in the supporting tissue between the gland acini. The glandular tissue in the oxyntic cells is well preserved. There is some thickening of the serous coat. Hæmatoxylin and eosin. Zeiss, oc. 2, obj. āā.

FIG. 2.—Case 1. A section from the stomach wall close to that part of the lesser curvature where the wall and the cœliac glands have fused. The majority of the tumour-cells are mononuclear polymorphous cells; amongst them occur large mono- and polynuclear cells, some in stages of division. These cells, both in their shape and staining reactions, resemble endothelial cells. The cells lining the capillaries are distinctly differentiated from the cells making up the main mass of the growth. The stroma here is composed only of cell processes. Methyl green and pyronin. Zeiss, oc. 6, obj. $\frac{1}{12}$ apoch.

FIG. 3.—Case 1. A section of the stomach wall, from the greater curvature. The large endothelial-like cells are well shown. Some of them in the pale nuclei seem to be degenerate. The stroma, except in the immediate vicinity of the capillary, is made up of the processes of the tumour-cells. Heidenhain's hæmatoxylin. Zeiss, oc. 6, obj. $\frac{1}{12}$ apoch.

FIG. 4.—Case 2. A section from the stomach wall showing the typical lympho-sarcomatous structure of the growth. The reticulum is made up of stellate cells with long processes which form a meshwork in which lie the small round cells. Hæmatoxylin. Zeiss, oc. 6, obj. $\frac{1}{12}$ apoch.

FIG. 5.—Case 2. A section from the small polypi of the intestine shown in Fig. 65. The appearance of the large endothelial cells, some containing cell inclusions, the polymorphous cells of the growth, and the characteristic cells of the capillary walls, are similar to those seen in Figs. 2 and 3. To be noted is the appearance of traces of a true stroma derived from the pre-existing areolar tissue of the lymphatic node in which this sarcomatous growth has been implanted.

[illegible]ION OF PLATE VI

[illegible]

[illegible]

[illegible] close to that part of the [illegible] glands have [illegible] polymorphous cells; [illegible] in stages of [illegible] reactions, [illegible] are distinctly differentiated from the [illegible] of the growth. The stroma here is composed [illegible] pyronin. Zeiss, oc. 6, obj. [illegible] apoch.

[illegible] stomach wall from the greater curvature [illegible] shown. Some of them in the pale nuclei [illegible] except in the immediate vicinity of the [illegible] up of the processes of the tumour cells. Heidenhain's [illegible] 6, obj. [illegible] apoch.

[illegible] A section from the stomach wall showing the typical [illegible] structure of the growth. The reticulum is made up of [illegible] which form a network in which lie the [illegible] Zeiss, oc. 6, obj. [illegible] apoch.

[illegible] A section from the small polypi of the intestine [illegible] of the [illegible] cells, some containing [illegible] of the growth, and the characteristic cells [illegible] are similar to those seen in Figs. 2 and 3. To be [illegible] of tissues [illegible] derived from the preexisting [illegible] of the [illegible] this sarcomatous growth [illegible]

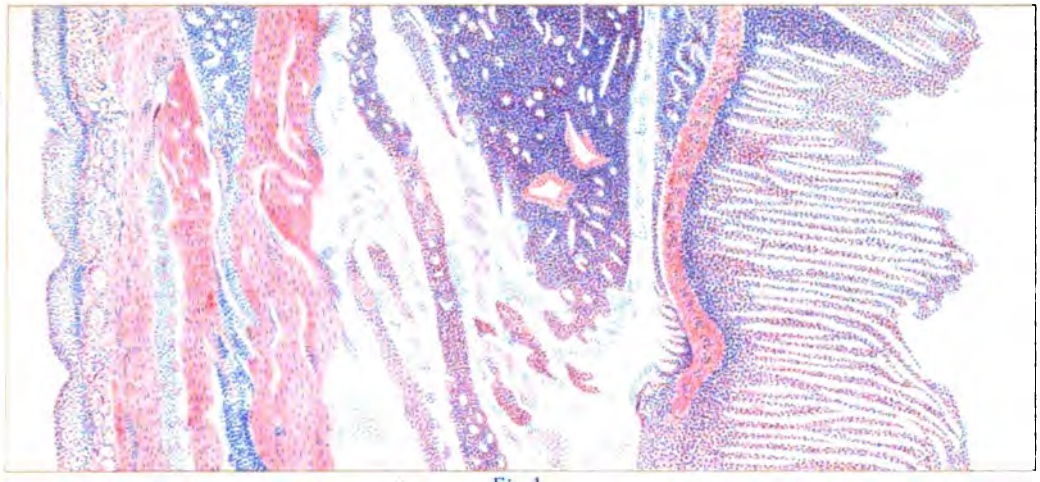

Fig. 1.

Fig. 2.

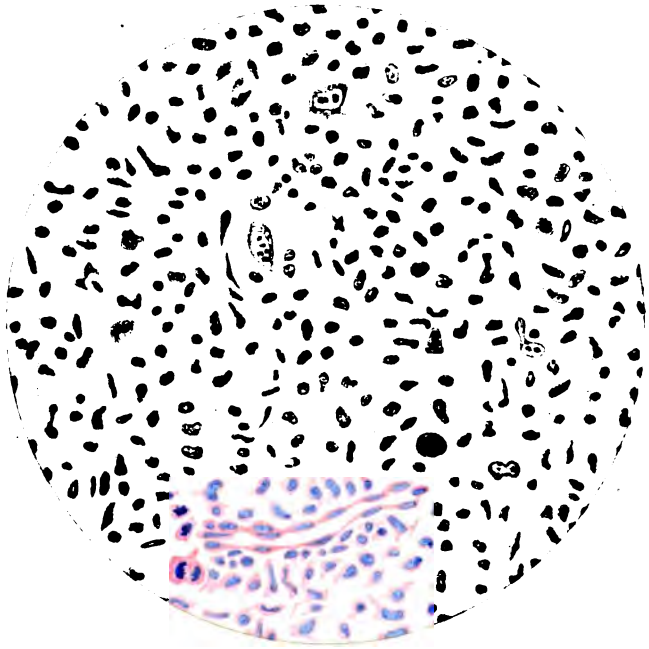

Fig. 3.

Fig. 4.



Fig. 5.

(3) Extensive ulcerations of stomach mucous membrane occur.

(4) More than one focus of growth can be demonstrated in the stomach, and whilst the cœliac glands are greatly hypertrophied, with primary sarcoma it is rarely the case. All these features are possessed by Case 1. The intestines, many groups of glands and the tonsils have suffered, the mucous membrane of the stomach was largely lost through ulceration, and the stomach growth was a composite one, as can be seen in Fig. 63 and Fig. 64, while the malignancy of the tumour, as judged by the destruction of normal tissue, size of growth, rupture into a great vein, and extreme cachexia, could hardly be exceeded.

Tilger has grouped this type of sarcoma of stomach together as primary lymphosarcoma of retro-peritoneal glands; we shall see later that the name "lympho-sarcoma" as here applied is not happy, and that it is best used to designate a quite different type of tumour formation; but that Tilger has isolated a pathological species investigation both into the literature and into all available specimens besides the two new cases here given amply proves. I have appended (App. IV) a list of the cases in the literature which belong to this group. Many of these I have personally examined both macro- and microscopically.

Before considering the values of the histological characters of the growth, it will be advisable to clear the ground by defining the meaning which in this paper is attached to the various terms applied to lymphatic tumours which are so often used interchangeably, and which have led to nothing but confusion in the discussion of lymphatic tumours.

Lymphosarcoma, if we accept the histological and biological characters of it as given by Kundrat (19), becomes a real and definite pathological entity; but it is not only because in my own opinion I believe his definition to be a sound one, but also because in working independently through a large number of mediastinal growths as well as sarcomata of stomach and intestines, application of Kundrat's definition does when followed lead to a satisfactory classification of these very difficult growths, that I have taken it as a standard to work by.

Kundrat defines lymphosarcoma as a growth composed of lymphoid cells in a fibrillar meshwork; and either cells or meshwork may be in excess, giving rise to medullary or fibroid forms. He adds the following characteristics:

Lymphosarcoma infiltrates without restraint, differing from the leukæmic and pseudo-leukæmic growths. Lymphosarcoma may start in the follicle of a mucous membrane or a lymphatic gland, and the one may infect or be secondary to the other.

Lymphosarcoma in an intestinal organ chooses the readiest paths for its further propagation, spreading in muscular and serous, as well as by submucous coats, and never causing constriction. Peritoneum, omentum, and appendices epiploicæ are often distended with growth.

Lymphosarcomata never shows those degenerative changes common to leukæmic and pseudo-leukæmic growths.

The diffuse infiltrations of or nodular deposits in liver, kidney, or spleen found in pseudo-leukæmia and leukæmia are here never seen.

The secondary deposits are not true metastases, because there is always a continuous chain of growth from one deposit to another; and the deposits occur just in those places apart from serous membranes where true metastases are so rare.

The bone marrow rarely shows changes, and is rarely the seat of secondary deposits.

The age limit according to Kundrat is from 25 to 53, whilst men are affected twice as often as women; both of these later statements I venture to think will require amendment.

Tuberculosis allied with lymphosarcoma is very rare, and when it occurs different glands are affected, whereas in leukæmia the two processes are frequently combined.

Lymphosarcoma most commonly begins in the glands of neck or axilla, through frequently primary in the pharynx. It is by reason of its excessive process of growth practically a generalised disease of the lymphatic system.

Of leukæmic and pseudo-leukæmic growths I can nowhere find an histological analysis which is trustworthy. Besides the properties already enumerated which they in contrast to lymphosarcomata possess, it may be taken as generally true that the enlarged glands of leukæmia do not increase beyond the limits of their capsule nor do contiguous glands fuse. I have, however, examined one case of clinically established lymphatic leukæmia where the glands have fused and formed a solid mediastinal mass which seemed to possess most of the malignant properties of lymphosarcoma. In leukæmia diffuse

lymphatic growths are most common in liver, kidney, and spleen, as well as occasionally in the marrow. The lymphatic deposits in the organs are variously regarded as true metastases by Ehrlich and Lazarus, whilst Pinkus and Benda regard them more logically as being swellings of autocthonous elements. These views are discussed by Löwit (20) and Walz (39). Histologically the enlarged glands present a more or less normal appearance, the chief difference being the great increase in quantity of the germ centre material, which may equal or exceed in quantity that of the normal medullary substance. The reticular structures remain normal.

Pseudo-leukæmic growths are probably not all histologically akin. Many pseudo-leukæmias are cases of general glandular enlargement whose blood picture only differs in quantity from that of true chronic lymphatic leukæmia. Pappenheim (27) considers the one differs from the other merely by the involvement or not of the bone marrow. Pinkus divides pseudo-leukæmias into (1) those in which the multinuclear elements are diminished, with a relative though perhaps slight increase of lymphocytes; the difference between this form and lymphatic leukæmia is only quantitative; (2) those in which there is no blood change, and the growths have the characters of malignant tumours.

The first division becomes practically leukæmia, whilst the second is lymphosarcoma.

The classification of Pinkus illustrates the almost insuperable difficulties there are to overcome in the classification of the hypertrophies of the lymphatic system—difficulties which are not likely to be satisfactorily settled till some new pathological or physiological factor is discovered which may render a classification practicable. As a statement of facts, Pinkus' classification is sound, and cases occur in which the passage of the one into the other variety may be observed.

That the various lymphatic hypertrophies so far considered are closely related, although admitting of a certain, not too rigid, classification has been shown; but a personal examination of a large number of such cases has suggested that the differences exhibited clinically are physiological, and based on the stage of development of the lymph-cell forming the tumours; *e.g.* in some growths the cells are hardly to be differentiated at all from the ordinary finished lymphocyte, whilst in many others, generally

more malignant, they are similar to the lymphogonia of the germinal centres. In still other tumours, such as the one under consideration, the cells possess more protoplasmic body and are more irregular in shape than the lymphogonia, and although possessing a distinct resemblance, are more active and conceivably developmentally younger than the latter. It would appear probable that the terrible malignancy of this class of tumour (App. IV) might be correlated with these facts.

Recently Banti (3) has published his views on leukæmia in general, and as they throw some light on the questions here dealt with, I shall venture to give a short account of them.

Banti considers both myeloid leukæmia and lymphatic, with its congener pseudo-lymphatic, leukæmia to be a true tumour development, a sarcomatosis, of medullary and lymphatic elements respectively. The presence or absence of the specific elements, their sudden appearance, and their equally rapid disappearance in the blood, are due to the erosion of the endothelial lining of the veins or to their subsequent thrombosis. Such erosions he has observed in the lymph glands of lymphatic leukæmia and the marrow vessels in the myeloid variety.

Banti further puts forward evidence concerning the nature of the cells which support the same views, showing that what is often taken for a lymphocytosis may only be a surcharge of sarcoma cells (Carrington, App. IV).

Should this theory be proven, it will do very much to bridge over the many difficulties of classification, and it may be possible to regard lymphatic leukæmia as pseudo-leukæmia with eroded blood-vessels; Kundrat's lymphosarcomatosis (Case 2) as pseudo-leukæmia with continuous spread by the lymphatics only; whilst myeloid leukæmia differs from the above only by the fact that its place of origin, and hence its cells, are different.

In support of the sarcomatous view of myeloid leukæmia Banti quotes a case where, besides the not unusual appearance of myeloid cells in the liver, spleen, and glands, there was extensive myeloid infiltration of the serous coat of the stomach and intestines.

Another general disease of the lymphatic system is one known as lymphadenoma. Amongst surgeons this name is often loosely applied to almost any glandular enlargement, especially in the neighbourhood of the neck, which is not obviously tuberculous.

Many intestinal growths have been described as lymphadenoma which are really lymphosarcoma; this is all the more to be regretted as lymphadenoma is probably the only type of lymphatic enlargement which possesses a thoroughly definite histological and a fairly uniform clinical picture. Clinically the disease is one of youth and early middle-age; it begins by the gradual, though occasionally rapid, enlargement of a gland or group of glands. The axillary glands are often the earliest to be affected; the disease may be limited to the one group, or several groups in all parts of the body may follow suit. The spleen is not often affected. As far as I can gather, the intestinal tract is never affected by lymphatic growths possessing the histological characters of true lymphadenoma, as one finds it to be by lymphosarcoma. I have, however, examined a case which, starting in the glands of the neck, gave rise to a large mediastinal tumour, which had all the naked-eye appearances of a lymphosarcoma and had invaded the pericardium and tissues at the base of the heart.

The glands affected remain for a long time usually discrete and soft, others tend to coalesce and infiltrate the surrounding tissues, becoming very hard and fibrous; whilst a third variety, owing to the most extensive hyaline degeneration of the fused and infiltrating glandular growth, present the appearance of a mass of molten wax poured into the tissues.

I have not been able to find in the accounts of cases any information which would suggest a specific blood condition correlated with the disease.

The histological features of lymphadenoma have been very carefully described by Andrews (1), who, however, has somewhat detracted from the value of his paper by stating that he is talking of what is clinically known as Hodgkin's disease; whilst Osler under "Hodgkin's Disease" gives as synonyms pseudo-leukæmia, general lymphadenoma, and adenie. It will be seen that, from the histological features described by Andrews himself, the disease is different from any of these, and that Hodgkin's disease cannot be considered as a pathological entity, but merely a clinical description, which, like an adjustable frame, can be made to include nearly all the enlargements to which the lymphatic glands are prone.

Andrews analyses the histological features of lymphadenoma as follows:

(*a*) There is a loss of all germ centres.

(*b*) A great diminution of lymphocytes.

(*c*) A greater or less increase of reticular structure.

(*d*) The presence of varying but large number of eosinophile corpuscles.

(*e*) The presence of a large number of very big cells containing one to four or even more nuclei.

In these cells mitoses are frequently seen; they closely resemble the large cells met with in many sarcomata, whilst they differ altogether from the giant-cells of tubercle.

If preparations of true lymphadenoma be stained by Pappenheim's stain, it is seen that these large cells have similar staining reactions to endothelium, and that, in addition, the gland contains large numbers of plasma cells. The latter may be found in normal lymphatic glands as well as in the peripheral portions of the glands of pseudoleukæmia, but I have not found them in such large numbers, nor in the very midst of the gland substance, as I have in lymphadenomatous glands.

It will be seen that neither the morbid, anatomical, nor the histological features of Case 1 coincide exactly with the conditions which I have detailed. In one important feature it differs from them all, viz., in its not only possessing the properties of infiltration, but also that of destroying and boring its way through vessel walls, as in the case of the inferior vena cava. This feature alone suggests that it is a true sarcoma. The absence in the greater part of the growth of stroma tends in the same direction, as does also the character of the cells, which, though possessing many points of resemblance to the lymphocytes or lymphogonium, are more polymorphic.

On the other hand, the growth has characters which are not usual in the ordinary round-celled sarcoma; such are the perfectly developed endothelial lining to its vessels and capillaries, and the presence of a large number of very large cells distinct from those which go to form the tumour as a whole.

The large cells (Pl. VI, figs. 2, 3, 5) with their big nuclei, generally single, though sometimes amounting to four or even more, recall at once the characteristic cells of lymphadenoma.

The involvement of the tonsils and cervical glands, besides

the growths in the alimentary canal also suggests the distribution of a general disease of gland tissue.

I would suggest, therefore, that one has in this case to deal with an example of a sarcoma of lymph gland which possesses many features reminiscent of its place of origin on the one hand and of a well-defined disease (histologically) of its place of origin on the other, viz. lymphadenoma; that it is a secondary lymphadenosarcoma.

A specimen in Guy's Museum (App. IV) resembles almost exactly Case 1. There one finds a large mass of cœlic glands and a sarcomatous infiltration of the duodenum as well as of the stomach. Microscopically the two growths seem to be identical.

Another specimen (London Hospital Museum, 1118) of which the stomach and cœliac glands alone are preserved differs only from Case 1 by a somewhat less involvement of the stomach. The specimen is some thirty years old, and there is no reference to its history. Microscopical examination was, owing to insufficient fixation, not fully satisfactory. There was, however, evidence of the presence of large endothelial-like cells in the growth besides the round somewhat large lymphocyte-like cells which formed the bulk of the tumour.

I have in App. IV given a further list of cases from the literature, which, from the description, I take to be cases of a similar nature both in their naked eye as well as microscopical features. Besides the types of sarcoma of stomach represented by Cases 1 and 2, there are two others, viz. (*a*) round-celled sarcoma of the submucous tissues of the stomach. (*b*) polypoid sarcomatous tumours (fibro- and myosarcomata). These two types I will briefly describe:

Round-celled sarcoma of the submucous tissues.

A typical case is described by Dr. Thursfield (34), through whose courtesy I have been able to examine both stomach and sections. The case was that of a boy aged 3 years and 9 months.

The duration of the illness was three and a half months. A tumour in the left hypochondrium and swelling on the left side of the neck at the level of the thyroid and over the ascending ramus of the jaw were noticed. There was excessive anæmia, but no wasting.

Post mortem the stomach was found to be very much enlarged, the walls irregularly hypertrophied and thrown into deep folds, so that in the posterior and parts near the lesser curvature they were as much as one inch thick. There were no hæmorrhages, nor did there appear to be any ulceration. The pylorus and cardia were free from growth. There was no enlargement whatever of the retroperitoneal or mesenteric glands. There was a secondary nodule in the kidney and in the transverse mesocolon.

Histologically the tumour was composed of mononuclear round cells about the size of polynuclear leucocytes. There were no large cells as seen in Case 1.

The stroma was extremely scanty and had no resemblance to lymphoid reticulum.

In the kidney the secondary growth spread between and destroyed the tubules; here also were no large cells, and almost no recognisable stroma.

In Appendix II I have grouped together four cases which are apparently of this type. The case described by Brooks (7) as secondary to a gunshot wound of the stomach is of special interest, as the tumour originated in the scar tissue. It was definitely submucous, and gave rise to no enlarged glands.

Histologically it was composed of round cells, but with no lymphatic stroma.

The case described by Morton (21) of a sarcomatous infiltration of the whole stomach, which extended beyond the pylorus and involved no glands, was successfully removed, the patient being alive two years later. The case should, although Morton describes it as round-celled sarcoma, be placed, I think, from the description given of it, amongst the lymphosarcomata.

Török's case (36), though described by him as lymphosarcoma, I have placed provisionally in the class of round-celled sarcomata.

In the Museum of St. Bartholomew's Hospital is a specimen of a tumour about the size of an orange projecting into the lumen of the stomach from the lesser curvature. It has the histological appearances of a round-celled sarcoma with no large cells, and there are no enlarged glands in the lesser omentum.

Round-celled sarcoma of the stomach is therefore a growth arising in the tissues of the stomach wall itself, and is limited to that organ. Its growth is limited by the pylorus. Glands

enlarged secondarily occur very late, if at all, whilst secondary deposits in the organs as seen in Thursfield's case follow the ordinary course of sarcomatous metastases.

Histologically they appear to be similar to the ordinary round-celled Sarcomata, and to be very deficient in stroma.

Polypoid sarcomata. Fibro- and myosarcomata.

This last class of sarcoma of the stomach is one which, owing to its lesser malignancy, is scantily represented in the literature, and I have so far been able to collect but eight cases.

Herman's (17) case of a woman aged 60 years, who upon the diagnosis of a twisted ovarian was operated on, is a good example of this type. Herman found a tumour larger than a child's head hanging into the abdominal cavity by a pedicle from the greater curvature. It was removed, and six months later the patient was well. Dr. Bulloch, who examined the growth, described it as a myxomatous fibrosarcoma.

All the cases of polypoid tumours have been from the greater curvature, and they have all projected outwards, except that of Tilger (35), where part of the growth projected in a polypoid manner downwards and outwards, whilst the remainder projected within the viscus.

In all the examples of this class the tumours have undergone more or less extensive myxomatous degeneration. In Virchow's (37) and Hinterstoiser's (18) cases this myxomatous change had induced a cavitation of the growth, and these cavities had become continuous with the mucous membrane secondarily. In all, the mucous membrane is but slightly affected, and that mechanically.

Two cases have been operated on, Herman's and Cantwell's. The latter recurred after eight months.

The fibrosarcomata and myosarcomata of the stomach arise in the muscular and serous coats as opposed to the other types which arise in the submucous. It is possible that the small fibromata and myomata occasionally met with may form the starting-point of many of these tumours.

Virchow's (37) and Bradowsky's cases (6) are myosarcomata.

Included in the literature is a case of Hadden (15), which he has called sarcoma of the stomach, and which in its macro-

scopical characters resembled Case 1. The description of the histological appearances of the growth, however, make it almost certain that it is a perimelioma.

Conclusions.

As a result of the investigations as embodied in this paper, it would appear that sarcoma of the stomach is neither a very rare nor a simple disease; above all, it is clear that there are several divergent types of the disorder. It would be idle to draw a picture of the clinical characters of the disease. Fenwick has attempted to do so, but the result is merely to show that while a large percentage of cases are practically symptomless the rest cannot be distinguished from carcinoma of the stomach.

Reviewing the question of the clinical signs and symptoms from the point of view of the different types of the disease, it is quite possible that, could one get sufficient clinical histories, a very satisfactory analysis could be made. It is evident, *e.g.* that the lymphosarcomata that do not ulcerate will give very different signs and symptoms from the sarcomata that do, whilst it is most probable that the polypoid growths exert only mechanical effects.

The classification I would suggest of sarcomata of the stomach is:

1st. Lymphosarcomata of Krundat's type.

2nd. Round-celled sarcomata.

3rd. Polypoid fibro- and myosarcomata.

4th. Sarcomata of the retro-peritoneal glands directly invading the stomach, a type of growth which might, were not an increase in the nomenclature of neoplasms best avoided, be termed a secondary lymphadenosarcoma.

APPENDIX I.—*Lymphosarcoma of the stomach, Kundrat's type.*

Name of Author.	Reference to Bibliography.	Sex.	Age.	Remarks.
Sidney Coupland	33	F.	24	Enlarged glands everywhere with subcutaneous nodules; masses of growth in submucous tissues of stomach extending into duodenum; ovaries and kidneys likewise infiltrated.
Cruvelhier	10	M.	41	Diffuse infiltration of submucous tissues of stomach which spreads over into duodenum. Many of follicles and Peyer's patches enlarged; all glands slightly enlarged, also spleen.
Dock	12	M.	39	Infiltration of entire stomach wall and pylorus of a nodular type. No glands and no constriction of pylorus.
Guy's Hospital	Museum No. 750	M.	36	Nodules of submucous growth in stomach, duodenum and ileum.*
Kundrat	19	—	—	Starting in larynx, spread to stomach.
Morton	21	M.	39	General diffuse infiltration of stomach extending over into first part of duodenum. No glands.
Newton Pitt	26	M.	48	Submucous growths in stomach; polyp-like growths in intestine; large mass round appendix. General glandular enlargement; enlarged spleen.
Guy's Hosp. Perry & Shaw	28, Case 47	F.	18	Infiltration of pyloric end of stomach and duodenum.*
Guy's Hosp. do.	do.	M.	15	Infiltration of submucous tissues of pyloric end of stomach and duodenum.*
Pstrokowski	31	M.	34	Blood. Red c. 1,500,000. White c. 18,000. Hæmoglobin 20 per cent. Diffuse submucous infiltration, especially of lesser curvature. No enlarged glands.
Salaman	Present Communication.	M.	51	Case 2.*
Wickham Legg	40	F.	17	The growth invaded the pyloric end of the stomach and spread into the liver and omentum. The glands were enlarged, but said not to contain growth.

* Sections and specimens examined personally.

APPENDIX II.—*Round-celled sarcomata of the stomach.*

Name of Author.	Reference to Bibliography.	Sex.	Age.	Remarks.
St. Bartholomew's Museum	Museum Catalogue (Spec. 1928)	—	—	A massive tumour projecting into the stomach from the lesser curvature. No enlarged glands.*
Brooks	7	M.	67	Sarcomata found in old bullet wound of stomach.
Thursfield	34	M.	3¾	Much enlarged, most extensively infiltrated stomach. Some ulceration. No enlarged glands or spleen. Secondary nodule in the kidney.*
Török	36	F.	21	Stomach removed by operation. Alive and well six months later. This may be a case of lymphosarcoma.

APPENDIX III.—*Polypoid fibro- and myosarcomata.*

Name of Author.	Reference to Bibliography.	Sex.	Age.	Remarks.
Alessandri	2	F.	53	Enormous polypoid tumour hanging from the greater curvature. Successfully removed.
Bradowsky	6	M.	57	A 14-lb. tumour hung from greater curvature. Mucous membrane above it ulcerated and infiltrated. Mixed round-celled and myomatous sarcoma with myxomatous degeneration.
Cantwell	9	F.	52	A tumour weighing 12 lb. removed from the posterior wall of greater curvature. Fibro-myxosarcoma.
Herman	17	F.	60	Large pendulous tumour of greater curvature removed. Fibrosarcoma.*
Hinterstoiser	18	F.	42	Large fibrocellular growth with extensive myxomatous degeneration forming cysts communicating with the stomach.
Tilger	35	F.		Pendulous tumour whose proximal part projected into the greater curvature of the stomach. Fibrosarcoma.
Virchow, two cases	37 and 38	—	—	Polypoid myosarcomata with advanced myxomatous degeneration.

* Sections and specimens examined personally.

APPENDIX IV.—*Sarcoma of the retroperitoneal glands directly invading the stomach.*

Name of Author.	Reference to Bibliography.	Sex.	Age.	Remarks.
Carrington . . .	8	F.	55	Blood. Red. corp., 4,720,000; white corp., 20,296. Glands left side of neck mediastinal and cœliac much enlarged. Spleen enormous; all follicles in gut much enlarged.
Coupland . . .	33	F.	25	The glands were enormous and confluent; besides the stomach the walls of the gut were infiltrated. In the gland mass were numerous large cells in a medley of round cells.
Cayley . . .	9A	M.	57	Glands very much enlarged—the histological description is primitive.
Guy's Hospital . .	Museum, No. 751.	M.	38	There is a large mass of retroperitoneal glands which involve mainly the first part of duodenum. Histologically similar to Case 1.*
Handford . . .	16	M.	74	Enormous cœliac gland mass in which vessels were imbedded as in Case 1. The stomach wall was extensively infiltrated, but the growth stopped short at the sphincters.
Salaman . . .	Present Communication.	M.	42	Case 1, p. 297.*
Tilger . . .	35	—	—	This tumour is described as being definitely primary in the glands.
London Hospital .	Museum, No. 1118.	—	—	No history. Large mass composed of cœliac glands with continuous infiltration of the lesser curvature and posterior wall of the stomach. Microscopically round-celled growth with some large cells.

APPENDIX V.—*Sarcoma of retroperitoneal glands involving parts of the alimentary canal other than the stomach.*

Name of Author.	Reference to Bibliography.	Sex.	Age.	Remarks.
Moore (Norman) .	23	F.	41	Enlarged mesenteric glands with direct infiltration of the duodenum.
Moxon	25	M.	30	Enormous retroperitoneal glands of the abdomen which surrounded and invaded the small intestine at several places, producing constriction.

* Sections and specimens examined personally.

REFERENCES.

1. *Andrews and Butlin.*—'Trans. Path. Soc.,' 1901, vol. xxxii, p. 297.
2. *Alessandri, R.*—'Mittl. Aus. den Grenzgeb. d. Med. u. Chir.,' 1903, Bd. xii, Heft 4.
3. *Banti.*—'Pathlog. Centralblatt.,' Bd. xv, No. 1, s. 1.
4. *Borrman.*—'Lubarsh and Ostertag.,' vii, s. 9833.
5. *Borst.*—'Die Lehre. v. den Geschwülsten,' p. 474.
6. *Bradowsky.*—'Virch. Arch.,' 1876, Bd. lxvii, s. 227.
7. *Brooks.*—'Med. News,' 1898, vol. lxxii, p. 617.
8. *Carrington.*—'Trans. Path. Soc.,' 1884, vol. xxxv, p. 386.
9. *Cantmell.*—'Annals of Surgery,' 1899, vol. ii, p. 596.
9A. *Cayley.*—'Path. Soc. Trans.,' 1869, vol. xx, p. 171.
10. *Cruveilhier.*—'Atlas,' vol. xxxiv, Pls. 2 and 3.
11. *Daniels.*—'Virch. Arch.,' Bd. clxv, s. 238.
12. *Dock.*—'Trans. Assoc. Amer. Phys.,' 1900, pl. 65.
13. *Fenwick, Soltau.*—'Cancer and Tumour of the Stomach,' 1902.
14. *Fenwick, Soltau.*—'Lancet,' 1901, p. 463.
15. *Hadden.*—'Trans. Path. Soc.,' 1885, vol. xxxv, p. 234.
16. *Handford.*—'Trans. Path. Soc.,' vol. xl.
17. *Herman.*—'Trans. Obstet. Soc.,' 1902, vol. xliii.
18. *Hinterstoiser.*—'Wiener Medizinsche Wochenschrift,' 1885, No. 5.
19. *Kundrat.*—'Wien. klin. Wochen.,' 1893, Nos. 12 and 13.
20. *Löwit.*—'Lubarsch and Ostertag.,' Jahrg. vii, p. 43.
21. *Morton.*—'Brit. Med. Journ.,' 1889, vol. ii, p. 1083.
22. *Morton.*—'Brit. Med. Journ.,' 1901, vol. i, p. 1338.
23. *Norman Moore.*—'Path. Soc. Trans.,' vol. xxxiv, p. 99.
24. *Moser.*—'Deutsch. med. Wochen.,' 1903, p. 809.
25. *Moxon.*—'Path. Soc. Trans.,' vol. xxiv, p. 101.
26. *Newton Pitt.*—'Path. Soc. Trans.,' 1889, vol. xl, p. 80.
27. *Pappenheim.*—'Zeitschr. f. Klin. Med.,' 1900, Bd. xxxix, s. 171.
28. *Perry and Shaw.*—'Guy's Hospital Reports,' 1891.
29. *Pinkus.*—'Arch. f. Dermat. u. Syph.,' 1899, Bd. l, s. 1.
30. *Pinkus.*—Nothnagel's 'Spez. Pathol. u. Therap.,' 1901, Bd. viii, Teil 1, Heft 3, s. 1.
31. *Pstrokowski.*—'Zeit. Klin. Med.,' 1902, p. 160.
32. *Sydney Coupland.*—'Trans. Path. Soc.,' 1877, vol. xxviii, p. 127.
33. *Sydney Coupland.*—'Trans. Path. Soc.,' 1877, vol. xxix, p. 363.
34. *Thursfield.*—'Trans. Path. Soc.,' 1901, vol. lii, p. 61.
35. *Tilger.*—'Virch. Arch.,' 1893, Bd. cxxxiii, s. 183.
36. *Török.*—'Verhl. Deutsch. Gesell. Chir.,' 1892, vol. xxi, p. 102.
37. *Virchow.*—'Krankhaften Geschwülste,' 1864, Bd. iv, s. 130.
38. *Virchow.*—'Krankhaften Geschwülste,' 1864, Bd. xxii, s. 351.
39. *Walz.*—'Path. Centblatt.,' 1901, No. 23.
40. *Wickham Legg.*—'St. Bartholomew's Hospital Reports,' vol. lxxiv.

May, 1904.

25. *Calcifying chondrosarcoma of the breast.*

By Charles A. Morton.

The tumour was removed from a woman aged 64 years, who had only noticed it accidentally a month before removal. It felt very hard and heavy and somewhat lobulated, and occupied the outer and lower segment of the breast, just extending under the nipple, which was not retracted. I cut into it at the time of operation, and as the marked creaking under the knife seemed so typical of scirrhus, I removed the whole breast and the axillary glands and fat.

The tumour lies in the breast, and is round, and has a diameter of 1¾ inches. It is harder even than a scirrhus, as hard as cartilage, but it does not glisten. There are many areas of calcification in it, so that its section grates when the edge of the knife is passed over it. It is by nature of its hardness well differentiated from the surrounding breast tissue, but cannot, I think, be said to be definitely encapsuled. There is one very small lobe which is almost a separate growth, but of exactly the same character. The edge of this tumour is not as hard as the central portion. There are no areas of degenerative softening in it. A few axillary glands were enlarged, but a section of one shows no growth.

Fifteen months after the first operation a growth was noticed in the left gluteal region, and I removed a large nodule of cartilaginous calcifying growth of the same nature as the primary tumour from the skin in this region, and another of the same character from the underlying gluteal muscles. There was no connection between them. I hear that another growth formed two months later, on one of the fingers, and shortly after that she died, but the exact cause of death I do not know.

Microscopic sections show that the tumour is composed of round- and spindle-celled sarcoma with a mixture of cartilage and areas of calcification, which are found not only in connection with the cartilage but also in the areas of sarcoma-cells. In large areas the cartilage has a hyaline matrix, but in others there are masses of cells like cartilage cells crowded together without any matrix. In the secondary growth only a very few

areas of cartilage have any matrix, but there are large areas of cells resembling cartilage cells. The calcareous change in the secondary growth is not nearly as marked as in the primary. Indeed, no evidence of this is to be seen in the microscopic sections, but in the growth here and there calcareous areas can be detected. The cells in the primary growth are mostly spindle-shaped, but in the secondary growth the majority are round.

There are a few cases on record in which cartilaginous tumours of the breast were found—at any rate, no evidence of malignant growth was discovered in them. But in most of the cases of cartilaginous and osseous tumours of the breast the cartilage and bone have been combined with sarcoma. There is at least one record [1] of a case in which cartilage with areas of imperfect ossification was present in a carcinoma of the breast. In the records of some of the tumours described as ossifying sarcoma it is not clearly stated whether the microscopic structure of bone was seen or whether only areas of calcification were present, but in at least one the microscopic structure of bone was seen.

This specimen is, I believe, the fifth of the kind which has been shown at this Society. Mr. Bowlby in 1882 (vol. xxxiii, p. 306) showed a sarcoma of the breast containing small areas of cartilage, and in making microscopic sections small areas of calcareous material were also found. The areas of cartilage which were small appeared as "smooth glistening spots," and their cartilaginous structure was only apparent under the microscope. Mr. Durham in 1884 (vol. xxxv, p. 378) showed a sarcoma of the breast containing scattered masses of cartilage and a plate of bone. Mr. Battle's tumour shown in 1886 (vol. xxxvii, p. 473) consisted mainly of soft sarcoma, but contained an area of ossifying cartilage. A calcifying chondrosarcoma was shown by Mr. Bruce Clarke in 1890 (vol. xli., p. 229). The calcareous change was so extensive that part of the tumour had to be divided by a saw. *December 1st*, 1903.

Report by Members of the Council selected from those representing the Section of Morbid Anatomy.—We have examined the tumour of the breast shown by Mr. Morton, and agree

[1] Heurtaux, "Cancer Ostéoide du Sein," 'Mem. de la Soc. de Chir.,' t. vii, p. 1.

generally with his description of the macroscopic and microscopic characters.

The growth is a chondrosarcoma. Cartilage is present in a considerable amount and forms well-defined trabeculæ, the central portions of which are, in many places, undergoing calcification. Some of these trabeculæ are more fibrous in character and resemble those found in osteoid tissue, and the tumour as a whole bears a somewhat close resemblance to the osteoid sarcomata which are met with in bones. There is no evidence of the formation of true bone.

The cellular elements are chiefly delicate spindle cells and there are a few giant cells. There are a few small areas exhibiting mucoid degeneration.

H. Morley Fletcher.
C. Powell White.

---

26. *An unusual form of obstruction of the colon.*

By Charles A. Morton.

The portion of the transverse colon shown this evening formed a firm, sausage-shaped swelling, situated midway between the umbilicus and the left costal margin, and was the cause of chronic intestinal obstruction in a man, aged 27 years, who had suffered from vomiting and constipation for five months, and from attacks of pain, "as if his bowels were tied in a knot," for five years. At the time of the patient's death there was very marked distention of the transverse colon behind the obstruction, and to a less extent of the cæcum. Death occurred after an operation to establish intestinal anastomosis.

The part of the transverse colon which I show was the portion situated to the left of the umbilicus. It was firm, but not nodular, and the enlargement was uniform in the whole length of bowel involved. It measured six inches in length and one and a half inches in thickness, and felt exactly like an intussusception, but there was no sulcus formed by entering bowel. It was densely adherent to the descending colon. There was great

distention and hypertrophy of the right half of the transverse colon, the ascending colon, and the cæcum. There were old adhesions of the sigmoid to the left iliac fossa.

On laying open the thickened portion of colon, great hypertrophy of the muscle coat was seen, much greater than in the hypertrophied wall of the colon on the proximal side of the obstruction. There was also thickening of the peritoneum. The mucous membrane was thickened, honeycombed, and extensively separated from the muscle coat beneath, but not as a slough. This very extensive separation of the mucous membrane, without actual necrosis, is the most striking feature in the specimen. It seems likely that the honeycombed appearance is due to old ulceration, as this often undermines the mucous membrane, leaving bridges of it, but the mucous membrane here is almost wholly detached, and forms in its honeycombed condition a sort of network within the lumen of the bowel, composed of fine spiral rods, the whole mass resembling somewhat a collection of fine white worms. This, together with great thickening of the outer coats, caused the obstruction. There was a history of syphilis, and possibly the ulceration was syphilitic in origin. All active ulceration had ceased at the time of the patient's death. I regret that a general *post mortem* could not be made, nor even the interior of the intestines examined for the indications of old or recent ulceration. The way in which the sigmoid was densely adherent to the left iliac fossa was suggestive of ulceration there also, though the sigmoid was not obviously thickened. *December 1st*, 1903.

---

27. *A case of dermoid tumour of the brain.*

By E. Farquhar Buzzard.

Early in 1903 a boy, aged 14 years, came to the Royal Free Hospital complaining of having had fits and paroxysmal attacks of headache and vomiting during the previous twelve months. On examination he proved to have very intense double optic neuritis and some slight weakness of the lower half of the face

on the left side. Apart from this there were no objective signs of disease of the nervous system, and the other organs were healthy with the exception of the heart, which presented the physical signs and symptoms of a fully compensated mitral lesion. The boy was admitted into the hospital, where he remained, except for a few days, until his death, two or three months later. During the greater part of this time he was perfectly well, mentally and physically, but at intervals of two or three weeks he would have a paroxysm of severe frontal headache, accompanied by vomiting, and lasting a few days. While the attack persisted he was in a drowsy, semi-conscious condition, and on one or two occasions was observed to have some form of generalised epileptiform seizure. His eyesight began to fail as the neuritis passed on to atrophy, and he died during one of the periods of unconsciousness. At the autopsy a tumour was found on the orbital surface of the frontal lobes lying just in front of the optic chiasma and extending from the commencement of the fissure of Sylvius on the right side to a similar position on the left. It occupied the space between the dura mater and the leptomeninges, being unattached to the former, but strongly adherent to the latter. The brain substance in front of the right Sylvian fissure was deeply indented, so as to form a hollow cup lined by the pia-arachnoid, in which the thickest end of the tumour lay. A similar but shallower depression was present on the left side in the corresponding region. The tumour itself was of a light yellow colour and of a greasy, crumbly consistence, and from its position must have exerted some pressure on both optic nerves and both olfactory lobes. It possessed a definite wall only around its right thickened extremity, and sections of this wall presented the appearances of ordinary skin containing numerous hair follicles and very active-looking sebaceous glands. Firmly adherent to its deep surface was the pia-arachnoid, much thickened and calcareous in places. Microscopically the main mass of the tumour was seen to be composed of sebaceous material mixed with epithelial *débris*, numerous hairs and fatty globules of varying size. Chemically it contained only traces of cholesterin.

Taking into consideration the fact that no definite wall was present except at the right extremity of the growth, and that

that wall showed the presence of numerous secreting sebaceous glands, it is justifiable to suppose that the dermoid arose in connection with some epiblastic tissue remains in the subdural space near the mouth of the right Sylvian fissure. In the second place, it appears probable, owing to the age at which symptoms of its presence began first to show themselves, that the onset of puberty was responsible for an excessive secretory activity on the part of the glands and an abundant production of hairs, with the result that the material so formed was gradually forced across the midline in front of the optic chiasma until the mass occupied the position seen at the autopsy.

Probably the last word has not yet been spoken as to the origin of tumours such as the one just described, but a full discussion of the whole subject and an excellent *résumé* of the literature can be found in the 'Centralblatt für Allgemeine Pathologie u. Pathologische Anatomie' for 1897, and a shorter digest on much the same lines is supplied by Bruns in the 'Handbuch der Pathologischen Anatomie des Nervensystems.'

Bostroem, the author of the former paper, holds the view that simple cholesteatomata—cholesteatomata containing hairs, etc.—and pial dermoids have all a similar fundamental origin from epiblastic tissue, the former representing a proliferation of the epidermal and the latter a proliferation of the deeper dermal structures of the skin. This view is in opposition to that held by other authors, who regard the cholesteatomata as of endothelial origin, but is supported by the fact that there are transitional varieties, and that all three are usually found in similar situations and in similar relation to the primitive neural tube. *January 5th*, 1904.

---

28. *Sarcoma of the pancreas associated with pseudo-lipæmia.*

By J. Fawcett and A. E. Boycott.

Geo. W. M., aged 19 years, a porter, was admitted into Guy's Hospital under Mr. Arbuthnot Lane on January 5th, 1903, and died the following day.

No information was obtainable as to his previous history, except

that for about five days before admission he had had some increasing tenderness of the gums.

Condition on admission.—He was anæmic, emaciated, and seemed very ill. Temperature 103°. Pulse 150. The gums were much swollen, and pus welled up between the teeth, many of which were loose. Sordes were present in the mouth. The loose teeth were extracted, and pure carbolic acid was applied. The patient rallied well after the anæsthetic, but later became worse again and died.

Abstract of the autopsy.—The gums formed thick infiltrated flaps overlapping the emptied jaws. The peritoneum contained a quantity of thin foul-smelling pus. There was no perforation anywhere, and no cause for the peritonitis could be found. The liver, stomach, duodenum, spleen, left kidney, and pancreas were matted up together by a large mass of growth and peritoneal adhesions. Both liver and spleen were firmly adherent to the diaphragm. The pancreas was about twice its normal size, and was infiltrated throughout by a firm white growth which extended from the tail of the organ into the pelvis of the left kidney. The growth had extended in all directions—into the lesser omentum and the mesentery, along the round ligament to the liver, and into the descending meso-colon. At the level of the tail of the pancreas there was a layer of growth surrounding the duodenum, the wall of which was in consequence increased in thickness to about 1·5 cm. The spleen was large and soft, and weighed 439 grms. A few secondary nodules were present in the left kidney, and there was a secondary growth in the periosteum over the left frontal bone.

Cultivations made from blood from the right side of the heart showed the presence of *Streptococcus longus, Bacillus coli,* and other non-identified organisms.

Morbid histology of growth.—Pancreas.—Sections from different parts all showed a small, round-celled deposit which, in some places, had altogether replaced the gland tissue, and, in others, was seen between the lobules and acini of the gland.

Lymphatic glands showed a similar structure.

Duodenum.—Villi still seen on surface. The submucous and muscular coats were infiltrated by a small round-celled deposit similar to that in the pancreas.

The growth may therefore be classed as a lymphosarcoma,

but the place of origin must be regarded as doubtful. I do not think it is possible to say whether it actually started in the glands, the intestine, or the pancreas. I have called it a sarcoma of the pancreas inasmuch as the involvement of that viscus throughout its length was the most striking feature at the autopsy. The affection of the duodenum was strictly localised, and suggested an extension of the growth into it, in the same way as had taken place into the left kidney and other structures.

Urine.—Not examined during life, but some which was withdrawn from the bladder *post mortem* did not contain either sugar or diacetic acid.

Blood.—A specimen of the blood taken from the right heart for purposes of bacteriological investigation was noticed *after a short while* to have separated into an opaque milky layer above, with dark blood below. Unfortunately, as neither the disease of the pancreas nor the blood condition had been suspected during life the only blood available for further investigation was that in the intra-cranial sinuses. About an ounce was obtained, and for the examination of it I am indebted to Dr. A. E. Boycott, Gordon lecturer on experimental pathology at Guy's Hospital, who reports as follows:

"*Blood from post-mortem examination* made about sixteen hours after death separates into—(1) a layer of corpuscles occupying about a sixth of the fluid in the test-tube, (2) a supernatant liquid of creamy colour, yellower than fresh cream. This liquid could not be easily made to separate into anything further, but by repeated and prolonged centrifugalisation, or on standing for about seven days, a thin clear stratum (about a tenth) was obtained. The red corpuscles showed nothing particular; but they were not well preserved. No excess of leucocytes, and nearly all are small lymphocytes, a condition which is, I believe, commonly found in *post-mortem* blood. The creamy layer owes its appearance to the presence of a large number of extremely minute particles; they are very small, but as far as can be seen none are circular in outline; they look rather irregular fragments. Their size is practically uniform throughout. They are only separated from the fluid in which they float with great difficulty, so that their specific gravity is a trifle more than that of the serum. They are not soluble in ether or in 1 per cent. acetic acid. In films they stain a clear

blue with Jenner's stain, *i. e.*, quite differently from the free granules of polymorphonuclear leucocytes. With thionin-blue they also stain a clear pale blue without any trace of purple, *i. e.* differently from nuclear chromatic material. They show no trace of specific staining with osmic acid or Sudan III. There are, then, no reasons for supposing that this granular material is immediately derived from any of the cellular elements of the blood."

Mr. J. H. Ryffel, B.Sc., Demonstrator of Chemistry at Guy's Hospital, kindly analysed the blood for me, and found it only contained 0·38 per cent. of fat—that is, no more than is present in normal blood-plasma. In Schäfer's 'Text-book of Physiology' Professor Schäfer states that fats are present in small but variable quantity, 0·2—0·5, or even 1 per cent. This report therefore confirms that of Dr. Boycott, in which he points out that the particles in the fluid gave no fat reactions.

Remarks.—In addition to the interest attaching to the nature of the growth, there is the special feature of the blood condition. It will have been noticed that the blood, when withdrawn from the heart, was of the usual dark colour, and that it was only after some five or ten minutes that it separated out into two layers. Now although so-called "lipæmic" blood is generally of a pink or crushed strawberry colour, yet I do not gather that the term "lipæmia" is only applied to this variety of blood, but to any which, after withdrawal from the vessels, separates into layers, the upper of which is creamy, this appearance being thought to be due to the presence of an excess of fat. A large majority of cases in which this creamy blood is present are associated with diabetes, but it has been met with in such others as chronic alcoholism, etc. In this case, however, the blood did not contain any excess of fat, nor did the urine contain any sugar when examined after death.

In a paper in the 'Lancet,' vol. ii (pp. 232 and 258), 1860, Dr. C. T. Coote refers to the fact that lactescence of the serum may be due to another cause than free fat, and that this was first noticed by John Hunter and recorded in 1794. To this substance is given the name of "molecular albumen," but Dr. Coote thought it very doubtful whether milkiness of the serum was ever due to the presence of molecular albumen alone. He, however, refers to a case examined by Dr. Bostock ('Bright's Reports of Medical

Cases,' vol. i, p. 83) in which the blood-serum from some dropsical patients was occasionally noticed to be turbid, "and upon standing for twenty-four hours a white, creamy substance rose to the surface," but there was not "any proper oily matter in it."

These cases, amongst others, suggest that creamy blood may be due to a substance apparently proteid in nature, and Dr. Hale White has recently published ('Lancet,' October 10th, 1903) a report of a case in which a similar result was obtained. The blood in appearance was typically "lipæmic," the serum after clotting was milky, and yet on microscopical examination no fat globules were to be seen, but a granular precipitate only. This precipitate was apparently the cause of the milkiness, and on analysis it was found to consist of a proteid and another substance which, although allied to fat, was not a true fat.

In the case I have recorded there is little evidence as to the nature of the granular precipitate which gave rise to the milkiness of the serum, but what there is tends to confirm the observations of Dr. Hale White and others that such blood is not always due to the presence of free fat, and that "lipæmia" is not a correct term to use for all cases of "white blood."

The pathology of the condition is no more certain than it was forty or more years ago. It is clear that it may be due to other substances than fat, as also that diabetes mellitus is not the only condition with which it is associated. Whether or no the pancreas has any ætiological relation with it is a question which for the present must be left for further investigation.

May 3rd, 1904.

---

29. *A case of primary sarcoma of the liver in an infant.*

By E. P. Baumann and J. G. Forbes.

The specimen shown is taken from a male child aged 11 months, who was brought to the Hospital for Sick Children, Great Ormond Street, on December 4th, 1903, on account of

swelling of the abdomen. The child was admitted under the care of Dr. Penrose, to whom we are indebted for permission to publish the case.

The history given was that the patient had been in good health until four weeks before admission, when he began to vomit and "seemed out of sorts." At the same time his abdomen was noticed to be enlarged.

The enlargement became rapidly greater. At the onset of the illness the patient was said to have been slightly jaundiced, but this condition soon passed off. Latterly the vomiting had grown more frequent and the child was losing flesh. The bowels throughout were regular, but the motions were of a bright green colour.

The child was one of a family of six, of whom the others were all well. No tendency to hereditary disease on the part of the parents was elicited.

State on admission.—The child was well nourished, though very pale. It was not jaundiced. The abdomen was greatly distended. The whole of the upper part was occupied by a large resistant mass descending on the left side to the iliac fossa and extending right across the middle line into the right flank. The surface was smooth and elastic, and at one point almost fluctuant. The mass was distinctly felt *per rectum* reaching into the left pelvis. No glands were to be felt in the abdomen, and the glands generally were not enlarged. The urine contained a faint haze of albumen, but no bile. The heart and lungs appeared to be healthy.

A diagnosis was made of sarcoma of the liver, and this was confirmed by an exploratory incision which was performed by Mr. H. Stansfield Collier on December 9th. Large friable masses were seen in connection with the liver. Any attempt to remove the growth was hopeless and the wound was therefore closed. Death occurred three days later. The temperature during the stay in hospital ranged between 99° and 102° F.

Post-mortem examination.—At the necropsy the liver was found to be much enlarged, occupying the greater portion of the abdominal cavity. The organ was easily removed, being adherent only at one point to the other viscera. This was at the lower border of the right lobe, where a coil of intestine was adherent. Several massive deposits of growth were found

occupying practically the whole of the organ. There were three main masses into which extensive hæmorrhages had occurred, and several small nodules were found on the surface and in the substance of the liver. The coil of intestine which was adherent was not infiltrated, and no secondary growth could be discovered in any other tissues or organs.

Microscopical examination was made of some of the small nodules, and showed the growth to be composed of collections of round cells invading the liver substance, and separated from neighbouring nodules by flattened and altered gland tissue, or by inflammatory exudation and hæmorrhagic areas.

In many places the arrangement of the new cells appears to be alveolar in character—so much so that the growth on first examination presented strong resemblance to a carcinoma.

Further investigation, however, showed that this appearance was possibly due to some of the cells having been cut in transverse section. For here and there strands of growth are to be found with the cells cut in the longitudinal axis, and appearing unmistakably spindle in shape, with oval or elongated nuclei—thus proving their sarcomatous nature.

Extensive areas of hæmorrhage occur scattered throughout the growth and the liver substance. Some of these appear as blood spaces lined by endothelial cells, which show proliferation and merge into the surrounding cell masses.

In other parts, where no hæmorrhagic spaces are visible, the small capillaries are crowded with proliferated endothelial cells, which form the lining wall of the vessels and appear to pass with perceptible gradation into the type of cell constituting the growth. If this observation be correct, it would seem to indicate that the growth had its origin in the endothelium of the perivascular lymphatics or of the blood capillaries themselves.

Where free from growth the liver substance is much compressed, atrophied or in an advanced state of fatty degeneration, and in parts small intra-lobular hæmorrhages are to be seen.

Summing up, the case in our opinion is one of primary round- and spindle-celled sarcoma in the form of multiple new formations affecting only the liver, but it may be an angiosarcoma.

The alveolar arrangement of the cells seen in the transverse section of the greater part of the specimen, and already referred to, raises the interesting question whether a connective-

tissue growth may not assume the cell arrangement of the glandular organ in which it is deposited.

Primary sarcoma of the liver is at all times a rare condition. Byrom Bramwell and Leith[1] were a few years ago able to collect only 27 cases. The great majority of these occurred in adults, only one or two of the cases being children.

The *post-mortem* records of the Hospital for Sick Children from January, 1860, to the present day, furnish but a single other instance of the occurrence of primary sarcoma of the liver, and that was in the case of a child aged 3 years.

In very young children the condition is one of extreme rarity, for the whole literature of the subject comprises only four authenticated cases in infants under 12 months of age.

For this reason the above case has seemed to us worthy of record.

Abstract of previously recorded cases of primary sarcoma of the liver.

1. West, 'Diseases of Children,' 1884, p. 764.—Male, aged 8 months. Illness began with diarrhœa, loss of appetite, and emaciation. When nine months old a solid tumour was noted by mother in abdomen. Disease lasted eight months. At necropsy medullary sarcoma found in right lobe of liver. Separate nodules found in right lung.

(*Note.*—The writer speaks of this case as a cancer, but from the description it must be regarded as a sarcoma.)

2. Meisenbach, 'Weekly Med. Review,' 1884, ix, p. 433.—Infant aged 4 months. Father died of phthisis. No history of specific disease. Some weeks after birth mother noticed a swelling in abdomen. Child lost flesh. Large resistant mass almost filling abdomen. Disease lasted nine or ten weeks. At necropsy, liver smooth and symmetrical; colour mottled. On section, shown to be myosarcoma. Secondary deposits in lungs.

3. Lendrop, 'Hospitals-Tidende,' 1893, p. 217.—Infant aged 4 months. Large tumour in abdomen. No jaundice. At necropsy, liver was found to contain numerous disseminated tumours consisting of small round cells which seemed to originate in the

[1] 'Lancet,' vol. i, 1897, p. 170.

endothelium of the interacinous blood-vessels and penetrate into the veins, where they compressed the liver-cells.

4. De Haan, 'Beitrage zur Path. Anat.,' 1903, xxxiv, p. 215. —Infant aged 4 months. Illness began at the age of 2 months with pyrexia and enlargement of the liver. No jaundice at necropsy; liver was found to contain several hæmorrhagic tumour masses. On section, shown to be alveolar angiosarcoma. No secondary deposits.

In addition to the above published cases a specimen of primary round-celled sarcoma from an infant aged 2 months figures in the Pathological Museum of St. Bartholomew's Hospital.

30. *An experimental inquiry concerning epidemic or bacillary dysentery.*

By R. H. Firth.

(With Plates VII and VIII.)

Summarium.

(Cum Tabulis VII, VIII.)

Quamvis in dejectis eorum qui dysenteriâ epidemicâ aegrotant reperiri possint bacilli qui et B. coli communi et B. typhoso omnino dissimiles sunt, non omnes horum dysenteriam causare videntur.

De bacillis dysenteriæ, ut dicuntur, quærere oportet, qui morbifici seu pathogenici, qui non-morbifici sint.

Bacilli illi non-morbifici facultatem possident sacchari (maltose, galactose, mannite) fermentandi, indol quoque faciendi; acidum generant sed haud ærogenici sunt; quæ facultates bacillis morbificis desunt.

Bacilli morbifici dijudicari insuper possunt reactione quæ ad agglutinationem pertinet.

Sanguinis serum animalium quæ bacilli dysenteriæ injectione immunisata sunt, maxime dilutum bacillos ejusdem generis agglutinat.

Hoc serum bacillos non-morbificos aut minime aut nullo modo agglutinat.

Nulla fit interactio quum bacilli non-morbifici cum sanguinis sero animalium miscentur si animalia bacillis morbificis immunisata sint.

Sero in cuniculos injecto nulla actio antitoxica apparet.

Quamvis cuniculi nullo modo morbo afficiantur quum bacilli dysenteriæ aut toxina sua, per os aut per intestinum (culturâ directe injectâ) adhibeantur, post injectionem, tamen, subcutaneam oriuntur læsiones similes illis quæ in ægris dysenteriâ affectis videntur.

Hae læsiones, insuper, oriuntur quum bacilli antequam injiciuntur calore interfecti sunt (60° C., per dimidiam horæ partem).

Similia efficit injectio culturæ filtratæ.

Quamvis bacilli dysenteriæ et toxina sua cæcum atque colon deligant, nihil in cuniculo efficit injectio directa in lumen intestinale: injectio subcutanea, ex contrario, læsiones dysentericas generat.

In epithelio intestinali cuniculi inest materies quædam normalis, ut credo, quæ bacilli dysenteriæ aggresionem prohibet.

De vitâ bacillorum dysenteriæ extra corpus, aut in solo aut in fabricis siccatorum, adhuc viventes post dies 21 inveniuntur; ex aquâ (22° C.) post dies 160, ex aquâ 37° C. post dies 43, ex aquâ sterilisatâ (22° C.) post menses 9, coli possunt.

Ille bacillus modo qui læsiones intestinales generat B. dysenteriæ appellari debet; ille non-morbificus, qui *mannitum frangit* "B. typhosus simulans" appelletur.

Nondum sperare, ut opinor, possumus, hominem adversus bacillum dysenteriæ immunisare.

Before discussing the main theme of this article, it may be convenient to review briefly modern views regarding the classification of dysentery. There are few subjects in medicine that have attracted more attention than this disease, and it is doubtful whether the literature of any affection is more encumbered with a mass of names, indicating the nature of the disorder or the author's conception of its pathology, than is that of dysentery. Its history dates from the earliest times, and its ravages, unlike those of many of the other pestilential diseases, have continued practically unaltered to the present day. A critical study of the literature of the disease suggests the probability that, under the term "dysentery," there may have been included in the past, and even be included still, more than one pathological entity. That the lines of demarcation between the several types should be obscure is not a matter of wonder, if we remember that all earlier attempts at classification proceeded upon clinical and pathological rather than etiological lines. Limiting our conception of the affection to that of a disease marked by frequent bloody and mucous stools, fever, tenesmus and abdominal pains in different degrees, coupled with thickening of the walls, hæmorrhages and ulceration of the mucous and submucous coats of the large intestine, notably of the cæcum and rectum, we find that the group of symptoms and lesions known as dysentery are conveniently classified into the following—namely, the endemic, the epidemic, and the sporadic classes.

Ever since the time of John Hunter there have been those who, upon pathologico-anatomical grounds, have separated the endemic from the epidemic disease, but it is only during recent years that the line has been sharply drawn. For this division of the idiopathic dysenteries we are indebted mainly to Kartulis, who specially distinguishes the endemic or tropical form of dysentery by its climatic and geographical peculiarities and its etiology, claiming an amœba as its constant cause. With this general classification most authorities tacitly agree, subject, however, to the proviso that although an amœba may be the cause, at least, of an Egyptian endemic or tropical dysentery,

yet the origin of epidemic dysenteries is essentially bacillary. As for the so-called sporadic forms, these are caused by chemical or mechanical means, or by the presence of parasites. A very superficial knowledge of the disease shows that the different forms of dysentery are clinically indistinguishable, since all have catarrhal, diphtheritic, and ulcerated stages, accompanied by such symptoms as colic, tenesmus, slimy bloody stools, and later fever, rigors, loss of appetite, and exhaustion. These various terms and symptoms are far from signifying sharply defined entities. The clinical manifestations and pathological lesions of the catarrhal variety occur in all kinds of dysentery and in all places where the disease prevails. Similarly, diphtheritis and ulceration are not safe data, for while the former condition is present commonly in the epidemic disease, it occurs also in the tropical or endemic manifestations. The so-called endemic dysentery has no tendency to spontaneous cure and is mainly chronic and ulcerative, affecting the cæcum and ascending colon, while the epidemic type is of short duration, catarrhal and ulcerative, involving the whole colon and rectum. Whether we consider the disease from the clinical, etiological, or geographical point of view, it is clear that the pathological anatomy and its exciting cause constitute the real differences between the types or classes. Under these circumstances there appears to be no reason why we should not drop the terms "endemic" and "epidemic," but adopt, as the basis of classification, the sole and etiological difference between the two types, namely, the presence of amœbæ or apparently causative bacilli.

Whatever may be the pathological differences between amœbic and bacillary dysentery, both forms of the disease agree in their independence of soil dampness or climate and of variations in temperature, also in their greater incidence in hot weather and under circumstances of crowding, lowered vitality, and bad or fouled water supply. Although it is not the purpose of this article to discuss the causative agent of amœbic or so-called endemic dysentery, it may be stated that Kartulis' case in support of his plea that amœbæ are the cause of all endemic dysenteries is a strong one; but until these amœbæ can be cultivated outside the body and then shown to be capable of causing a typical dysentery with amœbic stools in infected animals, the problem cannot be considered as solved absolutely.

Leaving this aspect of the dysenteric question, we may now pass to a consideration of the various organisms which have been described as the cause of epidemic-non-amœbic or bacillary dysentery.

The presence of bacteria in the stools and intestinal tissues in epidemic dysentery has been known for some years, but the credit of first recognising a definite pathogenic bacillus in that disease rests with Chantemesse and Widal, who described its characters and its pathogenic action on animals. Certain researches by Kruse and Pasquale and by Celli and Fiocca, on the same lines, were to some extent confirmative. These latter investigators considered it highly probable that the disease was caused by a bacillus closely allied to the *B. coli*, which they had isolated from dysenteric cases. With cultures of this bacillus they claimed to produce dysentery in cats, and a toxin separated from growths of the organism was found to give rise to similar conditions. Identical results were obtained by del Pino and Alessandri, while Escherich also expressed his belief in the important part played by certain highly virulent bacilli allied to the typho-coli group which he had isolated from a contagious enteric disorder in children, whose morbid anatomy agreed closely with catarrhal dysentery. On the other hand, a causative *rôle* in the production of dysentery had also been ascribed to the pyogenic cocci, especially the streptococci, which are constantly found in association with the intestinal bacilli. The chief exponent of this view has been Zancarol, whose studies have been endorsed to some extent by those of Silvestri, in Turin, and of Ascher, who investigated cases of this kind in Prussia. The cocci isolated by Ascher were said to have shown the agglutination reaction with the blood serum of the patients from whom they were obtained. In the same way a variety of endemic dysentery prevailing in Cochin China was believed by Calmette to be due to the *B. pyocyaneus*, while the same micro-organism was isolated from a small epidemic of the disease occurring in America by Lartigau, and in Canada by Adami.

From the foregoing summary it is clear that there has been no lack of variety in micro-organisms to which the causation of dysentery has been attributed. Much of the experimental work of those observers was carried out at a time and under conditions

when bacteriological methods were more imperfect than they are now. For this reason too great importance must not be attached to their conclusions, particularly as subsequent researches have shown that the bacilli so far enumerated, except those of Chantemesse and Widal, possess doubtful specific properties. The investigations of an epidemic of dysentery in Japan during 1897 by Shiga have yielded somewhat different and apparently more convincing results, inasmuch as he not only isolated a special bacillus from the stools of the affected, but showed its specificity by demonstrating the agglutination of its cultures by blood-serum from the sick. It is true his experiments upon animals failed to reproduce the symptoms and intestinal lesions so characteristic of human dysentery; still, relying on the constant presence of the bacillus in the excreta of those suffering from dysentery, its absence from the discharges of other sick persons, and its agglutination by the serum of the affected, Shiga believed that he had isolated the probable cause of epidemic dysentery, or at least of that form which prevails in Japan. Two years later Kruse discovered an apparently identical bacillus in an epidemic of dysentery which prevailed in Rhenish Westphalia. At much the same time Flexner, in the Philippines, isolated from certain persons suffering from dysentery a bacillus presenting close resemblances to that obtained by Shiga in Japan. Flexner's work was practically confirmed soon after by Strong and Musgrave in their study of dysentery among the American troops in Manilla, while Drigalski, in an outbreak among the Prussian Guards encamped at Doberitz, Pfuhl among men returned from the China expedition, and Müller in an epidemic at Sudsteiermark, all describe an identical bacillus. Vedder and Duval recovered in several outbreaks of dysentery in the United States bacilli analogous to those isolated by Flexner in Manilla and Porto Rico; so, too, Rosenthal in Moscow reports to the same effect; while Rogers has found a bacillus closely resembling that described by Shiga in the stools of catarrhal dysentery in India. To the same effect are the observations of Park and Carey, made during an extensive outbreak in Tuckahoe, New York State. More recently Vaillard and Dopter give details of a micro-organism isolated by them in an epidemic of dysentery in the garrison of Vincennes, which they consider to be the same as that noted by the other observers.

In short, from the most diverse parts of the globe has accumulated a considerable mass of evidence indicating that there exists an epidemic form of dysentery characterised by a special micro-organism whose constant presence in the intestinal discharges and agglutination by the blood serum of those affected suggests its being considered as the probable cause of this disease.

It is now generally recognised that four points must be proved in the effort to show that an organism suspected of standing in etiological relation to any given disease is really the causative agent. They are: (1) the organism must occur constantly in cases of the affection; (2) it must present certain definite cultural features and be a species not present normally in the diseased part; (3) it must be pathogenic and capable of producing in experimental animals lesions similar to those of the case from which it was obtained; (4) it should, by virtue of its pathogenic activity in man, show an agglutination reaction with the blood sera of those who are suffering from the disease. In the course of a critical inquiry into the present state of our knowledge as to the etiology of epidemic or bacillary dysentery I have been able to make certain observations on these various points, and hope to be able to show that we are now in a position to affirm what is the causative agent in this disease and how far we are justified in hopes of practical success in attempts to establish immunity against it. The evidence for and against the conclusions reached can be conveniently considered under the three main heads of (*a*) the cultural and agglutination reactions of the dysentery bacilli; (*b*) the experimental evidence as to their pathogenicity; (*c*) protective inoculation and serum therapy.

(A) *The cultural and agglutinative reactions of dysentery bacilli.*

The morphological and cultural characters of these micro-organisms may be thus described. They are short, thin rods, usually single and rarely united in pairs or in threads; individually they vary from 1 to 3 μ in length, and are a trifle thicker than the *B. typhosus*. Their ends are rounded; they are usually non-motile and apparently without cilia; never form spores, stain easily with the ordinary aniline dyes, but decolorise by Gram's method of staining. Bi-polar staining and the appear-

ance of involution forms are not uncommon. They grow well at 37° C. on all the ordinary cultural media, both aërobically and anaërobically, but preferably in the presence of oxygen. Both as to motility and the presence of cilia some difference of opinion is evident in the literature concerning these bacilli. As the result of a somewhat extended study of this micro-organism, derived from a variety of sources, I am disposed to think that in recently isolated strains there is motility, but at best it is less than that of the enteric fever bacillus, being slow and laboured and soon lost on artificial cultivation. Brownian movement is active. The same remarks apply as to the presence of flagella. In a recently isolated strain cilia can be demonstrated by both van Ermenghem's and Rossi's method of staining. The flagella are six to eight in number, peritrichal, and about eight times the length of the bacillus; the cilia are very readily shed and practically impossible to demonstrate in strains which have been under artificial culture for any length of time.

When grown on a gelatine slope at 22° C., the dysentery bacilli form a fine pearly expansion with slightly serrated margins, not unlike that given by the *B. typhosus*, and growing at much the same speed. In plates made of this medium, the surface colonies are delicate pearl-grey expansions, more or less translucent, with waved or indented margins, and marked by delicate ridges and furrows suggestive of the finer venations on a vine leaf. The gelatine is not liquefied. In the accompanying Plate VII are shown typical colonies of some varieties of this bacillus. In all these features it presents many similarities to colonies of the enteric fever organism. It, however, grows a trifle more rapidly on gelatine than does this latter bacillus, but distinctly more slowly than does the *B. coli communis*. Its colonies in the gelatine depth present no distinctive characteristics.

Upon ordinary sloped agar the growth is moist, grey, slightly opalescent, and very much like that of the *B. typhosus*. If the agar be tinted with neutral red in the presence of either glucose or lactose, subsequent inoculation with the *B. dysenteriæ* causes no change of colour.

In peptone broth the micro-organism causes a uniform turbidity, without the formation of any pellicle. After a few days, usually about the third day, a flocculent deposit forms,

and the reaction of the medium becomes slightly acid. The majority of the strains of this bacillus which I have examined fail to produce indol either in peptone bouillon or in peptone and salt solution. As will be seen from details given in the accompanying tabular statement, there are some apparent exceptions to this rule. On the other hand, all varieties reduce nitrates. The growth on potato is somewhat variable, but in the majority of cases it is colourless, moist, and glistening, while in some varieties it is of a pale yellow to a light brown colour.

In milk, the various dysentery bacilli grow well, producing no clot. The reaction of this medium does not sensibly alter for the first two days, but after that period there may be some production of a faint acidity, but passing always to a definite alkalinity about the seventh day. The resulting alkalinity, even after three weeks' incubation, rarely exceeds the original reaction of the medium, and never passes to that produced by certain "intermediate" bacilli of the colon-enteric group, such as *B. enteritidis* of Gärtner, *B. alkaligenes* of Petruschky, and some para-typhoid strains.

When grown in the various sugars there is no production of gas by this bacillus, but all strains cause a small production of acid in glucose, and a few varieties give rise to acid in maltose and galactose, and also in the alcohol mannite. Starch and glycerine are quite unaffected. Its behaviour in the media suggested by Proskauer and Capaldi is similar, on the whole, to that shown by the enteric bacillus. Practically, all varieties fail to grow in No. 1 medium, while in No. 2 their growth results in either no change in reaction, or at most a faint acidity.

The accompanying table gives in some detail the chief cultural characteristics of the different strains of the dysentery bacillus which have been examined by me. Two of those were received from Dr. Flexner, and are shown as Flexner I and II; Flexner III came from Dr. Krâl of Prague; and Flexner IV from Dr. MacConkey. Shiga I came also from Dr. MacConkey, Shiga II from Dr. Krâl, and Shiga III from Dr. Bulloch. The varieties called Harris and Gray came through Dr. MacConkey, and were, I believe, obtained originally in Manilla either by Flexner or one of his assistants; while Pickering and Landon were obtained by myself from the stools of two soldiers at Netley, who had been invalided with dysentery from India and South

Africa respectively. The Kruse I came from Dr. Krâl, and that marked Kruse II from Dr. Flexner, while the variety called Vaillard was sent to me by Dr. Vaillard of Vincennes, having been isolated in the outbreak of dysentery in that garrison already referred to. For the sake of brevity the letters N.G. are used to signify the fact of no gas production. Further, where a statement is made that a given percentage of acid was produced, the percentage is in terms of decinormal sulphuric acid, the degree of acidity being in all cases estimated after twenty-four hours' incubation at 37° C., unless specifically stated as being otherwise. The Proskauer and Capaldi media reactions are twenty-four-hour statements after incubation at 37° C.; indol production, clotting of milk, reduction of nitrate broth and neutral red reactions were all noted at the end of seven days' incubation at 37° C.

An examination of the table shows that while all the members of this group of micro-organisms have certain common characteristics in respect of morphology, growth on agar, gelatine, in broth, in milk, on potato, in nitrate broth, and in Proskauer and Capaldi's media, it is in their behaviour in the various fermentable media and in peptone and salt solution that certain points of difference show themselves. All of these organisms ferment glucose to the formation of acid, and all fail to ferment lactose and sucrose, but in respect of some of the other fermentable media and the production of indol in Dunham's solution, they divide themselves practically into those which ferment one or more of the three media, mannite, maltose, and galactose, and those which do not, and those which produce indol and those which fail to do so. A further scrutiny of the reactions shows that ability or inability to ferment the alcohol and the two sugars coincides broadly with an ability or inability to produce indol in a peptone solution. A still closer analysis of the reactions indicates that we have apparently two groups of micro-organisms: one represented by all the Shiga bacilli, both the Kruse strains, Flexner I and III, and the Vaillard variety (all these ferment glucose only); and a second group, represented by the Flexner II and IV, Gray, Harris, Pickering, and Landon (these organisms split glucose, maltose, galactose, and mannite, to the production of acid). In the main, these results as to fermentation are in accord with the work of Drigalski, Lentz,

and some others who have examined dysentery micro-organisms. It is quite clear that all strains of these dysentery bacilli are culturally distinct from the *B. coli communis;* but they present, in respect of those same reactions, a remarkable affinity to the *B. typhosus,* from which they differ only, in some cases, as to indol production, and, in other cases, as to inability to ferment mannite. The failure to be affected by an enteric serum marks, further, an important point of differentiation between the two micro-organisms, coupled with the fact that the enteric bacillus is equally unaffected by dysenteric serum.

As in the case of some other diseases, the blood serum of persons affected with dysentery appears to contain specific agglutinations, which are definitely active in respect of the infecting micro-organisms, and variably so in respect of other strains of apparently the same bacillus. This fact has naturally been taken to constitute an important argument in favour of the specific nature of the isolated micro-organism. Considerable time has been devoted to a study of the agglutination reactions of the bacilli actually isolated at Netley, as well as of those other cultures obtained from the various specified sources. The human blood serum was necessarily limited to that obtainable from the two cases which alone have come under observation, but in addition to these sera, some anti-colon serum was obtained from Dr. Dowson, of the Wellcome Research Laboratories, and various specific sera were obtained from rabbits inoculated with strains of the dysentery bacillus for the purpose. In all cases control observations were made with suspensions of *B. coli* and *B. typhosus,* also with an active anti-typhoid serum, while not infrequently normal human and rabbit's blood was used as a control for the specific sera. In none of these control tests was an agglutination reaction ever obtained. The reaction was in all cases observed microscopically in a hanging drop, the time limit being placed at one hour, and no agglutination accepted as being positive if the dilution was less than 1 in 20. The results obtained may be summarised in these terms.

The blood serum from both Pickering and Landon failed to agglutinate any strain of the bacillus then available, even failing in respect of the apparently specific organisms isolated from their respective dejecta. A rabbit inoculated repeatedly with small doses of Landon's bacillus gave a serum which agglu-

tinated Landon 1 in 60, Flexner I at 1 in 50, and Shiga I at 1 in 70. It failed to affect the strains referred to as Pickering, Flexner II, Harris, or Gray. The other strains were not then available.

A rabbit immunised with Flexner I gave a serum which agglutinated Pickering 1 in 30, Landon and Kruse I each at 1 in 50, Flexner I at 1 in 80, but failed to touch Shiga I or Kruse II. No other strains were available at this time.

Another rabbit inoculated with Shiga I was gradually worked up to agglutinate its own bacillus and Flexner I at 1 in 300, also Kruse II at 1 in 200, but its effect on Pickering, Landon, and Flexner II was only manifest at 1 in 40, and doubtful or unsatisfactory as to Gray and Harris at 1 in 30.

The serum of a rabbit, as the result of immunisation with Shiga II, agglutinated ultimately its own bacillus at 1 in 200, Kruse I and Shiga I at 1 in 150, Flexner I and III at 1 in 100, Harris, Pickering, and Gray at 1 in 50, but failed to act satisfactorily upon Flexner II and IV, or upon Landon.

A rabbit inoculated with Kruse I gave a serum agglutinating that organism and Krause II at a dilution of 1 in 140, Flexner II and III, also Harris at 1 in 60, Shiga I at 1 in 100, and Flexner I at 1 in 90. It was not tried against either of the strains called Pickering and Landon.

The serum from a rabbit as a result of inoculation with Kruse II, was active only against its own bacillus, Kruse I, all the Shigas, Flexner III, and the Vaillard strain at 1 in 200. It was inactive against Flexner II and IV, Harris, Gray, and Landon. It was not tried against Flexner I and Pickering.

After immunising a rabbit with the Vaillard bacillus, its serum was agglutinative as to its own micro-organism, the Shigas, both the Kruses, Flexner I and III at a dilution of 1 in 250. It affected Flexner II. and Pickering at 1 in 40, and Landon at 1 in 30. It was not tried against either Harris or Gray. In the case of another rabbit which died ultimately from the effects of injections with Vaillard's strain of the dysentery bacillus, the serum agglutinated its own micro-organism at 1 in 40, Shiga II and Kruse II both at 1 in 50, and Flexner IV and Gray at 1 in 30. It was not tried against the other strains. Another rabbit, which had been inoculated with certain soluble toxins (to be referred to later) derived from

TABLE I.—*Cultural Characteristics of*

	Flexner I.	Flexner II.	Flexner III.	Flexner IV.	Harris.
Morphology	Small, non-motile rod, often in pairs.	Small, non-motile rod, often in pairs.	Small, non-motile rod.	Small, non-motile rod, often in pairs.	Small, non-motile rod.
Flagella	Not observed.	Not observed.	Not observed.	Not observed.	Not observed.
Gram's stain	Negative.	Negative.	Negative.	Negative.	Negative.
Surface colonies on a gelatine plate	Thin bluish-grey film with irregular margin, surface of colony corrugated. Medium not liquefied.	Same as I.	Same as I.	Same as I.	Thin pearly-grey expansion with irregular margin. Surface granular or ridged. No liquefaction.
Growth on gelatine slope	Delicate thin pearly growth with dentated margin.	Similar to I.	Similar to I.	Similar to I.	Same as Flexner.
Growth on agar slope	Moist grey growth.	Same as I.	Same as I.	Same as I.	Same as Flexner.
Growth in broth	Diffuse growth; no pellicle.	Same as I.	Same as I.	Same as I.	Same as Flexner.
Milk at 37° C.	No clot.	No clot.	No clot.	No clot.	No clot.
Peptone and salt solution	No indol.	Indol.	No indol.	Indol.	No indol.
1 % glucose peptone at 37° C.	N.G. acid, 5 %	N.G. acid, 5 %	N.G. acid, 5 %	N.G. acid, 5 %	N.G. acid, 6 %
1 % lactose peptone at 37° C.	Unchanged.	Unchanged.	Unchanged.	Unchanged.	Unchanged.
1 % sucrose peptone at 37° C.	Idem.	Idem.	Idem.	Idem.	Idem.
1 % maltose peptone at 37° C.	Idem.	N.G acid, 5 %	Idem.	N.G. acid, 3 %	N.G. acid, 4 %
1 % mannite peptone at 37° C.	Idem.	N.G. acid, 5 %	Idem.	N.G. acid, 4 %	N.G. acid, 4 %
1 % galactose peptone at 37° C.	Idem.	N.G. acid, 6 %	Idem.	N.G. acid. 5 %	N.G. acid, 3 %
Proskauer and Capaldi's media, No. 1	No growth.	No growth.	No growth.	No growth,	No growth.
Proskauer and Capaldi's media, No. 2	Acid growth.	Acid growth.	Acid growth.	Acid growth.	Growth. Reaction faintly acid.
Nitrate broth	Reduces.	Reduces.	Reduces.	Reduces.	Reduces.
Neutral red glucose	Unchanged.	Unchanged.	Unchanged.	Unchanged.	Unchanged.
Anaerobiosis	Growth.	Growth.	Growth.	Growth.	Growth.

some Varieties of Dysentery Bacilli.

Gray	Pickering.	Landon.	Shiga, I, II, and III.	Kruse I and II.	Vaillard.
Small, non-motile rod.	Small, non-motile rod.	Small, non-motile rod.	Small, slender, non-motile rod.	Small, non-motile rod.	Small, non-motile rod.
Not observed.	Not observed.	Not observed.	Not observed.	Not observed.	Not observed.
Negative.	Negative.	Negative.	Negative.	Negative.	Negative.
Same as the Harris.	Of the Flexner type.	Similar to the Flexners.	Similar to the Flexners, but more granular with well-marked ridges. Margins irregular. Slower in growth than Flexners. No liquefaction.	Very similar to the Shiga type. Not so slow in growing.	Similar in type to the Shigas, but growing more rapidly.
Same as Flexner.	Same as Flexner.	Same as Flexner.	Slow-growing, fine, pearl-like growth with crenated edge.	Similar to the Shigas.	Similar to the Shigas.
Same as Flexner.	Same as Flexner.	Same as Flexner.	Same as Flexner.	Same as Flexner.	Same as Flexner.
Same as Flexner.	Same as Flexner.	Same as Flexner.	Same as Flexner.	Same as Flexner.	Same as Flexner.
No clot.	No clot.	No clot.	No clot.	No clot.	No clot.
Indol.	Indol.	Trace of indol.	No indol.	No indol.	No indol.
N.G. acid, 4 %	N.G. acid, 3 %	N.G. acid, 5 %	N.G. acid, 4 %	N.G. acid, 5 %	N.G. acid, 3 %
Unchanged.	Unchanged.	Unchanged.	Unchanged.	Unchanged.	Unchanged.
Idem.	Idem.	Idem.	Idem.	Idem.	Idem.
N.G. acid, 4 %	N.G. acid, 3 %	N.G. acid, 4 %	Idem.	Idem.	Idem.
N.G. acid, 4 %	N.G. acid, 4 %	N.G. acid, 3 %	Idem.	Idem.	Idem.
N.G. acid, 2 %	N.G. acid, 3 %	N.G. acid, 2 %	Idem.	Idem.	Idem.
No growth.	No growth.	No growth.	No growth.	No growth.	No growth.
Acid growth.	Acid growth.	Acid growth.	Growth. Reaction unchanged.	Growth. Reaction unchanged.	Growth. Reaction unchanged.
Reduces.	Reduces.	Reduces.	Reduces.	Reduces.	Reduces.
Unchanged.	Unchanged.	Unchanged.	Unchanged.	Unchanged.	Unchanged.
Growth.	Growth.	Growth.	Growth.	Growth.	Growth.

Shiga's bacillus, gave a serum agglutinating at 1 in 200, the Flexner I and III, Kruse, Vaillard varieties, but affecting the Shiga strains only at 1 in 80, and Flexner II and IV not at all.

A polyvalent anti-colon horse serum, obtained from Dr. Dowson, was efficient against Shiga I at a dilution of 1 in 40, Flexner I at 1 in 100, Flexner II at 1 in 80, Gray, Harris, and Landon at 1 in 60, and Pickering at 1 in 30. A second sample of anti-colon horse serum, kindly given me by Dr. Dowson, practically failed to touch any one of the various strains of dysentery bacilli.

These results leave little doubt as to the close identity of the several bacilli with which the various observations have been made. At the same time, it is clear that while the agglutinating properties of the bacilli from different dysenteric sources are very much the same, still there are differences in degree. Certain strains react better with a given serum than do others, especially if relatively high dilutions are used. Many of the sera were undoubtedly weak, and possibly this may explain why certain varieties of bacilli refused to react. The rabbit is not an ideal animal from which to obtain serum for this purpose, the goat and the horse being better; but the circumstances under which this part of the inquiry had to be made did not permit of the use of these animals. But, as will be seen later, the agglutinative functions of horse sera, following immunisation with given strains of these bacilli, are very much in accord with those obtained from rabbits. Apart from this, the irregular agglutination phenomena noted as the result of attempts to obtain active sera after immunisation may be due to the formation of secondary agglutinins. Certain observations of Posselt and Segasser show that if one exhausts an agglutinating serum, by the addition to it of various micro-organisms, the absorption or fixing of agglutinins is not strictly specific, inasmuch as the immunising micro-organism absorbs not only the specific agglutinins but also at times those secondary agglutinins or those specific to allied bacteria. At other times these secondary agglutinins may even increase instead of remaining stable or diminishing after the absorption of the specific agglutinins by the specific micro-organism. As explanatory of some of the difficulties surrounding the behaviour of dysenteric sera, Shiga has suggested the existence of certain hindering substances or

pro-agglutinoids, in an immunised serum which need to be fixed by the specific organism before the specific agglutinins can attach themselves. Whatever may be the true explanation of the phenomena, an impartial review of this section clearly indicates that the formation of specific agglutinins, certainly in rabbits, as the result of gradual inoculations with dysentery bacilli, is both variable and feeble, and too much importance must not be placed upon either negative or positive agglutination reactions. Experience with the human subject accords with the view, as the specific agglutination reaction with the serum from persons suffering from dysentery can only be obtained normally within the two first weeks following the onset of acute symptoms, and even then is often slight. As will be seen from what follows, there is much reason to believe that infection with bacilli of this group is not of the nature of a general septicæmia involving a constitutional reaction, but rather of the nature of a local cytolysis. If this be the case, then the absence of specific agglutinins from the general circulation is intelligible.

Outside the body all these so-called dysentery bacilli are possessed of some considerable viability. Thus, if dried in soil or on fabrics, they survive some twenty-one days; while, if placed in tap water and maintained at 22° C., they are recoverable up to one hundred and sixty days, and, if kept at 37° C., are recoverable up to forty-three days. When placed in sterile water and kept in the dark at 22° C., they continue to survive for nine months. If spread upon ordinary bread, these bacilli survive eleven days. In their viability characteristics, these micro-organisms present resemblances to the typho-coli family. To the *Bacillus coli communis* these dysentery bacilli present no cultural resemblances, but the mannite-splitting members of the group are culturally very like the enteric bacillus, the most notable difference between them being the general ability to make indol and the inability to be affected by an enteric serum. This mannite-splitting group of so-called dysentery bacilli is practically identical with a class of bacteria common in sewage and dirty water, to which the name *B. typhosus simulans* was given by Houston. In fact, the strains Flexner II and IV, and Harris, Gray, Pickering, and Landon all were agglutinated at 1 in 60 by a serum obtained from a rabbit immunised with

a strain of *B. typhosus simulans* isolated from a sewage-polluted water. The same serum was inactive against the non-mannite-splitting dysentery bacilli. These latter appear culturally, and as we shall see later also pathologically, to be quite a specific variety, differing from both the enteric bacillus and the *B. typhosus simulans* by virtue of their failure to split mannite and their inability to be affected either by an enteric serum or by one resulting from immunisation with Houston's organism. These, we shall see, are to be regarded as the true *B. dysenteriæ*.

(B) *The experimental evidence as to the pathogenicity of dysentery bacilli.*

Whilst fully admitting the value of the constant presence of a given bacillus in the stools of persons suffering from dysentery, and of the fact that that bacillus is usually agglutinated by the serum of the affected person, as evidence of its specific pathogenicity, still the crucial test depends upon the ability to produce the disease experimentally by means of pure cultures of the micro-organism. Until the publication of Vaillard's results at Vincennes, the experimental facts as to dysentery have been somewhat ambiguous.

As to the pathogenic effects of the dysentery bacillus upon man, the evidence is necessarily somewhat small, but even on this point it is not wanting absolutely. Strong reports the case of a Filippino prisoner, under sentence of death, who was induced to swallow a culture of the dysentery organism isolated in Manilla. The man suffered from the usual symptoms. The value of this case is somewhat lessened by the fact that dysentery was epidemic at the time. Shiga had one-twelfth of an agar culture, suspended in bouillon and killed by heat, injected into his own back. The immediate results of this injection were pain in the head, slight chill, and fever. After six days, beyond the formation of a small abscess at the point of inoculation, the toxic symptoms passed off. Shiga's blood-serum, however, showed active agglutination of the bacillus ten days after the injection. Flexner relates the experience of one of his laboratory assistants in Baltimore, who, while manipulating the bacillus from Manilla, accidentally aspirated a small quantity of fluid culture into his mouth. Notwithstanding immediate expectora-

tion and free lavation of the mouth with a weak disinfectant, severe diarrhœa, with bloody and mucous stools, pain and tenesmus, developed within forty-eight hours.

On animals a considerable number of experiments have been made by various observers, but owing to the extreme susceptibility of most of the ordinary animals to the toxins of the dysentery bacillus, lesions of the intestines analogous to those occurring in man, when suffering from the disease, have been but rarely demonstrated. That they do result, however, has been successively maintained by Shiga, Flexner, Kruse, Vaillard, and others, who report having caused marked enteritis, affecting chiefly the colon, in which the mucous membrane was œdematous, congested and beset with superficial necroses. The most emphatic lesions appear to have been produced in the dog, in the cat, in young pigs, and in rabbits. The horse reacts strongly to inoculations with the dysentery bacillus, and not infrequently is killed by a small dose. The goat is more resistant, but rats, mice, and guinea-pigs are quickly and easily affected, dying apparently from an acute toxæmia. The channels of experimental infection have been various. Ingestion with food and by an œsophageal tube, even after preliminary neutralisation of the gastric contents or exhibition of an irritant, have not been very successful, while even the direct introduction of pure cultures into the small intestine, after laparotomy, in a dog produced no appreciable effect. Intravenous injection of small quantities of a culture kills rabbits, dogs and small pigs in a few hours without allowing any definite lesions to be established. In large doses, even subcutaneous injection is fatal to most animals, and in the dog, cat, pig, and rabbit produces paralysis of the hind legs, with variable effects on the large intestine.

This aspect of the question has been the subject of considerable personal inquiry, and the following details furnish the results of my experiments as to bacillary dysentery in the rabbit. Various rabbits have not only been fed for days with cabbages soaked in fresh cultures of various strains of these dysentery bacilli, but also have had considerable quantities passed into their stomachs by means of an œsophageal tube, but in no case has the ingestion of the bacilli given rise to any symptoms or signs of ill-health. Subcutaneous injections of emulsions in sterile water of twenty-four hours old living growths on agar

slopes of various strains of these bacilli have given rise to variable effects according to the particular strain employed and the dosage. Injections of the whole of a twenty-four-hour-old agar slope culture, emulsified in sterile water, of the different strains of Flexner II and IV, Pickering, Landon, Harris, and Gray, while producing certain agglutination functions of the blood serum, practically gave rise to no intestinal disturbance or lesion or any symptoms other than a temporary fall in temperature of about 1° C., lasting for a couple of days. On the other hand, injections of the Shiga, Kruse, Vaillard, and Flexner I and III strains produced serious disturbance. In doses of a sixth to a fourth of a twenty-four-hour growth on an agar slope of these strains there was merely a temporary fall in temperature, following an initial rise, but in larger doses, varying from one third to three fourths of an agar slope culture, according to the size and weight of the rabbit, after an initial rise in temperature there was a marked lowering of body heat, with paralysis of the hind legs, progressive enfeeblement, and death about the fourth or fifth day. In but a few cases was there any actual diarrhœa, but on *post-mortem* examination the small intestine was found generally to be filled with a glairy mucus, and the mucous membrane somewhat œdematous or thickened. The large bowel was found usually to be tumefied or œdematous, with here and there congested or hæmorrhagic patches, while commonly in the cæcum necrotic patches, involving large areas of mucous membrane, leading to local sloughs and ulcers, were to be found. Plate VIII illustrates, in a very faithful manner, the lesion found in the cæcum of a rabbit after the subcutaneous injection of two thirds of a twenty-four-hour agar slope culture of the bacillus mentioned in this paper as Shiga I. Sections made of the diseased patches of the intestinal wall show an extensive bacterial invasion of the mucous and submucous layers, the bacilli being generally disseminated, but in places collected into clumps or masses. Cultures made from the heart's blood, spleen, kidneys, liver, and mesenteric glands invariably gave negative results. Sections made of the liver, spleen, and kidneys failed to show any bacilli in those viscera, but sections of mesenteric glands indicated in a few instances their invasion with bacteria.

The intestinal lesions produced in the rabbit by subcutaneous

NG

en rise
oyed a
our-hou
differe
rris, a
s of th
urbanc
in tem
e othe
xner
s of a
agar
all in
rying
rding
se it
with
eath
here
nail
us.
ed
us.
ile
as
re

EXPLANATION OF PLATE VII,

Illustrating the communication on "Bacillary Dysentery" by Lieut.-Col. Firth. (P. 340.)

Photographs of six bacillary colonies, magnified 30 times.

Each figure represents a colony of a true dysentery bacillus; the bacilli are from different strains, as noticed in the text. The colonies are each of 72 hours' growth.

TABULA VII.

Ad dissertationem "De Dysenteriâ" illustrandam.
R. H. Firth. (P. 340.)

Bacillorum coloniæ (× 30, Horarum 72) ex casibus dysenteriæ diversis.







Colony of B. Dysent. (Shiga III.)
72 hrs. × 30.

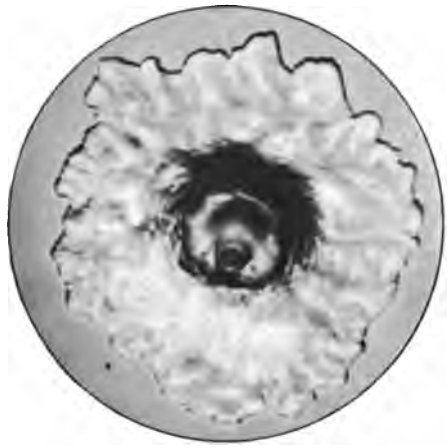

Colony of B. Dysent. (Flexner III.).
72 hrs. × 30.

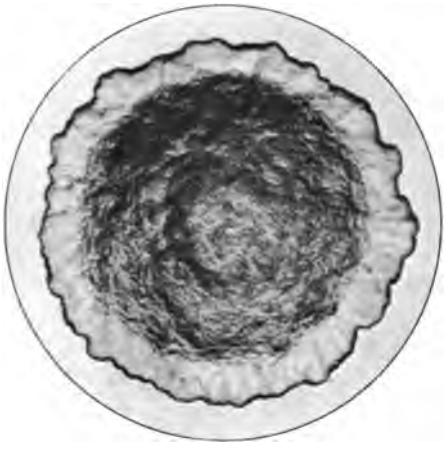

Colony of B. Dysent. (Kruse II.).
72 hrs. × 30.

Colony of B. Dysent. (Vaillard).
72 hrs. × 30.

Colony of B. Dysent. (Harris).
72 hrs. × 30.

Colony of B. Dysent. (Pickering).
72 hrs. × 30.

Sale, Sons and Danielsson, Ltd.

EXPLANATION OF PLATE VIII,

Illustrating the communication on "Bacillary Dysentery" by Lieut.-Col. Firth. (P. 340.)

Portion of the colon of a rabbit, into the subcutaneous tissue of the back of which was injected a suspension made from an entire agar slant of a living culture (24 hours age) of a true dysentery bacillus. Death occurred four days afterwards.

For a considerable extent the mucosa is intensely congested, and in places passing into a sloughing condition.

TABULA VIII.

Ad dissertationem "De Dysenteriâ" illustrandam.
R. H. Firth. (P. 340.)

Colon cuniculi cujus in telâ cellulosâ subcutaneâ injecta est cultura bacilli dysenteriæ (agar 37° C., Horarum 24). Animal die quinto mortuum est.

Mucosa intestinalis maxime congesta, atque locis in diversis necrotica est.

TABULA VIII.

[illegible] Dysenteriâ" illustrandam.

[illegible]

injections of certain strains of these dysentery bacilli bear a striking resemblance to those characteristic of the disease in man. The most remarkable fact is, however, the selective affinity which the micro-organism displays for single viscera, viz. the cæcum and large intestine, directing upon their tissues all its effects, and apparently not touching any other organs. At the point of inoculation there results a temporary tumescence, and marked by a slight local development of the injected bacilli, but this is evidently but transitory, the micro-organisms either getting into the blood stream and quickly finding their way to the elective tissues, where their toxic action produces rapidly necrotic effects; or, undergoing bacteriolysis in the blood, their liberated toxins exert gradually a specific action on the intestinal mucous membrane.

The general failure to produce pathogenic effects by means of these bacilli when administered by the mouth or in food has been emphasised. In the rabbit this is very marked, but in the case of a monkey (Rhesus) which received 50 c.c. of a fresh broth culture of Shiga's bacillus, marked diarrhœa was set up within forty-eight hours, and when the animal was killed by chloroform on the sixth day, typical ulcerations were found in the upper part of the large bowel. Cultures set from the viscera and heart's blood indicated a complete absence of general infection, in this respect conforming with experiences in man. No micro-organisms were isolated from the mesenteric glands.

The marked effects which result from the injection of living cultures of certain strains of these bacilli suggest the questions, What results are produced by these bacilli if killed by heat or by some chemical reagent, such as chloroform? and further, Do these bacilli secrete or contain a toxin? These various points have been investigated with the following results:

An exposure to 60° C. for half an hour kills all strains of the dysentery bacilli. Intravenous or hypodermic injections of emulsions of dead bacilli of the Shiga, Kruse, Vaillard, and Flexner I and III strains, which had been killed by an exposure to this temperature, gave rise in rabbits to symptoms similar to those produced by the corresponding living cultures, the essential difference being that the fatal effect was somewhat delayed. If a culture of these bacilli on an agar slope be killed by exposure to chloroform vapour, and the dead bacilli be worked up into an

emulsion in sterile salt solution, a fatal effect in rabbits, with intestinal lesions in the cæcum and large bowel, follows a subcutaneous injection about the fourth day, marked also by hypothermia and paralysis of the hind legs.

Whether the dysentery bacilli secrete a soluble toxin has been a debated point, chiefly owing to the fact that the filtrates from ordinary peptone broth cultures are only slightly toxic for animals. But if the bacilli be grown in a definitely alkaline broth, that is, one to which normal caustic soda solution has been added in the proportion of 7 c.c. per litre, highly toxic filtrates can be obtained. At least, rabbits succumb to hypodermic injections of 5 c.c. of the sterile filtrate from a four-day-old alkaline broth culture incubated at 37° C., obtained by filtration through a porcelain filter. The resulting symptoms during life and effects on the agglutinating powers of the blood serum are practically identical with those produced by injections of living bacilli, while the *post-mortem* appearances are extensive necrotic changes in the mucous membrane of the cæcum and large bowel. Toxic filtrates have been obtained in this way from cultures of the Shiga, Kruse, Vaillard and Flexner I and III strains, but not from the other strains, which were non-pathogenic when injected as emulsions of living bacilli. The toxicity of the filtrate is enhanced by growing the bacilli in the alkaline broths for longer periods; in this way, after a month's growth, a filtrate was obtained which was so toxic that it killed a rabbit at a dose of 0·2 c.c. This toxin, apparently secreted by the bacilli into broth in which they are growing, is fairly stable, being not destroyed by heating to 70° C. for half an hour, but is no longer pathogenic to rabbits after an exposure to 75° C. for half an hour. Injections of this now no longer toxic material are still capable of setting up specific agglutination power in the blood serum, and also of rendering the animal distinctly refractive to lethal doses of living dysentery bacilli. This suggests the existence of two bodies in the material, namely a labile toxic and a stable functional substance. Even when unheated to 70° C. the toxin is not hæmolytic for the corpuscles of the rabbit, but it is markedly cytolytic to the epithelial cells freshly scraped from the cæcum and large intestine of that animal, but feebly so to those scraped from the small bowel.

A similar but more powerful toxic substance can be dissolved

out of the dead bacilli by digestion in water. Following the lines suggested by the work of Conradi, Neisser and Shiga, six agar slope cultures of Vaillard's strain of the dysentery bacillus were incubated at 37° C. for twenty-four hours. These cultures were then killed by an exposure to chloroform; the dead bacilli were then scraped off the agar and worked up into an emulsion with 50 c.c. of sterile salt solution. This was allowed to autolyse for fourteen days at 37° C. The emulsion was then centrifugalised and the supernatant clear liquid pipetted off and filtered through a porcelain filter. An intravenous injection of 1 c.c. of this sterile liquid into a rabbit weighing 2·1 kilogrammes caused death in seventeen hours. A subcutaneous injection of 2 c.c. into a rabbit of similar size caused hypothermia, paralysis of the hind legs, and some diarrhœa. On being killed, under chloroform, an examination of the body showed extensive ecchymoses and superficial necrosis of the mucous membrane of the cæcum—in fact, similar lesions to those caused by injections of the living bacilli and their toxins secreted into broth. Some of this aqueous extract of dead bacilli was heated to 65° for half an hour: its toxicity was not sensibly lessened when hypodermically injected into a rabbit. Exposure to 75° C. for half an hour rendered it no longer toxic. Similar observations were made with the toxins dissolved out of dead bacilli of the Shiga, Kruse and Flexner III strains, and with the same results; but the strains referred to as Pickering, Landon, Flexner II, Harris and Gray failed to yield similar toxins.

The following experiment was made, on analogous lines to some work done by Carega in respect of *B. coli*, with a view to determine, if possible, the nature of the active substances apparently contained in the bodies of the pathogenic strains of these dysentery bacilli. Half a litre of broth was inoculated with the bacillus Shiga II, and incubated at 37° C. for sixteen days. Over a water-bath at 50° C. the culture was reduced to half its volume and the contained proteids precipitated by the addition of 200 c.c. of absolute alcohol. The precipitate was collected and digested in 50 c.c. of a 0·5 per cent. solution of caustic soda for twenty-four hours. After filtration the precipitate was dried at 40° C. This substance was set aside as being presumably a nuclein. The clear alkaline filtrate was

then acidified with acetic acid, and the resulting precipitate, collected on a filter, washed with very dilute acetic acid and finally dried at 40° C. This substance, which weighed 0·08 gramme, was deemed to be a nucleo-albumen: the nuclein, previously separated, weighed 0·12 gramme. The nuclein was rubbed up with sterile water and sterilised at 60° C. on three successive days; 0·005 gramme injected into the ear vein of a rabbit caused death within a quarter of an hour; given hypodermically, in a dose of 0·02 gramme, it caused at first some local irritation; on repeating the dose every three days a cumulative toxic effect was produced, the animal dying after the third dose. No appreciable lesions were noticeable, neither was the blood rendered capable of agglutinating any dysentery bacilli. The toxicity of this nuclein was not sensibly diminished after half an hour's exposure to 65° C. The nucleo-albumen, on the other hand, had feeble toxic powers, though it was capable of establishing some specific agglutination reaction in the serum. This function was not nullified absolutely by an exposure to 65° C. for half an hour. There was no evidence of any immunising power. These observations were repeated with one of the Kruse strains and similar results obtained.

Recognising the apparent elective affinity which the pathogenic strains of the dysentery bacilli have for certain parts of the intestinal tract when injected into the general circulation, and the difficulty experienced to secure infection by ordinary feeding with dysentery bacilli, it appeared desirable to determine whether there was any evidence of the existence of neutralising substances for the toxins of these bacilli in any of the tissues of the rabbit's body, especially in the epithelia of the mucous membrane of the bowel. To clear up these points the following experiments were carried out. Laparotomy was performed on two healthy rabbits; into the cæcum of one was injected by means of a fine needle an emulsion, made in sterile water, of two twenty-four-hour-old agar slopes of Vaillard's bacillus of dysentery, while into the bowel of the other rabbit 20 c.c. of freshly filtered broth from a four-day-old bouillon culture of Shiga's bacillus were injected. In neither case was there the slightest evidence of discomfort or illness. A week later, on the rabbit which had received the soluble toxins, a second laparotomy was performed, and an emulsion of living bacilli from two twenty-

four-hour-old agar slopes of the same strain injected into the cæcum. At the end of a fortnight the animals were killed; the intestinal mucous membrane in both was quite normal. It will be remembered that smaller doses of the same culture and filtrate, when given subcutaneously, were markedly pathogenic.

These results clearly suggest the existence in the mucous membrane of the rabbit's intestinal tract of some substance protective to attacks by the bacilli or their toxins. To further elucidate the point the following experiments were made: A healthy rabbit was selected and killed under chloroform, the spleen, some liver tissue, kidney, voluntary muscle, and portion of cæcum and large intestine were rapidly removed and placed in sterile normal salt solution at 37° C. The tissues were rapidly washed in the saline, and two grammes each of spleen, liver, kidney, and voluntary muscle rubbed up in a sterile mortar with an emulsion made from a twenty-four-hour agar slope of Shiga's bacillus. The portion of bowel removed measured some ten inches in length; the mucous surface was carefully scraped with the back of a sterile knife, so as to remove practically all the mucous membrane. This emulsified material, measuring about 4 c.c., was now rubbed up with an emulsion in saline solution made from the scraped surface of a twenty-four-hour agar slope of Shiga's bacillus. All the mixtures were transferred to sterile test tubes and incubated for two hours at 37° C. They were then centrifugalised, and 5 c.c. of each of the clear supernatant fluids injected subcutaneously into five rabbits, a sixth being taken for a control injection with the same bacillus. The results were as follows: The control died on the third day, the liver, spleen, kidney, and voluntary muscle animals all died between the fourth and fifth days, the symptoms and *post-mortem* appearances being similar in each case to those already described, and to that of the control animal, namely, hæmorrhages and necrotic lesions in the mucous membrane of the cæcum and large intestine. The animal which received the emulsion of bacilli and intestinal mucous membrane survived till the ninth day, when owing to the onset of posterior paralysis it was killed. The lesions found were a few small hæmorrhagic necroses in the cæcum. A second experiment was made on similar lines; in this case the anti-toxic influences of the intestinal epithelia were shown in an even more marked

manner, as the injected animal presented little or no discomfort and recovered. It is legitimate to infer from these experiments that, at least in the rabbit, some protective body exists in the normal intestinal mucous membrane which is antagonistic to the toxic and specific action of the dysentery bacilli. Further, attempts to establish dysenteric lesions in the rabbit by direct infection of the alimentary canal have so far been negative, neither is it clear what conditions of the bowel need to be established in order to secure the specific action of these bacilli upon the mucous membrane when brought into contact with its epithelia.

(c) *The prospects of protective inoculation and serumtherapy against dysentery.*

Arising, naturally, from these experimental observations as to the specific action of these bacilli is the question of securing immunity from their effects. Before discussing my own experiments relating to this topic, it is desirable to refer briefly to the work of others. The same question has been approached by Shiga in Japan, Gay in America, and Todd in this country. The former has produced a serum, by immunising goats with cultures killed by heat, which he reports to be both protective and curative. He employed it in an extensive epidemic in Japan, with a death-rate of 9·6 per cent., while the mortality during the same period in the same epidemic under ordinary treatment was 34·7 per cent. Gay's work also covers inquiries as to the protective power of immunised horse serum on guinea-pigs against living cultures of *B. dysenteriæ*. He finds that a vaccine made from dead bacilli is sufficient to protect guinea-pigs from a succeeding multiple fatal dose of living dysentery bacilli, and to produce in the horse an active immune serum. This immune serum of the horse exhibits marked protective properties on guinea-pigs against fatal infection with *B. dysenteriæ* or its toxin. Todd's work has been on slightly different lines, and accords largely with my own observations as to the production of a soluble toxin from dysentery bacilli, when grown in a somewhat highly alkaline broth. He also shows that when injected into suitable animals, for example, the horse, the toxin gives rise to a powerful antitoxin. The antitoxic serum so

obtained differs from the anti-bacterial sera of Shiga and Gay inasmuch as it does not protect against either the living or dead bacilli of dysentery.

In approaching this question of securing immunity against dysentery, it has seemed to me desirable, in respect of any serum to distinguish not only between the two functions of agglutinability and bactericidal efficiency, but also to determine, if possible, how far each or both were correlated to anti-toxicity and to the production of immunity against infection. From the facts, which have already been enunciated in this paper, as to certain cultural variations in the strains of bacilli examined and distinctions in their agglutinability, it is permissible to regard these differences as indicative of two groups of dysentery bacilli, namely, acid and non-acid producers in mannite and, further, to raise the question whether they are to be recognised as one or two species. To determine these questions it was clearly desirable to obtain sera from horses immunised respectively with both types of dysentery bacilli. Sera from horses immunised respectively with Shiga II (a non-mannite fractor) and Pickering (a mannite fractor) were obtained, each agglutinating their own parent strains to 1 in 10,000. The accompanying Table II and Table III show the effects of these sera in varying dilutions upon different varieties of dysentery bacilli.

TABLE II.—*Agglutination with Serum from Horse immunised against Shiga II.*

Strain of dysentery bacillus.	Whether or not a mannite fractor.	1 in 100.	1 in 200.	1 in 500.	1 in 600.	1 in 800.	1 in 1000.	1 in 2000.	1 in 4000.	1 in 5000.	1 in 6000.	1 in 8000.	1 in 10000.
Flexner I	No	+	+	+	+	+	+	+	+	+	+	—	—
Flexner II	Yes	+	+	+	+	+	—	—	—	—	—	—	—
Flexner III	No	+	+	+	+	+	+	+	+	+	—	—	—
Flexner IV	Yes	+	+	+	+	+	+	—	—	—	—	—	—
Harris	Yes	+	+	+	+	+	+	+	—	—	—	—	—
Gray	Yes	+	+	+	+	+	+	—	—	—	—	—	—
Pickering	Yes	+	+	+	+	—	—	—	—	—	—	—	—
Landon	Yes	+	+	+	+	+	—	—	—	—	—	—	—
Shiga I	No	+	+	+	+	+	+	+	+	+	+	+	—
Shiga II	No	+	+	+	+	+	+	+	+	+	+	+	+
Shiga III	No	+	+	+	+	+	+	+	+	+	+	+	+
Kruse I	No	+	+	+	+	+	+	+	+	+	+	—	—
Kruse II	No	+	+	+	+	+	+	+	+	+	+	+	—
Vaillard	No	+	+	+	+	+	+	+	+	+	+	+	—

The figures in the table show clearly that, although a relationship is apparent between the serum and the variety or type of bacilli, the disparity is not so marked as one would have expected. The probable explanation lies in the fact that th sera were powerful ones.

TABLE III.—*Agglutination with Serum from Horse immunised against Pickering.*

Strain of dysentery bacillus.	Whether or not a mannite fractor.	1 in 100.	1 in 200.	1 in 500	1 in 600.	1 in 800.	1 in 1000.	1 in 2000.	1 in 4000.	1 in 5000.	1 in 6000.	1 in 8000.	1 in 10000
Flexner I	No	+	+	+	+	+	+	+	+	+	—	—	—
Flexner II	Yes	+	+	+	+	+	—	—	—	—	—	—	—
Flexner III	No	+	+	+	+	—	—	—	—	—	—	—	—
Flexner IV	Yes	+	+	+	+	—	—	—	—	—	—	—	—
Harris	Yes	+	+	+	—	—	—	—	—	—	—	—	—
Gray	Yes	+	+	+	+	+	—	—	—	—	—	—	—
Pickering	Yes	+	+	+	+	+	+	+	+	+	+	+	+
Landon	Yes	+	+	+	+	+	+	+	—	—	—	—	—
Shiga I	No	+	+	+	+	—	—	—	—	—	—	—	—
Shiga II	No	+	+	+	+	+	+	—	—	—	—	—	—
Shiga III	No	+	+	+	+	+	+	—	—	—	—	—	—
Kruse I	No	+	+	+	+	+	—	—	—	—	—	—	—
Kruse II	No	+	+	+	+	+	+	—	—	—	—	—	—
Vaillard	No	+	+	+	+	+	+	—	—	—	—	—	—

Certain further observations made showed that, notwithstanding their high agglutinative functions, the bactericidal power of these immune sera was practically *nil.* Others have noted the same fact, but both Shiga and Gay have pointed out that the bactericidal power of such anti-dysenteric sera can be demonstrated *in vitro* by activating them with normal horse serum. The method adopted is that devised by Neisser and Wechsberg, who show that a fixed amount of normal complement-containing serum, in itself incapable of causing bacteriolysis, will destroy a given amount, by weight, of the dysentery bacillus, in the presence of a definite quantity of complement-free immune serum. The Tables IV and V indicate the bactericidal effect on each type of dysentery bacillus of the inactive anti-dysenteric sera *plus* complement-containing fresh normal horse's serum. It will be noted that the addition of an amount of immune serum greater or less than that exactly requisite

permits of more or less unrestricted growth of the micro-organisms. In the case of an amount of immune serum added less than that exactly needed, the resulting growth may be explained on the assumption of an insufficiency of bacteriolytic amboceptor, while in the case of a surplus of immune serum there is probably an excess of amboceptor, through which the complement becomes diverted from the bacteria by union with free amboceptors. These tables are instructive as showing that, in spite of using a fixed mean of immune serum to bring about the destruction of a definite amount of dysentery bacilli in the presence of a sufficiency of complement, no evidence of bactericidal action is obtained when a variety of serum and a strain of dysentery bacillus, not in conformity with each other, is employed.

TABLE IV.—*Bactericidal Effect of the Two-Horse Sera on B. Flexner II (a Mannite Fractor).*

Amount of culture of Flexner II.	Pickering horse-serum (mannite fractor).	Normal horse-serum.	Colonies on plate after 10 hours.	Amount of culture of Flexner II.	Shiga II horse-serum (non-mannite fractor).	Normal horse-serum.	Colonies on plate after 10 hours.
mgm.	c.c.	c.c.		mgm.	c.c.	c.c.	
0·05	0·1	0·25	7000	0·05	0·1	0·25	8500
„	0·05	„	1500	„	0·05	„	8000
„	0·005	„	92	„	0·005	„	Countless.
„	0·002	„	63	„	0·002	„	„
„	0·001	„	45	„	0·001	„	„
„	0·0005	„	8000	„	0·0005	„	„
„	0·0002	„	7800	„	0·0002	„	„

TABLE V.—*Bactericidal Effect of the Two-Horse Sera on B. Shiga II (a non-Mannite Fractor).*

Amount of culture of Shiga II.	Pickering horse-serum (mannite fractor).	Normal horse-serum.	Colonies on plate after 10 hours.	Amount of culture of Shiga II.	Shiga II horse-serum (non-mannite fractor).	Normal horse-serum.	Colonies on plate after 10 hours.
mgm.	c.c.	c.c.		mgm.	c.c.	c.c.	
0·05	0·1	0·25	Countless.	0·05	0·1	0·25	Countless.
„	0·05	„	„	„	0·05	„	„
„	0·005	„	„	„	0·005	„	„
„	0·002	„	„	„	0·002	„	80
„	0·001	„	„	„	0·001	„	114
„	0·0005	„	„	„	0·0005	„	90
„	0·0002	„	„	„	0·0002	„	Countless.

This fact has been pointed out by Gay, and my results practically agree with his. The next Table, VI, is interesting as being confirmative of the preceding ones, and of Shiga's statement that an anti-dysenteric serum can be activated *in vitro* by human

TABLE VI.—*Bactericidal Effect on B. Shiga II (a non-Mannite Fractor) of the two-horse Sera when activated with Human Blood.*

Amount of culture of Shiga II.	Pickering horse serum (mannite fractor).	Normal human serum.	Colonies on plate after 10 hours.	Amount of culture of Shiga II.	Shiga horse serum (non-mannite fractor).	Normal human serum.	Colonies on plate after 10 hours.
0.05 mgm.	0·10 c.c.	0·25 c.c.	Countless	0·05 mgm.	0·10 c.c.	0·25 c.c.	Countless
"	0·05 c.c.	"	"	"	0·05 c.c.	"	"
"	0·02 c.c.	"	"	"	0·02 c.c.	"	"
"	0·01 c.c.	"	"	"	0·01 c.c.	"	"
"	0·005 c.c.	"	"	"	0·005 c.c.	"	"
"	0·002 c.c.	"	"	"	0·002 c.c.	"	1100
"	0·001 c.c.	"	"	"	0·001 c.c.	"	330
"	0·0005 c.c.	"	"	"	0·0005 c.c.	"	Countless
"	0·0002 c.c.	"	"	"	0·0002 c.c.	"	"
"	0·0001 c.c.	"	"	"	0·0001 c.c.	"	"

blood complement. The general results, however, are not so good as when normal horse serum is used. Whether the same thing happens *in vitro* we do not know, but some authorities are disposed to doubt the reactivating power of human blood in the living body, and so explain the negative results obtained in man by the use of certain sera.

We may next pass to a consideration of some experiments made with those same sera *quâ* protection against infection by the dysentery bacilli. The animals used have been guinea-pigs and rabbits, but as some considerable evidence on these lines is available from the work of others, notably Gay's comprehensive studies in America, little more has been done than to control their results. The accompanying Table VII illustrates the extent of work done in this direction. The infective material administered in all cases has been a stated quantity of an emulsion made in 10 c.c. of sterile water of the scrapings off a twenty-four-hour-old agar slope culture of a pathogenic variety of the dysentery bacillus. This material was in all cases administered subcutaneously. The general results of these experiments indicate that the protection afforded by these two

sera accords mainly with their agglutinative and bactericidal functions as previously detailed—in other words, that it is dependent upon the particular strain of micro-organism used to produce the serum. It is quite clear that, whether we consider only the bactericidal function or the protecting power of these sera, or both, the facts have an important bearing upon any scheme of serum therapy, as, if the sera obtained by immunising animals with each type of dysentery bacillus (mannite fractors or non-mannite fractors) are only active against their own respective types of micro-organisms, the practical difficulties in the way of dealing specifically with the infections are increased. This has been recognised by others, and it is desirable that further experiments be made with a serum obtained from a horse or goat immunised with or against

TABLE VII.—*Comparative Protective Power of the two anti-dysenteric Horse Sera against two Pathogenic Strains of the* B. dysenteriæ.

Animal.	Weight of animal in grms.	Kind or source of anti-dysenteric serum used.	Dose of serum given 24 hours before, subcutaneously.	Dose of infective material given subcutaneously.	Result.
Guinea-pig	273	Control	Control	1·5 c.c. (Shiga II)	Died sixth day.
„	262	Horse (Shiga II)	2·0 c.c.	1·5 c.c. „	Recovered.
„	260	„ „	2·0 c.c.	1·5 c.c. (Flexner I)	„
„	274	„ „	1·0 c.c.	1·5 c.c. (Shiga II)	Recovered, very ill for a week.
„	280	„ „	0·5 c.c.	1·5 c.c. „	Died fifth day.
„	265	Horse (Pickering)	2·0 c.c.	1·5 c.c. „	Died eighth day.
„	272	„ „	3·0 c.c.	1·5 c.c. „	Died tenth day.
„	290	„ „	5·0 c.c.	1·5 c.c. „	Died fourteenth day.
„	286	„ „	8·0 c.c.	1·5 c.c. (Flexner I)	Died twelfth day.
„	270	Control	Control	1·5 c.c. „	Died fourth day.
Rabbit	2340	„	„	6·0 c.c. (Shiga II)	Died third day.
„	2280	„	„	6·0 c.c. (Flexner I)	Died fifth day.
„	2155	Horse (Pickering)	5·0 c.c.	6·0 c.c. (Shiga II)	Died seventh day.
„	2260	„ „	8·0 c.c.	6·0 c.c. „	Died fifth day.
„	2340	„ „	10·0 c.c.	4·0 c.c. (Flexner I)	Recovered.
„	2290	„ (Shiga II)	5·0 c.c.	6·0 c.c. (Shiga II)	„
„	2210	„ „	5·0 c.c.	6·0 c.c. (Flexner I)	„
„	2180	„ „	3·0 c.c.	6·0 c.c. (Shiga II)	Died ninth day.
„	2090	„ „	8·0 c.c.	10·0 c.c. (Flexner I)	Ill for a week, recovered.
„	2260	„ „	4·0 c.c.	5·0 c.c. (Shiga II)	Paralysed for 2 days, recovered.
„	2180	„ „	5·0 c.c.	8·0 c.c. „	Ill for 5 days, recovered.

both types of dysentery bacillus. I had hoped to have obtained such a bi-valent serum to settle the point, but so far have failed to be able to do so. I am not sanguine that any great degree of protection will be obtained by the use of sera of this nature, as, judging by one's own results, the duration of passive immunity afforded by injections of an anti-dysenteric serum is very short. The few observations which have been made on the point indicate that, in the rabbit, it does not last longer than nine days. It is, however, quite different when active immunity is attempted by giving repeated injections of living or dead dysentery bacilli. Some valuable observations on this point have been made by Gay, using guinea-pigs as subjects of experiment, from which it appears that in these animals the duration of immunity after injections with bacillary vaccines is approximately two months. My own observations, made on rabbits, indicate that refractivity to lethal doses of a virulently pathogenic strain (non-mannite fractor) of the dysentery bacillus lasts for a clear five months after the last injection with a "vaccine" or emulsion made of pathogenic dysentery bacilli, killed by chloroform. This active immunity can be readily established by the subcutaneous injection every five days of one-fourth of a twenty-four-hour-old agar slope culture made into an emulsion, with sterile water, after being killed by exposure to chloroform vapour. The blood of such actively immunised rabbits will agglutinate its own type of dysentery bacillus in a dilution of 1 in 5000 and usually those of the other type (mannite fractors) in lower dilutions up to 1 in 300. I have been unable to secure any such prolonged duration of refractivity in the rabbit to pathogenic dysentery bacilli, following active immunisation with emulsions of the mannite-splitting group of bacilli obtained from dysentery cases, though there is evidence to indicate that there is established a lessened susceptibility to lethal doses of a pathogenic strain (non-mannite fractor) lasting for some ten days. This lessened susceptibility in no case amounted to an absolute protection, thereby endorsing, so far as relates to active immunity, the results obtained as to passive immunity. Certain observations made with emulsions of both types of dysentery organisms—that is, a mixed or bivalent vaccine—are not encouraging as to the possibility of obviating this failure in protection by this means.

There still remains the further question of the anti-toxic action of these sera. Reference has already been made to the fact that from alkaline broth cultures of the non-mannite-splitting group of dysentery bacilli a powerful toxin can be obtained which is capable of giving rise to pathogenic lesions in the rabbit not dissimilar to those resulting from infection with living cultures of the corresponding micro-organism. Observations made as to the protective power of these horse sera against the toxin obtainable from alkaline broth cultures of the dysentery bacilli show that no such protection is afforded. The susceptibility of various animals to this toxin varies, the rabbit and horse being highly susceptible, and the monkey slightly so, while the guinea-pig is markedly resistant. My observations go to show that the minimum lethal dose of the toxin obtainable from the Shiga strain of bacillus after three weeks' growth in alkaline broth is practically 0·1 c.c. for large rabbits weighing 1800 to 2000 grammes when given intravenously, and in no case was any protection afforded by either of the horse sera. We may therefore assume that there is no correlation between agglutinability, bactericidal efficiency and anti-toxicity displayed by sera obtained by immunising horses with various strains of dysentery bacilli.

Reference has been made already to Todd's work, in which he demonstrates that when injected into the horse the dysentery toxin gives rise to a powerful anti-toxic serum, but devoid of any protective power either against living or dead cultures of the dysentery bacillus. Similar observations have been made by Rosenthal; but more recently, by immunising a horse simultaneously with living bacilli and toxin, he reports that he can obtain a serum which is at once anti-microbic and anti-toxic. Moreover, when tried upon 157 actual cases of dysentery, in doses varying from 20 to 140 c.c., the serum diminished the mortality by more than half. These results, if confirmed, are certainly encouraging. So far I have been unable to secure such a serum, but from what one knows regarding this question I am disposed to think that it is upon these lines only a preventive and curative serum will be obtained. The matter is under investigation, and I hope to report upon the results in a future communication.

In attempting to summarise this somewhat imperfect study it seems permissible to formulate the following conclusions:

1. The special bacilli obtainable from the blood and mucus of dysenteric excreta, and which have hitherto been indiscriminately called "dysentery bacilli," constitute two types, according to certain cultural, agglutinative and pathogenic reactions. The cultural and agglutinative reactions are relative, serving to give the two types of so-called dysentery bacilli the characters of a closely related group of micro-organisms. The pathogenic differences serve to distinguish the two types of so-called dysentery bacilli absolutely; and the absolute value of these differences is emphasised by the agglutinative, bactericidal and protective powers of anti-dysenteric sera.

2. The distinctive cultural features of the non-pathogenic type of these so-called dysentery bacilli is an ability to split maltose, galactose and mannite to the formation of acid, but without production of gas, also to produce indol,—characteristics which are wanting in the pathogenic varieties.

3. The term *B. dysenteriæ* should be employed only as referring to the strains of bacilli which are non-mannite fractors and capable of producing the pathogenic lesions characteristic of dysentery, as demonstrable by experimental inoculations in rabbits or other animals. The mannite-splitting bacilli or non-pathogenic forms are the "pseudo-dysentery bacilli" of some authors, but inasmuch as they conform absolutely with a type of bacteria to which the name *B. typhosus simulans* has been given, they may be conveniently spoken of, for the present, by that term. Whether they represent degraded or transitional forms of the true dysentery bacilli we are not in a position to say; neither do we know what is their connection, if any, with the distinctive bacilli associated with enteric fever, and from which they only differ in their inability to be agglutinated by an enteric serum, and their ability to make indol.[1]

[1] Some recent observations which I have made regarding the cultural behaviour in certain carbohydrate media of the micro-organisms referred to in this paper, show that the members of the group described as *B. typhosi simulantes* are capable of making acid in *raffinose* and *salicin*. These reactions, coupled with their behaviour in mannite, enable us to differentiate culturally these bacilli from the *B. dysenteriæ* on the one hand and the *B. typhosi* on the other. Thus, the dysentery bacilli do not produce acid in either mannite, raffinose, or salicin, the enteric bacilli make acid in mannite but not in raffinose or salicin, and the pseudo-dysentery organisms, or, as I have called them, the *B. typhosi simulantes* make acid in mannite, raffinose, and salicin. Members of all three groups make acid in glucose, but fail uniformly to do so in lactose and sucrose.

4. So far as this present inquiry goes, the various strains of Shiga, Kruse, Vaillard, and Flexner I and III are practically identical and should be considered as specimens of *B. dysenteriæ.* The other strains alluded to in this paper, namely, Flexner II and IV, Harris, Gray, Pickering, and Landon, are practically identical one with the other, but are not specimens of *B. dysenteriæ.* They are "pseudo-dysentery bacilli" or *B. typhosi simulantes,* and represent a class of micro-organisms common in sewage and in most dysenteric dejecta during the later stages of the disease and after the acute symptoms have passed off. The true *B. dysenteriæ* are apparently only present to any extent in the intestinal dejecta during the early acute stage of the affection, and then mainly in the blood and mucus.

5. The clinical entities produced by the *B. dysenteriæ,* as now defined, probably represent a group rather than a single class of cases. The cases may range from the typical acute dysentery of camps, through the various stages of ileo-colitis, to the infective diarrhœas of infants and adults. The causative agent in these cases is a micro-organism corresponding to the pathogenic type of bacilli or *B. dysenteriæ* described and defined in this article.

6. By the subcutaneous inoculation of the *B. dysenteriæ,* or their contained and excreted toxic substances into rabbits, symptoms and intestinal lesions characteristic of epidemic dysentery in man can be produced. The toxic substances elaborated by or contained in the bodies of these bacilli have a selective affinity for the mucous membrane of the cæcum and large bowel. But, owing to the apparently high refractiveness of the epithelial lining of the intestinal tract of rabbits to these bacilli and their toxins, the production of intestinal lesions or general infection by them in these animals is not possible either by ordinary methods of ingestion or direct introduction into the various parts of their alimentary canal. Dysenteric lesions can be produced in the monkey (Rhesus) by these bacilli, when administered with food.

7. The prospects of establishing an acquired immunity against bacillary dysentery are not very encouraging. Experiments on both rabbits and guinea-pigs show that passive immunity to the *B. dysenteriæ* is brief, though active immunity is of much longer duration.

8. Human complement is capable of activating an anti-dysenteric serum from the horse.

9. Dysentery vaccines or emulsions of the specific bacilli increase in toxicity for a time, this increase being associated with disintegrative changes in the micro-organisms.

As a considerable number of references have been made to the literature of this subject, a short bibliography is appended, which may be of use to others wishing to look up the papers in their original form.

BIBLIOGRAPHY.

Berghinz.—'Ann. d'Igiene speriment,' 1900.

Brieger and Mayer.—'Deutsch. med. Wochsch.,' 1903, No. 4, p. 61.

Carega.—'Centr. f. Bakt.,' xxxiv, No. 4, p. 323.

Casagrandi.—'Ann. d'Igiene speriment,' 1902 e 1903.

Celli.—'Ann. d'Igiene speriment,' vol. vi, 1896; also 'von. Leiden-Festschr.,' Bd. i, 1900.

Celli and Fiocca.—'Ann. d'Igiene speriment,' 1895.

Celli and Valenti.—'Centr. f. Bakt.,' Bd. xxv, 1899.

Chantemesse and Widal.—'Bull. de l'Acad. de Med.,' 1888; also 'Presse Medicale,' 1902, No. 59.

Conradi.—'Deutsch. med. Wochsch.,' 1903, No. 2, p. 26.

Dombrowski.—'Arch. f. Hyg.,' Bd. xlvii, 1903, Hft. 3, p. 256.

Drigalski.—'Veröffentl. a. d. Geb. d. Militärsanitätswesens,' 1902, Hft. 20, p. 106.

Duval and Bassett.—'Centr. f. Bakt.,' 1903, vol. xxxiii, p. 52.

Duval and Vedder.—'Journ. Exp. Med.,' 1902, vol. xi, p. 181.

Escherich.—'Centr. f. Bakt.,' 1899, Bd. xxvi, p. 385.

Flexner.—'Bull. Johns Hopkins Hosp.,' 1900, vol. xi, pp. 39 and 231; also 'Centr. f. Bakt.,' 1900, Bd. xxviii, p. 625; also 1901, Bd. xxx, p. 449; also 'Philadelphia Med. Journ.,' 1900, p. 414; also 'Univ. Pensyl. Med. Bull.,' 1901, vol. xiv, p. 190.

Gay.—'Univ. Pensyl. Med. Bull.,' 1903, vol. xvi, Nos. 5 and 6; also 'Medical Record,' March 26th, 1904.

Hiss and Russell.—'Med. News,' 1903, February 14th, p. 289.

Houston.—'Centr. f. Bakt.,' 1898, No. 14; also 'Suppl. 28th Rep. Local Gov. Board,' 1898–9.

Jürgens.—'Deutsch. med. Wochsch.,' 1903, No. 46.

Kruse.—'Deutsch. med. Wochsch.,' 1900, Bd. xxvi, p. 637; also 1901, Bd. xxvii, pp. 370 and 386; also 1903, Bd. xxix, Hft. 1–3.

Kruse and Pasquale.—'Zeitsch. f. Hyg.,' 1894.

Lentz.—'Zeitsch. f. Hyg.,' 1902, vol. xli, Hft. 3, pp. 540 and 559.

Müller.—'Centr. f. Bakt.,' 1902, Bd. xxxi, p. 558.

Neisser and Shiga.—'Deutsch. med. Wochsch.,' 1903, No. 4, p. 61.

Park.—'Proc. N. Y. Path. Soc.,' 1903, p. 182.

Park and Carey.—'Journ. Med. Research,' 1903, vol. ix, p. 180.

Posselt and Sagasser.—'Wein. klin. Wochsch.,' 1903, No. 24, p. 691.

Rogers.—'Journ. Trop. Med.,' February, 1903.

Rosenthal.—'Deutsch. med. Wochsch.,' No. 19, May 5th, 1900, p. 691; ibid., No. 6, 1903, p. 97; also ibid., No. 7, February 11th, 1904, p. 235.

Schmiedicke.—'Veröffentl. a. d. Geb. d. Militärwesens.,' 1902, Hft. 20, p. 78.

Shiga.—'Centr. f. Bakt.,' 1898, Bd. xxiii, p. 599; also 1899, Bd. xxiv, pp. 817, 870, and 913; also 'Zeitsch. f. Hyg.,' 1902, Bd. xli, Hft. 2, p. 353; also 'Deutsch. med. Wochsch.,' 1901.
Strong.—'Report Surgeon-General U.S. Army,' Washington, 1900.
Sukehito.—'Centr. f. Bakt. Originale,' Bd. xxxiv, Nos. 6 and 7.
Todd.—'Brit. Med. Journ.,' December 5th, 1903, p. 1456.
Vaillard.—'Ann. de l'Instit. Pasteur,' 1903, vol. xvii, p. 463.
Vedder and Duval.—'Journ. Exp. Med.,' 1902, vol. vi, p. 181.
Wollstein.—'Journ. Med. Research,' 1903, vol. x, No. 1.
Zancarol.—'Dysenterie tropicale.' Paris, 1895.

31. *On arterial sclerosis, especially in regard to arterial hypermyotrophy and the other morbid changes which occur in the muscular tunic of the arteries.*

By Thomas D. Savill.

[Read at the opening of a discussion on arterial sclerosis at the Pathological Society of London on February 16th, 1904.]

Definitions.

These investigations were initiated at the Paddington Infirmary, where, during the seven years I was medical superintendent, nearly 500 autopsies were made on persons of 60 years of age and upwards, many of whom presented circulatory symptoms during life, and some of them died of the semi-invalidism we call old age. It was to discover the cause of death in these latter cases that the investigations were directed. The inquiry has been continued during the last ten years whenever my leisure and eyesight would permit. The opportunity has thus been afforded me to examine, not only the visceral arterioles, but to pay more attention than is usually devoted to arteries of all sizes and in all positions throughout the body. I was accustomed to define arterial sclerosis in my own mind as a chronic generalised thickening, condensation, or degeneration of the arterial walls, in which, after death, the lumen does not collapse as usual, and the walls are harder and less elastic than normal. Histologically such a condition may occur in three situations: in the tunica media, when it may be properly termed medial sclerosis; in the tunica intima, when it might be called intimal sclerosis; or in the tunica adventitia, when it might be termed adventitial sclerosis. Such a division

of chronic arterial disease is more scientific and more in keeping with the division of chronic diseases of the heart into myocardial, endocardial and pericardial respectively, each being clinically and pathologically separable from the other, and each being of very different relative importance.

In regard to atheroma (a patchy fibroplastic infiltration of the intima), those who make many autopsies on the bodies of the aged can, I think, have very little doubt that atheroma and intimal sclerosis (the generalised thickening just referred to) are two totally distinct pathological conditions (Table 1), as Dr. William Russell[1] and others have already pointed out.

TABLE I.—*Distinction between*

Atheroma.	*Intimal sclerosis.*
Patchy, localised fibro-plastic infiltration of intima prone to undergo necrotic changes.	Fibrous thickening of the entire intima, with little, if any, tendency to necrosis.
Raised *yellow* spots or patches located on one side of an artery. These can be felt as beaded thickenings during life when the superficial arteries are affected.	Not a raised patch, but a more or less uniform thickening all round the lumen of an artery without alteration of colour. Affects a considerable length of a vessel which may give to it a smooth, hard feel like whipcord. Not a beaded thickening.
Affecting chiefly the aorta and the *larger* arteries of the trunk and brain. May be of very limited extent. Very often met with at a bifurcation of vessels even in quite healthy subjects.	May affect arteries of any size, but relatively more common in the medium and smaller vessels; usually affecting a considerable vascular area, and often found in association with arterial dilatation.

Atheroma is apt to be confused histologically with the obliterative endarteritis of syphilitic or other origin which occurs for the most part in younger subjects, but it ought not to be with intimal sclerosis. Some atheroma can always be found in the bodies of persons aged 60 and upwards who may have died without any circulatory symptoms or accidents of any kind, as in the case aged 100 to which I shall refer directly, and the conclusion has been forced upon me that atheroma is of no serious pathological importance provided the cardio-vascular system is otherwise fairly healthy. The evil results sometimes attributed to atheroma, in the brain for instance, can very often be accounted for by the yielding of the vessel wall *between* the patches, and the kinking of the artery which ensues.

[1] 'The Lancet,' June 1st, 1901, p. 1519.

In regard to adventitial and intimal sclerosis, I have met with many cases in which it could be legitimately inferred that chronic adventitial and intimal sclerosis of the larger and medium-sized arteries had been secondary, both in time and importance, to changes in the media, or to dilatation of the arterial lumen, as Thoma first pointed out. A distinction should, I think, be drawn between intimal sclerosis in the peripheral (microscopic) arterioles on the one hand, and intimal sclerosis in the medium-sized and larger arteries on the other. Their causes also appear to be distinct, and certainly their effects are, for the former may obstruct large areas of the peripheral circulation, but the latter is mainly supporting, compensatory and protective; each should therefore be studied from a separate standpoint. In relation to this subject I would dissent to the inference sometimes drawn that because intimal sclerosis exists in the arterioles of the kidney it also exists in the other peripheral arterioles. This is by no means so in my experience, and the kidney constitutes only a small portion of the whole peripheral circulation. The voluntary muscular system constitutes a very large part, and it does not appear right that too much attention should be concentrated on the visceral arterioles, nor on the microscopic arteries at the expense of those of larger size.

In this paper I propose to direct my attention chiefly to the morbid changes in the muscular tunic of the arteries, and to deal first with the relative importance of the muscular coat, secondly, with the morbid changes met with in the muscular tunic, and thirdly with the pathological condition which I have previously described as "Arterial Hypermyotrophy." The data on which these investigations have been based consist of cases under my care during life (often for several years) and examined after death at the Paddington Infirmary. Clinical and pathological details will be submitted in 29 of these (out of 257 autopsies in nineteen months) which presented definite circulatory symptoms or accidents during life without valvular disease, or any sufficient explanation other than their arterial condition.

I. *The relative importance of the muscular coat.*

At the outset it will be well to refer to the importance of the muscular tunic of the arteries relatively to the other two, on

histological, physiological, and pathological grounds. The muscular tissue forms the principal tunic of all the arteries and arterioles of the body, only excepting arteries of quite the largest size, in which very little muscular coat is found. In the arteries and arterioles it forms about half the thickness of the vessel wall, and constitutes the functionally active part of the entire arterial system. The intima is only a limiting membrane, the adventitia is only a supporting structure of connective tissue; but the media, by the exercise of its functions, controls the circulation as a whole, as well as the quantity of blood in this or that area or organ. These muscular fibres form, in short, the parenchyma or proper tissue of the arterial system. But whereas imperfections in the parenchyma of other physiological systems only affect the functions of that particular organ, any imperfection of the muscular coat of the arteries affects, directly or indirectly, the nutrition and oxygenation of all the organs and tissues of the body, and disturbs, not only the equilibrium between the different systems, but also that important equilibrium between the heart and arteries on which the perfect health and life of every individual depend.

We also know, thanks to the observations of Dr. Geo. Oliver and others,[1] that the regulator functions of the arteries are of vital importance, not only to the vascular area they supply, but to *that wonderful power of adaptability to the different positions of the body* which is indispensable to the dynamic equilibrium of the circulation; and, therefore, it is not surprising to find that postural vertigo is among the most prominent symptoms when the muscular coat loses its elasticity, contractility, or regulator powers. The older authors regarded old age as a loss of balance of functions, and this was probably true in regard to the equilibrium between heart and arteries. But the most important characteristic of incipient old age in my view is the loss of the regulator function of the arteries.

Turning to the pathological aspect, we know that extensive valvular disease of the heart or of the endocardium may exist without inconvenience, so long as the muscular wall is healthy; and we also know that fat may be deposited outside the heart,

[1] Dr. George Oliver, "On Pulse Gauging," London, 1895, p. 22 *et seq.* Dr. Leonard Hill, "The Physiology and Pathology of the Cerebral Circulation," London, 1896.

and fibrosis, amounting even to obliteration, of the pericardial cavity (as I have often seen in the *post-mortem* room) may exist without very seriously affecting its action, as long as the muscular tissue is healthy. Similarly, in my experience, widespread atheroma or intimal sclerosis on the one hand, or a marked adventitial sclerosis or peri-arterial fibrosis on the other, has existed in many cases without manifesting any clinical or patho-

FIG. 68.

Showing atheromatous erosion in the aorta of M. W—, a woman aged 100 who had very extensive atheroma elsewhere. × 45.

logical consequences provided the tunica media be fairly healthy.

As one among many illustrations of these statements the following case may be mentioned, that of a woman, M. W—, who died in the Paddington Infirmary at the age of 100 in October, 1890. Her mental and bodily powers became very gradually weaker, and she passed away with no definite evidences of active disease either before or after death, excepting the hypostatic congestion of the lungs and a certain degree of pulmonary fibrosis so

commonly present in the bodies of aged persons, accompanied by a few spots of incipient broncho-pneumonia latent during life. She was under observation for many months, and during life there was no history or evidence of any derangement of the

FIG. 69.

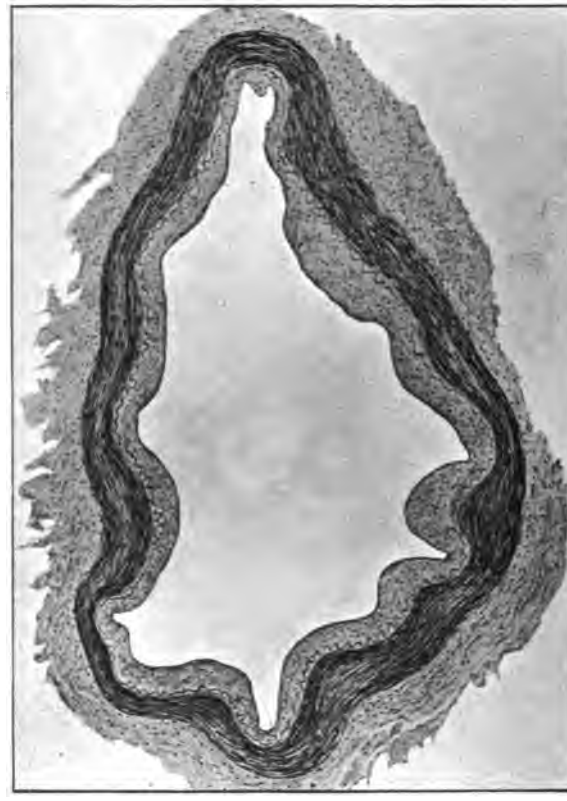

Radial artery (stained with logwood × 40) of a woman, M. W——, aged 100, showing, as in all the other arteries of this case, a perfectly healthy tunica media; the artery is dilated and the media *proportionately* thinned. The artery also shows intimal and adventitial sclerosis, which, in this case, the author regards as compensatory to the dilatation. This case also exhibited extremely widespread atheroma, but no circulatory complications at any time.

circulatory system. After death the naked-eye and microscopical examination (upwards of fifty sections of the arteries and organs were examined) revealed (1) widespread atheroma of the systemic and cerebral arteries reaching a degree that I have rarely seen. It was found not only in the larger vessels,

where it is usual, if not invariable, in persons over sixty, but also in the medium-sized and smaller vessels throughout the body, and even in the ultimate ramifications of those of the brain. In the arch of the aorta one or two atheromatous patches were breaking down into what are sometimes called atheromatous ulcers, but there had been no embolism, thrombosis, or vascular rupture of vessels in any part of the body or brain. (2) The lumen of all the arteries in the body was increased to one and a half, and in some of the larger arteries (*e.g.* the common iliac) to two and a half normal. (3) The heart was small, not hypertrophied or dilated, and microscopically, excepting for moderate peri-arterial fibrosis and the usual brown atrophy of old age, it was normal. (4) Besides the patchy atheroma, there was in this case generalised *intimal* sclerosis (diffuse thickening of the intima), and (5) generalised condensation and thickening in the *adventitia* (adventitial sclerosis), changes which may here be regarded as secondary to and compensatory of the arterial dilatation. (6) The muscular tunic of the arteries presented but little change, especially when we consider her age (Figs. 69 and 79). Some degree of granular changes existed in the lower extremities, but not more than I have met with in many persons of half her age. The thickness of the media was diminished, but careful measurements showed it to be strictly in proportion to the arterial dilatation which existed. Specimens of the organs and the cardio-vascular system were exhibited at the meeting of the Pathological Society.

It is surprising what grave disease of the intima may exist without at any rate local consequences. Here, for instance, is the anterior tibial artery (Figs. 70 and 71) of a woman (Case 67) who died at the age of eighty-one of an intercurrent malady (epidemic skin disease). The lumen of the vessel was narrowed by an atheromatous patch undergoing necrosis to only one tenth of the normal, yet no circulatory effects or accidents occurred in the limb. Incidentally, these two pictures reveal the value of acid orcein for delineating the boundaries of the tunica media.

These cases are only two of many that could be quoted as an illustration in support of the contentions (1) that extensive patchy atheroma, and even generalised intimal and adventitial sclerosis, are quite consistent with extreme longevity, and with

the total absence of circulatory symptoms, accidents, or complications, provided (firstly) the tunica media be relatively free from hypertrophy or disease, and (secondly) the balance between the heart and arteries is not disturbed.

On the other hand, moderate generalised disease of the

FIG. 70.

Anterior tibial of a woman, Harriet T——, aged 81, showing atheroma undergoing necrosis. Logwood staining × 45. [Case 67.]

muscular tunic is a serious potential evil. Starting, as it generally does, in my view, in hypermyotrophy, a slight and hardly measurable increase in the muscular tunic, even without the degeneration which ensues, must have a very considerable influence on the dynamics of the circulation and on the nutrition of the body generally.

II. *Morbid changes met with in the muscular tunic.*

Muscular tissue occurs in all but the very largest arteries, chiefly in the medium-sized and smaller arteries. The changes I have met with in the tunica media (apart from lardaceous

FIG. 71.

Same case and section as preceding (× 45). Stained by acid orcein for comparison, showing how well this reagent brings out the boundaries of the tunica media. [Case 67.]

disease, which hardly comes within the scope of arterial sclerosis) are atrophy, hypertrophy, cloudiness, granular degeneration (which are always more or less generalised in the arterial system), necrosis and calcification (which are mostly localised and limited). The methods of revealing these are given in the appendix. (1) True *atrophy* of the tunica media—that is to say,

apart from the thinning due to dilatation of the calibre of the arteries—I have only met with as an accidental condition. A slight degree of arterial amyotrophy was sometimes found after death from prolonged wasting disorders. Thus, atrophy was met with in three emaciated cases dying of chronic pulmonary

FIG. 72.

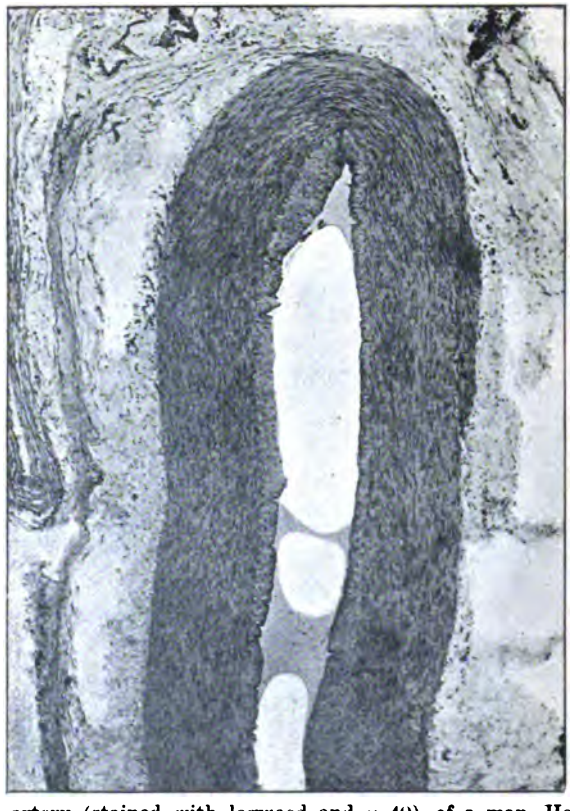

Radial artery (stained with logwood and × 40) of a man, Henry G—, aged 30, killed by an accident, showing simple hypermyotrophy; intima and adventitia normal. He had suffered from headaches, but no other symptoms. [Case 41.]

tuberculosis out of four examined, in two cases of chronic pyelitis, and in one of scirrhus of the pylorus. The atrophy or thinning of the media appeared in all of these instances to be due to a wasting of the protoplasm of the muscular fibres, as judged by the undue approximation of the neighbouring nuclei. (2) *Hypermyotrophy, i.e.* an increase in the number or volume

of the muscular fibres of the arteries, resulting in an increased width of the media, with or without some of the other changes about to be mentioned, was of very frequent occurrence. The almost universal occurrence of a slight degree of hypertrophy in the bodies of persons past middle life led me at one time to infer that some degree of hypertrophy of the media might be usual in advancing years, just as hypertrophy of the heart has been shown to occur in the aged.[1] But the measurements are too refined and the conditions for which allowances have to be made, such as the size of the lumen of a vessel, are too numerous, for anyone to be able to dogmatise on a general proposition of this character, and I gladly admit the corrections of Professor Clifford Allbutt's[2] valuable criticisms on this point. Hypermyotrophy is probably the first stage to all the morbid changes about to be mentioned, certainly 3, 4, and 5, and probably 6. At any rate, in all the cases I have examined I have never met with nebular or granular degeneration and necrosis without some degree of the former, though hypermyotrophy was sometimes met without the latter. Hypermyotrophy and its other consequences will be referred to more particularly later on. (3) *Cloudy* or *nebular degeneration* of the muscular fibres (Fig. 78 and part of 73) consists of a faint cloudy condition of the protoplasm, mostly accompanied by enlargement of the fibres. With logwood and other ordinary stains slighter degrees of this cloudiness are not revealed, but with neutral orcein (see Appendix), 96 c.c., the faintest degree becomes manifest. When treated in this way, the tunica media of the lower limbs of nearly all persons examined past middle life showed some slight cloudy changes. Cloudiness in the protoplasm apparently commences in the innermost layers of the tunica media, for it was always most marked in this situation. (4) *Granular degeneration*, like the preceding, predominated in the inner layers of the tunica media. It occurred mixed with cloudy changes in many transitional forms, and is probably an advanced stage of the latter. The tunica media in granular degeneration is brittle and more difficult to mount, the muscular fibres lose their outline, their protoplasm breaks up into granules, and later on the muscle nuclei also break up. This granular condition seems to me to correspond

[1] Boyle, 'Proceedings of the Royal Society,' 1861.

[2] The 'Lancet,' May 1st, 1897.

in some respects (its usual areas of distribution in the arterial system, for instance) with the "diffuse arterio-sclerosis" described by Thoma.[1]

Dilatation of an artery, local or general, may result from

FIG. 73.



Radial artery of Addison, a man aged 76, magnified about 300, showing granular degeneration of inner layers of media. [Case 69.]

either of the two preceding, and with it there may be an *apparent* thinning of the media. Both the adventitia and intima of such dilated arteries were, in my experience, as in the case of the woman aged 100 years, almost invariably denser or thicker

[1] Various papers scattered through Virchow's 'Archives,' 1883-1889.

than normal, and this adventitial and intimal sclerosis should, I think, be regarded as compensatory and conservative conditions. Probably dilatation itself is in a sense a conservative process in cases of persistent high tension. (5) *Necrosis* of the media consists of local spots or foci of amorphous *débris*, which take a very dark stain with aniline or logwood. The adjacent parts of

FIG. 74.

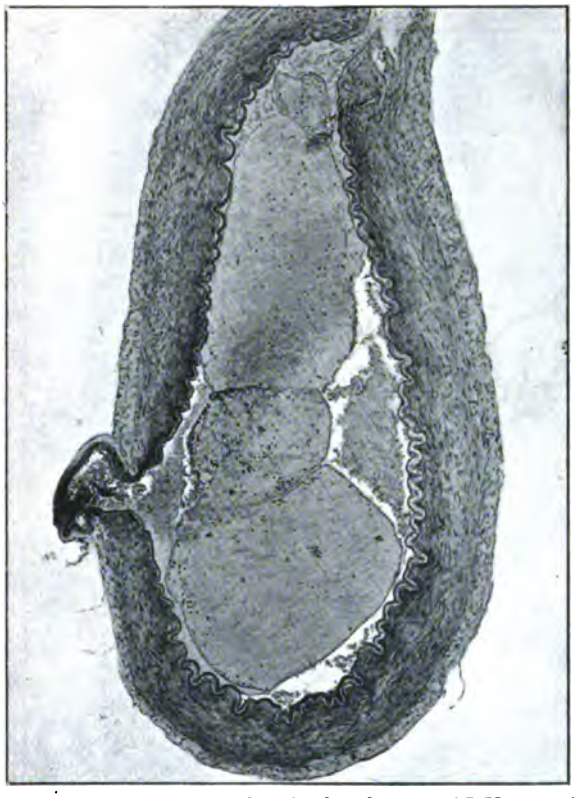

Middle cerebral artery (logwood-stained and × 40) of J. H—, aged 56; case described in text. There was, as usual in the cerebral arteries in cases of arterial hypermyotrophy, only very slight hypertrophy of the media. But a minute focus of necrosis in the media has resulted in bulging, such as would give rise, when combined with high tension, to the hæmorrhage from which he died. [Case 42.]

the vessel may be quite healthy in some cases (*e.g.* Case 42) and it is then very easily overlooked, while in other cases the media is the seat of cloudy granular changes. (6) *Calcification* of the media was not so common as the preceding changes. It was met with in the later stages of arterial disease in two

forms. Sometimes it was seen in the form of plates which had apparently succeeded the necrotic changes just referred to. These plates must not be confused with the more common atheromatous plates in the intima (particularly of the bigger vessels) which may encroach on, but do not originate within, the media, a fact which can be revealed by the use of acid

FIG. 75.

Another section from the radial artery (stained logwood × 40) of J. H—, aged 56, showing focal necrosis. Insufficiently stained on one side. [Case 42.]

orcein to define the boundaries of the tunics. A second variety of calcification which is still more rare takes the form of spicules surrounding the lumen of an artery, and appears to be due to a transformation into calcareous material of swollen muscular fibres or bundles of fibres. These spicules were apt to be more generalised than the plates, and might (as in a man named

Richard M—, aged 66 years) render entire lengths of various arteries as rigid as water-pipes. Both necrosis and calcification are fairly common in the popliteal artery, even when the rest of the arterial system is practically healthy. *Fibrosis, i. e.* a replacement or transformation of the tunica media into fibrous tissue, I have never seen. Unstained, insufficiently stained, or badly prepared specimens (*e.g.* by their remaining too long in Müller's or other preservatives) may present a very striking resemblance to fibrous tissue, both naked-eye and microscopically. But adequate preparation and staining has always brought out the characteristic rod-shaped nuclei of involuntary muscular tissue within the internal and external boundaries (as defined by acid orcein) of the tunica media. The media may, of course, be encroached on and apparently dilated and thinned by a dense fibrous intima, as in the arterioles of some cases of chronic interstitial nephritis.

It is not possible to give statistics as to the relative frequency of these several changes, because they were so commonly associated in varying degrees in the same patient. Hypertrophy, cloudy changes, and granular degeneration of the media are undoubtedly generalised changes such as would arise from nutritional, dynamic (*e.g.* high tension), or toxæmic causes. They were always generalised in their distribution, though apt to predominate in some vascular area, very often in the arteries of the lower extremities—a penalty, perhaps, for man's erect posture. But focal necrosis and plates of calcification were local and limited in their occurrence, and might be met with in any, often in the most unexpected, parts of the arterial system. They resembled the results of injury (as in the popliteal, where they are so common), or the blocking of a capillary area of the vasa vasorum. The effects of these two sets of changes are also somewhat different. The consequences of arterial hypermyotrophy, and of cloudy and granular degeneration (the generalised changes), were primarily to disturb the dynamics of circulation and nutrition (*i.e.* the elasticity and contractibility of the vessels and the cardio-vascular balance). The effects of the necrosis, on the other hand, were local, and led to rupture and hæmorrhage. Necrosis of the media, which was very frequently associated with arterial hypermyotrophy, if unaccompanied by compensatory adventitial or intimal thickening, appeared to be

one of the most insidious and lethal of medial degenerations (see Figs. 74 and 75). It might be present in one or two tiny spots in a tunica media which, excepting for hypertrophy, might be absolutely normal elsewhere. Consequently these spots are very difficult to find, but my belief is that they exist (in association with arterial hypermyotrophy) in a large proportion of cases of cerebral hæmorrhage. Such an association was found in at least four of the six cases of cerebral hæmorrhage among the thirty cases submitted. It may have been overlooked in the other two in spite of the most careful search.

III. *Arterial hypermyotrophy.*

Arterial hypermyotrophy was a term I first used in 1891 [1] and again in 1897 [2] to describe an increased thickness of the muscular tunic of the arteries due to an increased volume, with or without numerical increase, of the individual muscular fibres. A numerical increase is very difficult to determine. The question whether the increased volume or swelling of the individual muscular fibres is to be called a hypertrophy is an important one. I still regard the condition as primarily a genuine muscular hypertrophy, just as an increased thickness of the cardiac wall, in which some or all of the muscular fibres are swollen, is also so regarded. My subsequent researches with acid orcein have, however, revealed a certain cloudiness of the protoplasm of the muscle in some cases in which other stains did not reveal it. This nebular condition, as I have just mentioned, is probably the earliest stage of degeneration. But the fact of degeneration having commenced by the time a case reaches the *post-mortem* room does not negative the existence of hypertrophy. In point of fact, arterial hypermyotrophy must be regarded—a fact to which Dr. William Russell [3] has also drawn attention—as being the first step to all medial degenerations, the earliest phase of medial sclerosis, the first change when a strain is thrown on the arteries; hence the importance of its recognition. Careful

[1] Annual Meeting of the British Medical Association, 1891 (Pathological Section).

[2] 'Medical Society's Transactions,' vol. xx, p. 271; and 'British Medical Journal,' 1897 (January 23rd), vol. i, p. 188.

[3] Dr. William Russell, 'The Lancet,' June 1st, 1901, p. 520.

histological methods will always reveal traces of it in all cases of medial degeneration.

Arterial hypermyotrophy, as thus histologically defined, constitutes, in my experience, a distinct clinical and pathological condition of prolonged course, capable of recognition during life by careful investigation,[1] characterised in the first stage mainly by "postural" vertigo and other symptoms of high blood pressure, in the second stage mainly by the evident thickness of the arteries, cardiac hypertrophy, and sometimes by cerebral or other hæmorrhage, and in the final stages by the various circulatory and nutritional disturbances which may ensue, sometimes but not necessarily associated with chronic renal disease, which is only one amongst many of its causes, and constituting in itself one of the main pathological conditions on which cerebral and other hæmorrhages depend, and on which the incipient phenomena of senile decay also depend.

During the nineteen months June 1st, 1890, to December 31st, 1891, there were 257 autopsies made at the Paddington Infirmary. Twenty-eight of these 257 cases were patients who had presented circulatory symptoms or accidents during life, but who had no cardiac valvular disease. It was the combination of these two circumstances which induced me to investigate the arterial system. The muscular tunic of every one of these cases was increased in thickness; in many it was associated with other morbid changes in the media, and in some cases with abnormalities in the other arterial tunics. Two similar cases (Nos. 41, a case of accidental death, and 42, an interesting case of arterial hypermyotrophy, who died in the Paddington Infirmary in the spring of 1892) are added to this list, making 30 in all. Clinical and pathological details of these cases are given in the appendix to this paper, and the methods adopted in the examination are also given. Measurements were made of the muscular and other arterial coats by means of an eyepiece micrometer, any alteration of the lumen being allowed for. Upwards of 1500 microscopic specimens of arteries were examined, measured, and compared with normal specimens, an average of 50 sections to each case, taken from arteries of various sizes of the limbs, abdomen, thorax, and head, as well as the arterioles of the viscera.

[1] 'British Medical Journal,' *loc. cit.*

These 30 cases have been arranged in two groups.

Group A comprises 17 cases in which the arterial hypermyotrophy was *relatively* uncomplicated by other arterial disease and by less advanced degeneration of the tunica media. Group B comprises 13 cases, in which the arterial hypermyotrophy was complicated more or less with advanced degeneration, dilatation, or other arterial disease, viz., intimal or adventitial sclerosis or atheroma. These cases represented the later or final stages.

The difficulties of an inquiry such as this were considerable. (1) The universal distribution of the arterial system makes these examinations most tedious and prolonged, and the extensive dissections required often prevent one getting permission from friends. (2) Two or three sections of an organ will give you a general idea of its morbid changes, but this is not so in the arterial system, where 50 sections sometimes seem inadequate. (3) The minuteness of the measurements render the greatest care and precision necessary. (4) The state of contraction or dilatation of an artery is only one of the many conditions for which allowance has to be made in measuring the muscular tunic. If an artery is in a state of contraction, the media is of course thickened, whether there be hypermyotrophy or not, and the intima is thrown into folds; if it is dilated, the media is of course thinned and the intima stretched. No medial measurements therefore are of much value unless the calibre of an artery as compared with a normal specimen is measured and recorded. (5) Considerable difficulty is very often experienced (Figs. 70 and 71), especially in degenerate arteries, in distinguishing the boundaries of the middle coat, and after trying auric chloride, nitrate of silver, and many other stains, I found in acid orcein an ideal stain which brought into marked prominence the elastic layer of Henle and the increased quantity of elastic tissue which is found in the inner layers of the adventitia (Fig. 71). (6) But perhaps the greatest difficulty of all consisted in securing a normal standard from which measurements and comparisons could be made. In my search for a normal standard I found, as already mentioned, that there was certainly a minute variation in the thickness of the tunica media in various diseased conditions. After examining several bodies in which death occurred from acute or chronic disease, at last I wrote to some of the

Metropolitan coroners, who very kindly afforded me opportunities of examining persons who had died of accident in the midst of apparent health.

As examples of arterial hypermyotrophy I will refer to three cases which represent the three stages of the disorder: (1) simple hypermyotrophy, (2) hypermyotrophy with incipient degeneration, and (3) hypermyotrophy with degeneration, dilatation, and compensatory intimal and adventitial sclerosis.

1. In the course of my search for a normal standard, I had, by the courtesy of Dr. Danford Thomas, the opportunity of examining the body of a man named Henry G—, aged 30, a carpenter, who was riding his bicycle across Oxford Circus when he came into violent collision with the shaft of a four-wheeled cab, which drove his ribs into his liver, and he died in twelve hours. His radial artery is shown in Fig. 72. The case may be regarded as being one of arterial hypermyotrophy in its early phase, when the media is free from degeneration of any kind. The average of fifty specimens of arteries and organs examined in this case showed an increased thickness in the muscular tunic of the arteries of $\frac{3{\cdot}3}{2{\cdot}5}$. The heart was slightly hypertrophied and weighed 11½ ounces, and the muscular tissue was quite healthy. All the other organs were normal. After some difficulty I traced his wife, who informed me that he had always seemed quite healthy, but complained a good deal of headaches. I am glad to have been able to exhibit this case because arterial hypermyotrophy is not very often met with in the *post-mortem* room in such an early and unmixed condition. There was, as far as I could tell with the means at my disposal, a numerical increase in the muscular fibres, but this young man's arteries also revealed an increased thickness of the individual fibres. I have sometimes been asked if such thickening does not indicate degeneration rather than hypertrophy. Now, the individual fibres of all contracted arteries are thickened, and I have repeatedly seen the same thickening with or without contraction in normal arteries taken from young and perfectly healthy subjects; there is a remarkable variation in this respect within the range of health. True degeneration is revealed by cloudy, granular, or other definite change in texture.

2. The following case (Case 42 in the appendix) may be

regarded as a fair example of arterial hypermyotrophy terminating at a relatively early phase of the disorder in cerebral apoplexy. Joseph H—, aged 56, a road sweeper in the employ of the Vestry, was admitted into the Paddington Infirmary on April 14th, 1892, for left hemiplegia, which had come on suddenly while he was at work the day before, without loss of consciousness. The precordial dulness extended to the nipple line, and indicated hypertrophy. The apex beat was forcible. The pulse was full, the arterial tension high, and it was noted by one of my colleagues that "the artery feels like whipcord." The abdominal organs were natural. There was incontinence of urine, but some was collected and it was noted as copious, clear, pale, acid, 1020, no albumen or sugar. We were informed that his mother had incurred a stroke of paralysis down one side, followed by death two years later, and that one sister was in an asylum. His brother George, aged fifty-eight, had been in the infirmary for "bronchitis," and there was a note in our records that he had "whipcord-like arteries," and complained of "giddiness when he stooped." The patient's previous history revealed that he had taken both beer and spirits in fairly liberal quantities, but not to what was regarded as excess. He had suffered from "bronchitis" from time to time. For the past two years he had been troubled with swimmings and giddiness in the head, especially after stooping, had complained of a good deal of headache, occasional breathlessness and depression of spirits. The next evening, April 15th, he became comatose, and died at 3 the following morning without fresh symptoms.

At the autopsy nothing of importance was found, excepting in the vascular system. The kidneys weighed, right 4 ounces, left 4½ ounces, and were microscopically quite normal, excepting that the arterioles stood out and remained patent. Microscopically the media of the arterioles was a trifle thickened, but the parenchyma of the organs was perfectly normal. The heart weighed 13 ounces, and its walls were notably hypertrophied and slightly dilated. The muscular tissue appeared normal to the naked eye, and under the microscope. The valves were perfectly healthy.

A naked-eye examination of the arteries showed that the radials and all the other arteries of similar and smaller size were slightly contracted, with the single exception of the dorsalis

pedis on both sides, which was dilated, and that the muscular coat of *all the arteries* was notably thickened even after allowing for the slight diminution of calibre. The brachials, radials, and femorals were tortuous, showing an increase of the media in length as well as in thickness. Microscopically sections of over fifty different arteries were examined and measured, the average measurements being—

Calibre $\frac{18}{20}$, media $\frac{4{\cdot}5}{2{\cdot}5}$, adventitia $\frac{2}{2}$, intima $\frac{1}{1}$. (The lower figures represent the normal standard.)

The increase in the muscular tissue was most marked in the lower extremities, average $\frac{5{\cdot}7}{2{\cdot}5}$, that of the upper extremities and abdomen $\frac{4{\cdot}1}{2{\cdot}5}$, splenic artery $\frac{4{\cdot}0}{3{\cdot}0}$.

In the radial the thickening of the media was very marked, the measurements being $\frac{20}{20}, \frac{5{\cdot}5}{2{\cdot}5}, \frac{2}{2}, \frac{1}{1}$.

The muscular tissue of the arteries appeared normal and free from degeneration, excepting a moderate degree of cloudy swelling in the inner layers of the media in the arteries of the lower extremities.

In the arterioles of the viscera the muscular tissue was increased, but less than in the arteries of the limbs and abdomen. A slight amount of intimal thickening could be observed in the arteries of the lower extremities. Elsewhere the tunica intima was normal. The adventitia was not notably increased or condensed anywhere (excepting, perhaps, in the radial and dorsalis pedis arteries).

The cerebral vessels appeared to be remarkably healthy both to the naked eye and microscopically. There was no atheroma, and no thickening in any of the coats to be detected. The media was perhaps slightly increased, but the increase was hardly measurable. Nevertheless, in the centre of the brain, which was otherwise quite healthy, there was a recent blood-clot, about the size of a hen's egg, occupying the right internal capsule.

These were the results of going twice over the specimens of more than fifty arteries, and it seemed difficult to account for the cerebral hæmorrhage. When all the arteries are simply too

thick, why should they rupture? The most obvious explanation was that the marked hypermyotrophy of the systemic arteries and the heart threw an extra strain on the relatively unhypertrophied arteries of the brain, and I think this explanation is sufficient, or partly sufficient, to account for most cases of apo-

FIG. 76.

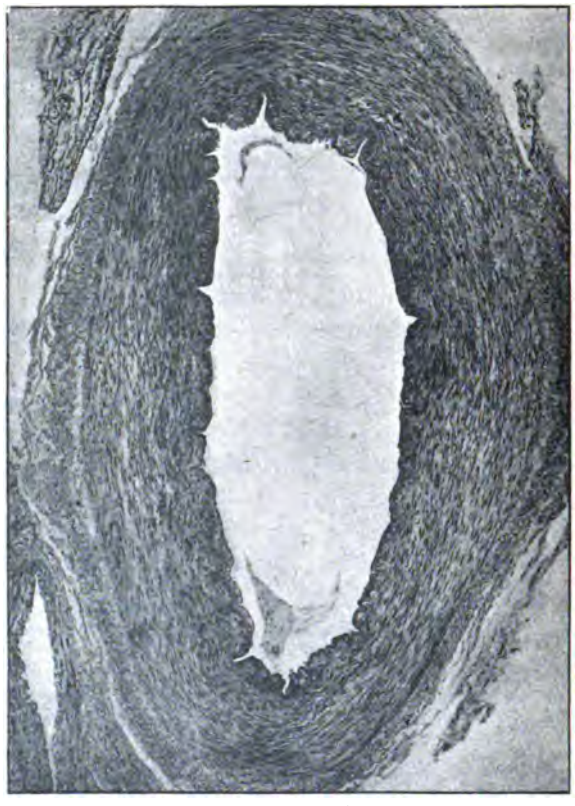

Radial artery (stained with logwood and × 40) from a man named J. H—, aged 56, who died of cerebral hæmorrhage. This, like all his other arteries, shows marked arterial hypermyotrophy. The measurements are given in the text. [Case 42.]

plexy. But on further search of additional sections I came across a minute (microscopic) necrotic focus in the tunica media, surrounded on all sides by healthy muscular tissue, in four situations; one in a section of the radial (Fig. 75), one in an arteriole in the kidney, one in the basilar artery, and one in the middle cerebral artery (Fig. 74), which was bulging. I

think it is safe to infer that this man's cerebral hæmorrhage came through such a bulging. But one meets with many other cases of medial necrosis without cerebral hæmorrhage; therefore the cardio-arterial hypermyotrophy and its consequent high tension must, I think, still be regarded as the main cause of the

FIG. 77.

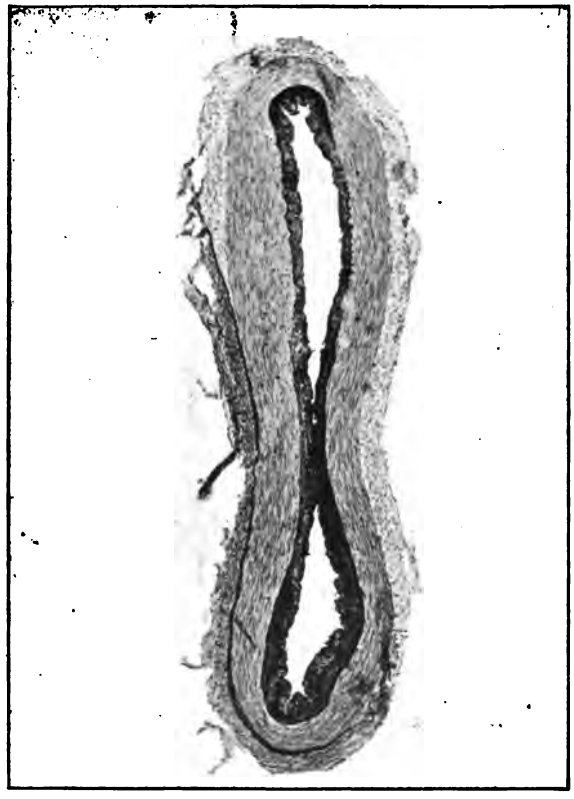

Normal radial artery for comparison with preceding (stained with logwood and with weak nitrate of silver solution to bring out the boundaries of the middle coat. × 40).

cerebral hæmorrhage in this case. It was in many ways a most instructive one, uncomplicated as it was with any renal disease, and unmixed to any extent with intimal or adventitial sclerosis, or with that extensive degeneration of the media which so often supervenes (*e.g.* Cases 58 to 70) before the patient reaches the *post-mortem* room.

3. The third case, taken from among many similar ones, illus-

trates the final stage of arterial hypermyotrophy when degeneration, dilatation, intimal and adventitial sclerosis had supervened. William B—, aged 73 years (Case No. 56), had been many years in the workhouse, and was four and a half years under observation in the Paddington Infirmary. Since the age of 59 he had been subject to vertigo, especially on any change of posture, *which was at first relieved by nitro-glycerin.* At the age of 71 the vertiginous attacks were replaced by attacks of syncope, sometimes even while he lay in bed. He died suddenly in one of these syncopal attacks at the age of 73. The kidneys (total weight 9½ ounces) and other organs were healthy, and the urine

FIG. 78.



Brachial artery of W. B—, aged 73, showing arterial hypermyotrophy and commencing granular degeneration. × 45. [Case 56.]

FIG. 79.



Brachial artery of M. W—, aged 100, showing normal media for comparison with preceding figure. × 45 Case described in text on p. 379.

was always normal. The heart was hypertrophied, the weight being 19 ounces. The brachial artery, compared with that of the patient aged 100 years whom I have already alluded to, depicts the muscular increase. The calibre of these two arteries was the same and therefore their tunics are strictly comparable. W. B—'s hypermyotrophy was widespread, more marked in the lower, less marked in the upper half of the body, least marked in the brain. Some degree of granular degeneration of the media existed in the lower parts of the body, slight cloudiness in the upper. Dilatation (average $\frac{27}{20}$) and tortuosity, with some degrees of intimal and adventitial sclerosis existed, most marked

in the larger arteries and those of the lower limbs. Some atheroma existed in the largest vessels only.

In all the other cases submitted with this paper the leading symptoms during life were circulatory, and the leading change after death was cardio-arterial hypermyotrophy, many of them,

FIG 80.

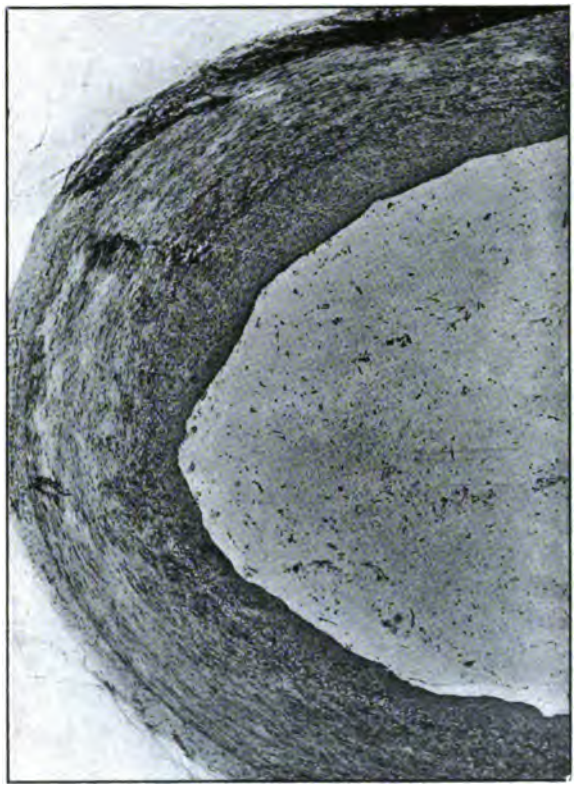

Radial artery (stained with logwood and neutral orcein × 40) showing hypermyotrophy, with commencing cloudy and granular degeneration, dilatation, and generalised intimal sclerosis. Case of Charles W—, aged 65 years, referred to in the text. [Case 48.]

as already explained, being mixed when they reached the dead-house with degeneration or other conditions.

In Case 48, Group A, Charles W—, aged 65 years, a case of senile vertigo who died of cardiac failure, the hypermyotrophy, which amounted in some places to $\frac{6 \cdot 1}{2 \cdot 5}$, was associated with

marked dilatation (amounting sometimes to $\frac{47}{20}$) and some generalised intimal sclerosis.

In Case 60, Group B, Mary N—, aged 76 years, a case of chronic renal disease, who died of uræmia, the hypermyotrophy

FIG. 81.

Radial artery (stained logwood × 40) of a man, William J—, aged 75, showing hypermyotrophy, cloudy and granular degeneration, which make the artery brittle to mount; slight dilatation, some intimal sclerosis. Case referred to in the text. [Case 70.]

averaged $\frac{4}{2 \cdot 5}$, and was associated with some degeneration and dilatation in the larger arteries, contraction in the smaller arteries.

In Case 70, Group B, William J—, aged 75 years, a case of giddy, fainting, and cyanotic attacks, who died of "senile decay," the hypermyotrophy was associated with degeneration, dilatation, and slight generalised intimal sclerosis.

In all the 30 cases which are submitted the muscular coat of the arteries was increased in thickness, even after making allowance for any dilatation or contraction of the vessel. Microscopic measurements showed that the average increase in the muscular tissue of the arteries of the 17 cases in Group A was nearly 50 per cent., *i.e.* one and a half times the normal; the greatest average increase was $\frac{12}{5}$, the smallest $\frac{7}{6}$ of normal. In Group B the average was about 31 per cent. The increase of the muscular coat had in many instances taken place in length as well as thickness, so that the artery had become tortuous. A thickened tunica media when fairly marked can, after a little practice, be detected by the naked eye or with the aid of a one-inch Codrington lens. The vessel loses some of its pliability, remains unduly patent, and does not collapse as a normal artery does. The media may even project beyond the intima and adventitia as though their connections were loosened. Histologically the change I am referring to is not a fibrosis, even in the arteries or arterioles, for the rod-shaped nuclei could always be revealed when the section was efficiently and thoroughly prepared (*see* Appendix).

As regards distribution, I found that the radial artery might be regarded in most cases as a tolerably fair sample of the thickness of the muscular tunic throughout the arterial system, though by no means of its condition as regards degeneration. The media of the arteries of the lower extremity were nearly always more hypertrophied (or presented a more advanced stage of degeneration) than those of the upper extremities, and these latter were more affected than those of the brain. The different arteries of a limb might vary considerably among themselves both as regards thickness and degeneration. The middle coat of the cerebral arteries was often quite normal in thickness, a most interesting fact. The major distribution in the lower extremities suggests the explanation that gravity throws more strain upon these latter, and that the relative exemption of the cerebral arteries was due to the same cause. Dr. George Oliver's and Dr. Leonard Hill's observations (*loc. cit.*) support this view. This relative exemption of the cerebral vessels from the thickening of the media probably helps, as previously mentioned, to

explain the frequent occurrence of cerebral hæmorrhage in cases of arterial hypermyotrophy.

Among the *causes of arterial hypermyotrophy*, the first question which claims our attention is its relation to chronic renal disease. Sir George Johnson[1] first demonstrated muscular hypertrophy in the systemic arteries and arterioles of the kidney in association with chronic renal disease, and this has been confirmed by others.[2] Undoubtedly chronic renal disease is very constantly accompanied and followed by arterial hypermyotrophy. This, indeed, is what one would expect from the high blood-pressure which is so usual in renal disease. But chronic renal disease cannot be regarded as the only cause of arterial hypermyotrophy, for out of the thirty cases submitted only nine could be classed as suffering from chronic renal disease, four out of 17 in Group A (Cases 43, 46, 51, and Case 44, who presented alcoholic fatty degeneration of all organs), and five out of 13 in Group B. In the remaining two thirds (21 cases) there were no urinary changes during life, and no evidence of renal disease after death. It is now universally admitted that a slight degree of fibrosis in all organs is normal and usual in the aged, but this is not likely to be mistaken for incipient interstitial nephritis, especially when the urine has been normal during life, and the weight, macro- and microscopic characters of the kidneys are natural.

The name of Bright should surely be attached only to cases presenting characteristic urinary changes and *post-mortem* evidences of kidney disease. But since the days of Mahomed, Ewald, and others (1881) the term "chronic Bright's disease" has by many been held to connote sometimes primary renal disease followed by arterial hypermyotrophy, and at other times a generalised morbid condition characterised by persistent high arterial tension, various circulatory and nutritional defects, associated or followed with more or less indefinite evidences of renal disease. I wish to protest against the name of Bright being applied to any but cases exhibiting characteristic urinary changes and *post-mortem* evidences of renal disease. Such a

[1] 'British Medical Journal,' 1870, vol. i, p. 381; 'Med. Chir. Trans.,' 1873, and elsewhere.

[2] Professor Hamilton, 'Text-book of Pathology'; Dr. W. H. Dickinson, "The Baillie Lectures," the 'Lancet,' July 20th, 1895, p. 136, and others.

confusion is undesirable, and I would submit (1) that the generalised condition to which I have just referred consists in reality either of cardio-arterial hypermyotrophy and its consequences or of the senile hyperpiesis described by Prof. Clifford Allbutt,[1] or some other form of high tension, with its concomitant circulatory and nutritional defects; (2) that the term "chronic Bright's disease" should only be applied to cases of undoubted chronic renal disease; and (3) that chronic Bright's disease as so defined is a potent, though not the only, cause of arterial hypermyotrophy. I have not met with any facts in support of the hypothesis that disease of the general vascular system is ever the starting-point of renal disease.

2. Hypertrophy of the heart may well be regarded as in some way causally related to arterial hypermyotrophy; either may be the cause of the other, or both may be the product of a common cause. It existed in all of the seventeen cases in Group A, the average weight being 13·9 ounces, two being as high as 19 ounces. In none of these did any valvular disease exist, six cases of arterial hypermyotrophy with cardiac valvular disease having been excluded from the list of cases on this account. In Group B the average weight of the heart in the thirteen cases was 12·5 ounces, one being as high as 17·5 ounces. In persons whose ages were mostly over 60 it is not to be expected that the heart, though hypertrophied, will be free from some kind of degenerative changes. Nevertheless, in thirteen the microscopic structure was healthy or exhibited only the "brown atrophy" of the aged. Fatty degeneration existed in only three cases, fibroid degeneration in six, and some granular degeneration in ten. The pericardium was adherent in three cases.

The leading fact to be derived from these data is that the heart is practically always hypertrophied in cases of arterial hypermyotrophy. Conversely, my belief is that if the arterial system were investigated in cases of cardiac hypertrophy some arterial hypermyotrophy would probably be found, and much light might thus be thrown upon the subject. It is only natural that the opposing forces of the heart and arteries should act and react on each other. But which of these first hypertrophies, or whether, as seems probable, they both start at

[1] The 'Lancet,' January 17th, 1903, p. 170.

the same time, and finally, which first begins to give way and degenerate, must differ in different cases and often be matters of conjecture.

3. High arterial tension, or as some say, high pulse tension, sometimes intermittent but usually persistent, has existed in all the cases of arterial hypermyotrophy which I have observed before arterial dilatation or degeneration has occurred, and in some cases after this has taken place. This was investigated by the finger and the pulse tracing in all but a few cases which were seen after Hill and Barnard's instrument was adopted for clinical work. It is not possible to obtain evidence of the high tension having existed antecedent to the occurrence of any arterial hypermyotrophy, but in view of the well-known fact that excessive functioning, in health at any rate, produces overgrowth, and the frequency with which the known causes of high tension could be revealed in the history of the cases submitted, it seems extremely probable that high arterial tension is the main cause of arterial hypermyotrophy. For instance, in the seventeen cases in Group A there was a history of alcoholic excess in seven, of gout in two, of passing gravel or lithates in six, chronic renal disease existed in three, and in one there was no information of value on the point. My belief is that these figures represent approximately the truth about the matter, and that alcohol in anything more than medicinal doses plays the leading *rôle* in this and other medial changes, sugar in excess perhaps coming next. Generalised intimal sclerosis of the peripheral arterioles (not in the renal system only) existed in the renal cases, and in some of the others, and may have been a cause of high blood-pressure in the arteries.

Age and heredity no doubt play their part in causation. But the information before us is not sufficient to draw any very definite conclusions. The average age at death of sixteen out of the seventeen patients (excluding Case 41, who died of accident) in Group A when they reached the *post-mortem* room was 66·5, but this is no guide as to when the condition supervened. It may have existed ten or twenty years in some, two or three in others; many had had symptoms for years. Three died, aged 38, 42, and 56 years, of cardiac failure, uræmia, and cerebral hæmorrhage respectively; the remainder were over 60 when they died. In Group B the average age at death was 74·5.

These were cases in which the media presented marked degeneration, and which were complicated by other arterial diseases.

The *consequences* of arterial hypermyotrophy seem to be mainly the same as those of high arterial tension, namely, hypertrophy of the heart and subsequent degeneration of the cardio-arterial system, with disturbance of the functions of all organs. Cardiac hypertrophy has already been alluded to. (1) Undoubtedly the most serious consequence is cerebral hæmorrhage; it occurred in four cases in Group A, and in two in Group B. This seemed to be due not so much to the hypermyotrophy in the media of the cerebral arteries themselves as to the relative immunity of these vessels. Arterial hypermyotrophy being most marked in the systemic arteries, the rigidity of these vessels throws a strain on the least protected part. Any excessive cardiac hypertrophy undoubtedly contributes to this end. When describing the case of Hall (Case 42) I alluded to the possibility of minute foci of necrosis which might easily be overlooked also forming an important factor in this and other hæmorrhages. It will be noticed that hæmorrhages in situations other than the brain, epistaxis, dermal hæmorrhage, frequently arose in several of the cases, more particularly in Group B, cases in which degenerative changes in the arteries are most marked. Cerebral accidents other than cerebral hæmorrhage occurred in only one case in Group A and four in Group B. (2) Reference has already been made to various degenerative changes in the media which supervene on arterial hypermyotrophy. Hypermyotrophy is only the first step, hence the rarity with which pure cases are met with in the *post-mortem* room, and hence the importance of its recognition. The most directly lethal degeneration undoubtedly is focal necrosis. (3) A certain degree of fibrosis of organs was present in all the cases, particularly perivascular fibrosis. Sometimes it was very slight and ill marked. This is in some measure a normal occurrence in advancing years, but its presence also in case of hypermyotrophy under sixty has led me to regard it as a usual sequence of arterial hypermyotrophy. (4) If the patient escape cerebral or other accidents, if the heart compensate sufficiently but not excessively, and if the arterial hypermyotrophy and degeneration be not excessive, or if a certain degree of compensatory arterial dilatation occur, it would seem as though the patient may live for many years, and

even to a good old age. It is uncompensated or over-compensated hypermyotrophy which seems to be the chief potential evil. (5) The actual causes of death in the thirty cases submitted are summarised in the following table (Table III). It will be seen that intercurrent diseases account for thirteen, senile decay and asthenia for eight, cardiac failure and syncope for three, cerebral hæmorrhage for four, and uræmia for two. (6) The clinical phenomena have been referred to above and on a previous occasion.[1] They consist mainly of progressive asthenia, with various circulatory symptoms, and especially vertiginous

TABLE III.—*Showing the causes of death in Groups A and B.*

	Group A.	*Group B.*
Cerebral hæmorrhage	4	—
Senile decay and asthenia	3	5
Cardiac failure and syncope	2	1
Uræmia	1	1
Intercurrent maladies:		
Fatty degeneration of organs	1	—
Epidemic skin disease	5	1
Tuberculosis	—	2
Pneumonia	—	2
Strangulated hernia	—	1
Accident	1	—

sensations produced by variations in posture. In all the thirty cases submitted a definite history of postural vertigo, fainting sensations, or other postural circulatory symptoms existed, excepting in Case 43, in whom dyspnœa was the most prominent symptom, and Case 41, who was not under observation during life. The three conditions with which arterial hypermyotrophy are apt to be confused are old age, granular kidney, and other forms of arterial sclerosis or arterial degeneration. Granular kidney is, as we have seen, not infrequently an associated pathological condition, occurring, like it, in the latter half of life; this fact and the one which Sir William Broadbent[2] and others such as that which is apt to occur in arterial hypermyotrophy)

[1] 'British Medical Journal,' vol. i, 1897.

[2] 'On the Pulse,' Cassell & Co., London, 1890, p. 153.

have pointed out, namely, that a generalised arterial contraction may of itself give rise to copious urine of low specific gravity, with an occasional trace of albumen, do not render the diagnosis easier. The difficulty of distinguishing arterial hypermyotrophy from senile decay is also considerable, because arterial hypermyotrophy and its sequelæ constitute, if my observations be correct, some of the main factors in senility. Other forms of arterial sclerosis are so frequently associated with, and secondary to, arterial hypermyotrophy that it is hardly possible to distinguish them clinically.

In regard to the *prevalence* of arterial hypermyotrophy, judging by an infirmary experience, the morbid condition would seem to be a relatively frequent one. It will be seen that twenty-eight cases were met with out of 257 autopsies in the space of nineteen months.

The *treatment* of arterial hypermyotrophy cannot be discussed here, but two points merit reference. First, the marked effect of vaso-dilators such as nitro-glycerin in the early stages of many of the cases submitted indicates a genuine muscular hypertrophy. A fibrosis or a purely degenerative change could not be modified in this way. Secondly, the conclusion has been forced upon me that if one could prevent hypermyotrophy of the arteries one could prolong life. Hypertrophy of the muscular coat of the arteries is but the first step to senile decay.

In conclusion my main contentions are:

1. That the histo-pathology of the different tunics of the arterial system should be studied separately, just as are the different coats of the heart, *i. e.*, that a histological and etiological distinction should be made between intimal, medial, and adventitial sclerosis.

2. Careful histological methods and a large number of specimens are necessary before generalisations can be made: neutral- and acid-orcein are valuable aids.

3. That advanced atheroma and a considerable degree of intimal and of adventitial sclerosis may exist without serious consequences and be compatible with extreme old age, provided the muscular tunic is unaffected.

4. The prime importance of the muscular tunic, relatively to the intima and adventitia, in that it constitutes the functionally active structure of the arterial system and the regulator mechanism of the whole body.

5. The existence of arterial hypermyotrophy as a substantive generalised change in the arterial system.

6. The importance of its recognition by reason of the potential evils in the way of circulatory derangement, circulatory accidents, nutritional disturbances, disturbance of the balance between the heart and arteries, and the degenerations which are apt to ensue.

7. It is the first step towards the condition we call senile (or generalised) decay, and is the main cause of senile vertigo at any age. The combination of arterial hypermyotrophy and focal necrosis of the media is a most deadly one, and may produce death by hæmorrhage at a comparatively early age (*e.g.*, Case 46, aged 49).

8. Arterial hypermyotrophy may be due to chronic renal disease, but it has many other causes, all of which probably produce the condition by producing high arterial tension or in other ways disturbing the balance of the circulation.

APPENDIX.

Material available. Methods of investigation.

During the nineteen months June 1st, 1890, to December 31st, 1891, there were 257 autopsies made at the Paddington Infirmary. Twenty-eight of these 257 cases were patients who had presented circulatory symptoms or accidents during life, but who had no cardiac valvular disease. It was the combination of these two circumstances which induced me to investigate their arterial system in these 28 cases. The muscular tunic of every one of these cases was increased in thickness; in many it was associated with other morbid changes in the media, and in some with abnormalities in the other arterial tunics. Two similar cases (No. 41, a case of accidental death, and 42, a case of arterial hypermyotrophy, who died in the Paddington Infirmary in the spring of 1892) are added to this list, making 30 in all.

These 30 cases have been arranged in two groups:

Group A comprises 17 cases in which the arterial hypermyotrophy was *relatively* uncomplicated with other arterial disease; and by less advanced degeneration of the tunica media. Group B

comprises 13 cases in which the arterial hypermyotrophy was complicated with advanced degeneration, dilatation, or other arterial disease, viz., intimal or adventitial sclerosis or atheroma. These cases represented, I believe, the later or final stages.

I had tabulated these cases in columns under the following headings, but for convenience of printing they are now set out in a series of paragraphs, each headed with a Roman numeral corresponding to the following headings:

I. NAME, SEX, AGE, DATES OF ADMISSION TO INFIRMARY AND DEATH.

II. CLINICAL OUTLINE OF CASE AND SYMPTOMS REFERABLE TO THE CIRCULATORY SYSTEM.

III. PAST HISTORY AND POSSIBLE CAUSES.

IV. POST-MORTEM EXAMINATION OF THE SYSTEMIC ARTERIES, NAKED-EYE AND MICROSCOPIC, GIVING A GENERAL RÉSUMÉ OF THE DETAILS DISCOVERED CONCERNING THEIR CALIBRE AND THE THICKNESS AND STRUCTURE OF EACH TUNIC.

V. OF THE CEREBRAL ARTERIES AND BRAIN.

VI. OF THE HEART.

VII. EXAMINATION OF THE KIDNEYS AFTER DEATH, AND THE URINE DURING LIFE, AND PARTICULARS OF OTHER ORGANS WHEN NECESSARY.

VIII. SUMMARY STATEMENT OF CASE.

In regard to the first three headings, all but one of these 30 cases were under my care (some for several years) during life. I was fortunate at that time in having two very able assistant medical officers in the persons of Dr. Victor Hugo and Miss Annette Benson, M.B.Lond., and a valuable pathological assistant in Mr. H. J. Waring, to all of whom my thanks are due for the aid they rendered me in this laborious inquiry.

In the description under the heading IV, "Systemic Arteries," the following order is adopted: (1) The general condition of the *calibre* of the arteries; (2) the condition of the *media*, its size or thickness, any degeneration or special features to note therein; (3) the condition of the *adventitia*, its size and condensation; and (4) the condition of the *intima*, presence of any generalised intimal sclerosis, and the presence or absence of atheroma. The term "larger arteries" refers to such arteries as the aorta, iliac and femoral; "medium-sized arteries"

to such as the brachial, radial, basilar, splenic, and renal; "smaller arteries" to all the branches of these latter visible to the naked eye; and "arterioles" or "microscopic arteries" to such as cannot be well seen without the aid of a microscope occurring in the muscles and viscera.

Methods of examining the arterial system.—The difficulties of such an investigation have already been alluded to. After death the cases were investigated in two ways, (*a*) by dissection and examination of the vascular system naked eye and with the aid of a 1-inch lens—a procedure which frequently occupied a very considerable time; and (*b*) by microscopic sections of arteries and tissues stained in various ways and unstained. At the autopsies which were made by me or under my immediate supervision 24 to 48 hours after death all the principal arteries of the head, trunk, and limbs were examined, and compared with a set of normal specimens kept for the purpose. To estimate the calibre and to detect definite thickening of the arterial wall, and which tunic is chiefly involved, by naked eye or lens, is quite possible after a little practice. The feel of the vessel also between the finger and the thumb is fairly characteristic; the lumen also remains unduly patent.

Microscopic sections in some cases were made from quite fresh specimens, but mostly pieces of the arteries and tissues were first preserved in alcohol (about 50 per cent.). A few were placed in Müller's fluid for a few weeks, and then (after being well washed) in alcohol. Sections of most of the cases were mounted in 1890, 1891 and 1892; some were not prepared until 1896–8, but I ascertained by examining sections from the same specimens that no change had occurred. Müller's fluid is not a suitable preservative, because afterwards the tissues do not stain so well, and an appearance of fibrous tissue in the media may result. The rapid method of hardening small pieces of organs with a saturated solution of mercuric chloride was tried in one case, but I cannot recommend the procedure; alcohol is certainly the best preservative. Sections of the tissue or artery, taken from different places in its length if any different appearances were visible, and carefully labelled, were then soaked in celloidin and cut with a Reichart's microtome.

Measurements were made of nearly 1500 sections of arteries from these cases (besides the sections of muscles, tissues, and

organs) under the microscope with the aid of an eyepiece micrometer, and compared with a corresponding normal specimen prepared in the same manner. The difficulty of obtaining an exact normal standard has already been alluded to. The arteries of a man aged about 25 years who committed suicide while in apparent health were chiefly used, many of the measurements being checked by other examples. Measurements were made first of the lumen of the tube, expressed as the mean between the two diameters, next of the total thickness of the wall, and finally of each coat separately (*first* the media, *next* the adventitia and *lastly* the intima). These measurements were then recorded in five columns of a huge table which it has not been thought necessary to reproduce. Averages were struck, and a summary description of each case is given below. The measurements were recorded simply in terms of micrometer divisions in the form of a fraction or *ratio*, abnormal above, normal measurement (measurement of the same artery in a normal subject) below. At first some were worked out in fractions of a millimetre, but the task did not seem commensurate with the gain so long as the proportion to normal was given. The process described was sufficiently tedious and trying to the eyes, hence the length of time required to complete the investigation, and the fact that it was several times interrupted by eye-strain and recurrent iritis. Throughout this communication the figures represent arbitrary micrometer divisions, with only one exception, namely, THE MEASUREMENTS OF THE RADIAL ARTERIES UNDER HEADING IV, WHICH ARE EXPRESSED IN TERMS OF MILLIMETRES, and are here given for purposes of comparison because the radial artery is one of the most accessible and has proved in most (though not all) instances to be a fair sample of the arterial system as regards measurements.

Staining methods.—Any protoplasmic stain will bring out the rod-shaped nuclei of the muscle-fibres if adequate time and care be employed, and the specimens have not been badly preserved, but an aqueous solution of logwood was found to give the best results. It is necessary to leave arterial sections in longer than the time required for other tissues, and I found a solution of moderate strength better than a strong solution for a shorter time. The muscular coat of the arteries, consisting of a dense

circular layer of muscular fibres,[1] is bounded on either side by a well-marked layer of elastic tissue. Internally this tissue forms the fenestrated membrane of Henle, and externally the elastic fibres form a closer network (not recognised in most histological text-books) than that which exists more sparsely scattered through the adventitia. Very early in the inquiry it appeared to me that if I could adopt some reagent which would bring out these two boundaries of elastic tissue, measurement would be easier and there would be less likelihood of mistaking the tunic which was the seat of disease, an error which is liable to occur in advanced arterial disease, especially when the disease has spread from tunic to tunic (Figs. 70 and 71). After numerous experiments with other stains I found that *acid orcein* was exactly suited to this purpose. Orcein is a neutral aniline dye, which gives to connective tissue a beautiful golden-red colour, and if mixed with a certain proportion of hydrochloric acid has a very special selective quality for elastic tissue. The acid solution consists of neutral orcein 2 grammes, strong hydrochloric acid 2 c.c., alcohol (70%) 96 c.c. It does not give such good results when the tissues have been preserved in bichromate as in spirit. My method of staining with acid orcein was as follows. The sections being in about 60 per cent. alcohol are next placed in some of the filtered stain for 4 or 5 minutes. Other tissues may need less, but senile arteries require quite this time. Next, lightly wash in weak alcohol, to which a little ether may be added to extract the celloidin. If too darkly stained, leave the section in the alcohol a little longer, or else wash it in weak acid alcohol (not exceeding 1 per cent.) in which case the acid must be afterwards thoroughly washed out in plain water. Finally, place the section for a few minutes in absolute alcohol, float on clove oil, and mount in balsam.

Neutral orcein solution is made with $\frac{1}{4}$ gramme of orcein to 100 c.c. of 60 per cent. alcohol. The sections require to be left in this about 4 to 5 minutes; remove excess of stain in absolute alcohol, oil of cloves, and mount. This stains the ground substance of the muscle-fibres and has no selective actions on elastic tissue. It is a valuable stain, however, for revealing

[1] *Longitudinal* muscular fibres are found in small quantity normally in the aorta, umbilical, renal, superior mesenteric, splenic, the arterioles of the pia mater, and abnormally in many situations.

lighter shades of degeneration. A gentle heat facilitates all these staining operations. Double stainings were made in many cases, first in orcein (neutral or acid) afterwards in logwood. These were the principal methods, but others were also employed for different purposes, such as osmic acid, eosin, carmine, methyl blue, gentian violet, auric chloride and silver nitrate. My practice was to mount two sections on one slide, one stained with acid-orcein, showing the boundaries, the other with logwood (or neutral orcein, or both) to reveal the degenerative or other changes. Unstained specimens were also examined. In unstained or lightly stained sections the tunica media presents exactly the glistening and refractile appearance of fibrous tissue, the boundaries of which are quite indistinguishable from a sclerosed intima. Possibly the unfortunate term "arterio-capillary fibrosis" has arisen in this way.

Group A.—17 Cases of Relatively Uncomplicated Arterial Hypermyotrophy. Cases 41–57.

Case 41.

I.[1] Henry G—, male, aged 30 years, died November, 1896, of bicycle accident. (Case referred to and illustrated in Fig. 72.)

II. Was at work. Wife stated that he had always enjoyed good health, but was subject to headaches. Died of fractured ribs and ruptured liver twelve hours after accident.

III. No precise information. He worked hard and stood a good deal at his work.

IV. *Arteries.*—The media of all the medium, small, and microscopic arteries throughout the body hypertrophied, the average increase of fifty-five arteries examined being 37 per cent. No degeneration. Slight cloudy swelling in the arteries of the lower extremities. Adventitia and intima normal.

V. Cerebral arteries normal.

VI. Heart 11½ ozs. Slight hypertrophy of left ventricle.

VII. Right kidney, 4½ ozs.; left, 5 ozs. Substance normal, both naked eye and microscopic. Slight increase of tunica adventitia in places. Urine, no information.

VIII. Arterial hypermyotrophy in an early phase without, as far as was known, any symptoms excepting headache. Death by an accident.

Case 42.

I. Joseph H—, male, aged 56 years, admitted April 14th, 1892, for

[1] The significance of the Roman numerals is explained on p. 409.

left hemiplegia; died April 16th, 1892, of cerebral hæmorrhage. (Case referred to and illustrated in Figs. 74, 75.)

II. "Swimming in head" and giddiness on stooping, headache, depression of spirits and occasional breathlessness for past two years (particulars confirmed by his wife). On admission forcible apex-beat; pulse full; arterial tension high; noted that "artery feels like whipcord." The hemiplegia, which was flaccid, occurred on the previous day, without loss of consciousness. His mother died of a stroke of hemiplegia, age unknown. One sister was in an asylum. A brother, aged 58 years, had been in the infirmary, and was noted as having had the same "whipcord-like" arteries and to have complained of giddiness when he stooped.

III. Road-sweeper. Both beer and spirits in fairly liberal quantities.

IV. Throughout the body and limbs there was hypertrophy of the *tunica media*. The average increase in thickness amounted to $\frac{4}{2\cdot5}$. It was most marked in the lower end of such vessels as the radials and tibials; the arterioles of the viscera were less affected. The lumen of all the vessels was normal. The unsupported arteries were tortuous. Only one artery was dilated—the dorsalis pedis. *Tunica adventitia* condensed but otherwise normal. No *intimal* sclerosis, but a few scattered patches of atheroma in the lower limbs. One minute necrotic focus was found in the otherwise healthy muscular tissue of the radial, one in a renal arteriole, one in the basilar, and one in a branch of the middle cerebral. *Radial artery* $\frac{2\cdot4}{2\cdot2'}\ \frac{0\cdot76}{0\cdot27'}\ \frac{0\cdot22}{\bar{0}\cdot22'}\ \frac{0\cdot11}{\bar{0}\cdot11}$.[1]

V. A recent blood-clot, size of a hen's egg, occupied the right internal capsule. Cerebral vessels appeared everywhere healthy; no thickening of the media or atheroma could be detected naked eye or by microscope, but on prolonged search a small necrotic focus in the media, partly protruded by the force of the blood through the vessel wall, was discovered in the middle cerebral (Fig. 74). Sections of the vessels in the neighbourhood of this were quite healthy.

VI. Heart 13 ozs. Left ventricle hypertrophied. Valves healthy. *Microscopically.*—Normal.

VII. Kidneys: right, 4 ozs.; left, 4½ ozs. Slight congestion; capsule not adherent or thickened; vessels patent. Urine on April 15th: acid, clear, high-coloured; sp. gr. 1030; no albumen; no sugar.

[1] The measurements of the radial artery are given as an example, and in these particular measurements the micrometer divisions have been *worked out in millimetres.* The first of the four ratios gives the lumen of the artery (the normal standard being placed below), the second the thickness of the muscular coat, the third the adventitia, the fourth the intima.

VIII. Arterial hypermotrophy and cardiac hypertrophy terminated at an early phase of the disorder at the age of 56 by cerebral apoplexy. Kidneys and urine healthy. Four minute necrotic foci were discovered with difficulty, but otherwise there was no obvious degeneration of media.

Case 43.

I. Elizabeth S—, female, aged 42 years, admitted May 19th, 1890, for epistaxis, died June 4th, 1890, of uræmia.

II. Progressive feebleness of body and mind. Attacks of dyspnœa for eighteen months before admission. Epistaxis on admission and repeated attacks later. Heart on admission, violent action, apical systolic murmur of dilation. Pulse small, rapid, feeble; thickened radials. Respiration sighing, sometimes laboured. Before death hæmorrhage from gums and purpuric eruption on legs. Died of uræmic coma.

III. History very deficient. Had been drinking hard for several years. Deposits of urate of soda in kidney substance (gout).

IV. Arterial lumen contracted. *Media* increased everywhere to about same as radial $\left(\frac{4}{2\frac{1}{2}}\right)$. *Adventitia* moderate increase. Marked intimal increase in renal and other visceral arterioles. *Radial* $\frac{2\cdot20}{2\cdot20}$, $\frac{0\cdot44}{0\cdot27}$, $\frac{0\cdot27}{0\cdot22}$, $\frac{0\cdot16}{0\cdot11}$.

V. Brain and cerebral arteries not examined. No cerebral symptoms other than uræmic coma.

VI. Heart 15 ozs. Left ventricle much hypertrophied and dilated. Muscle firm. Valves normal. *Microscopically.*—Marked brown induration, *i.e.* brown atrophy, with fibrosis. No fatty change.

VII. Kidneys: right, $3\frac{1}{2}$ ozs.; left, $2\frac{1}{2}$ ozs. Pale, granular on surface; capsule adherent. Cortex atrophied. Extensive deposits urate of soda, crystals. Arteries patent and thickened. *Microscopically.*—Typical granular kidney with numerous deposits of urate of soda. Urine copious, clear, pale, average sp. gr. 1011. Always a trace of albumen, once $\frac{1}{40}$th.

VIII. A case of chronic renal disease associated with cardio-arterial hypermyotrophy. Death by uræmia.

Case 44.

I. David D—, male, aged 38 years, admitted August 23rd, 1890, for cardiac failure; died in a convulsive seizure the same day.

II. First attack of "swimming in the head" in 1885, and several since then. In November, 1889, admitted with dropsy of the legs and signs of congestion of the lungs. Dyspnœa very severe and persisted after pulmonary condition relieved. On August 23rd, 1890, it was noted "breathlessness extreme, pulse small, thready, 180, arteries thickened."

III. A stableman; history of alcoholic excess. No information on other points.

IV. Arteries throughout the body dilated to an average of between $\frac{30}{20}$ to $\frac{36}{20}$. *Muscular* coat increased (even without allowing for the dilatation) to an average of between $\frac{3}{2\cdot5}$ and $\frac{3\cdot7}{2\cdot5}$. Slight cloudy change, chiefly in the inner layers, revealed by acid orcein. *External* coat, slightly increased; internal coat, slightly diminished, not diseased. *Radial* $\frac{4\cdot07}{2\cdot2}$, $\frac{0\cdot41}{0\cdot27}$, $\frac{0\cdot27}{0\cdot22}$, $\frac{0\cdot8}{0\cdot11}$.

V. Cerebral arteries unaffected; brain extremely bloodless.

VI. Heart 14 ozs., dilated and degenerate, half fat, half muscle; valves normal.

VII. Kidneys: right, 7 ozs.; left, 7 ozs.; extremely congested, typical cardiac kidney. *Microscopically.*—No notable increase in interstitial tissue; arterioles thickened and dilated; other organs congested; liver fatty, 72½ ozs. Urine: November, 1889, normal, no albumen; August 23rd, 1890, dark, scanty, high sp. gr., albumen $\frac{1}{5}$.

VIII. Arterial hypermyotrophy with cardiac hypertrophy, followed by extreme cardiac degeneration and dilatation, and death by convulsions; in an alcoholic subject.

Case 45.

I. Mary Ann C—, female, aged 64 years, admitted October 22nd, 1890, for cerebral apoplexy; died next day.

II. Sister stated patient had had occasional "dizziness" for some years, more frequently of late. Admitted in a state of apoplectic coma. Cardiac area enlarged. Pulse 100, intermittent; arteries thick and contracted.

III. Past history deficient.

IV. Medium, small, and micro-arteries contracted; larger ones dilated (calibre of the femoral $\frac{50}{39}$). *Media* thickened, most in the micro-arteries; cloudy and granular changes in places. *Adventitia* dense

but not increased. *Intima* not much affected, thickened in popliteal and arteries of lower extremities. *Radial* $\frac{1\cdot54}{2\cdot2}$, $\frac{0\cdot60}{0\cdot27}$, $\frac{0\cdot27}{0\cdot22}$, $\frac{0\cdot22}{0\cdot11}$.

V. Intra-ventricular hæmorrhage; arteries free from atheroma. *Media* not increased, cloudy and granular changes in places; no necrotic focus could be found, as in case of Hall.

VI. Heart 10½ ozs. Left ventricle one third thicker than normal. Slight atheroma of aorta. Valves normal. *Microscopically.*—Pigmentary changes of old age. Coronary trunks thickened and contracted.

VII. Kidneys: right, 3½ ozs.; left, 3½ ozs. Capsule strips readily: no granular surface; arteries patent. *Microscopically.*—Arterioles much thickening of t. media, t. adventitia, and intima. Slight increase of interstitial tissue (senile), but no evidences of disease. Note in case-book "urine normal"; no particulars given.

VIII. A case of arterial hypermyotrophy, with cardiac compensation, associated with some degree of medial degeneration and contracted arteries; not complicated by atheroma, adventitial sclerosis, or chronic renal disease. Death by cerebral hæmorrhage.

Case 46.

I. William W—, male, aged 49 years, admitted January 29th, 1889, with tertiary syphilis of nasal bones and chronic gout. Died February 4th, 1891, of apoplexy.

II. In 1889 an apical systolic murmur due to dilatation (valves healthy) was noted. For three years frequently complained of giddiness, sometimes followed by vomiting. Breathlessness and exhaustion also noted.

III. A plumber; suffered from gout all his life. He passed gravel. Syphilis in early life; tertiary involvement of nasal bones. Formerly excess of alcohol.

IV. Moderate hypermyotrophy, average $\frac{3}{2\cdot5}$, with some dilatation $\left(\frac{24}{20}\right)$ of lumen in all the medium and small arteries. Diffuse granular change, predominating in the arteries of the lower extremities. Some of the larger arteries (femoral, splenic, renal and external iliacs) dilated, but otherwise healthy. *Adventitia* normal. *Intima* normal, excepting in the kidneys. *Radial* $\frac{3\cdot63}{2\cdot2}$, $\frac{0\cdot44}{0\cdot27}$, $\frac{0\cdot14}{0\cdot22}$, $\frac{0\cdot11}{0\cdot11}$.

V. Smaller cerebral arteries atheromatous in places and slightly dilated. No hypermyotrophy. Tunica media slightly cloudy, commencing granular degeneration in places. One necrotic focus found after prolonged search; probably others existed. Large intra-ventricular hæmorrhage.

VI. Heart 12½ ozs.; hypertrophied, not dilated. Left ventricular wall nearly one inch thick; substance firm. Valves normal. Fibres show pigmentary changes, but otherwise healthy.

VII. *Kidneys.*—Right, 4 ozs.; left, 4 ozs. Cortex diminished. Capsule adherent. *Microscopically.*—Much fibrosis and cell infiltration, with congestion; cloudy swelling of epithelium. In 1888 urine normal. For two years, 1889–1891, urine contained measurable quantity of albumen, and was of very low sp. gr.

VIII. Arterial hypermyotrophy with granular (large red) kidneys in a patient the subject of gout and syphilis. Death by apoplexy.

Case 47.

I. David S—, male, aged 79 years, admitted February 14th, 1890, for enlarged prostate, died February 7th, 1891, of senile decay.

II. For many years attacks of breathlessness on slight exertion, and giddiness on rising at night to micturate. Failing health and strength for six years. On admission, harsh apical systolic bruit, which became less audible under treatment. Cardiac action irregular. "Pulse tension high, arteries thick and tortuous." Bladder symptoms disappeared in a few weeks. Became weaker, mind feebler, wandering at night. Hæmorrhage from prostate day before death.

III. No history of gout or syphilis. No history on other points obtainable. Marked family history of insanity.

IV. The only arteries examined were the radials, brachials, popliteals and posterior tibials, which showed a definite hypermyotrophy, with moderate medial degeneration and some dilatation. In the viscera the hypermyotrophy of the arterioles was more and the degeneration less marked. Intimal sclerosis was also present.

V. Cerebral arteries normal.

VI. Heart 11 ozs. Left ventricle somewhat thickened and dilated. Aorta atheromatous. Valves normal. *Microscopically.*—Brown atrophy of muscle. Coronary arteries commencing atheroma.

VII. *Kidneys.*—Right, 4 ozs.; left, 5 ozs. Capsules a little thickened, but stripped off readily. Vessels prominent. *Microscopically.*—No notable fibrosis, and otherwise healthy. On admission, urine ammoniacal, with pus; subsequently pale, acid, clear, sp. gr. 1015–1020.

VIII. Moderate arterial hypermyotrophy and degeneration, with moderate and proportionate cardiac hypertrophy. No renal or other complications. Death from senile decay.

Case 48.

I. Charles W—, male, aged 65 years, admitted October 21st, 1889, for senile vertigo, died February, 1891, of progressive asthenia, cardiac failure, and hypostatic congestion of the lungs. (Illustrated in Fig. 80.)

II. Attacks of breathlessness for some years; was in workhouse and suffered from "swimmings in the head" since the age of 55. Pulse when noted was slow, and at first high tension. Subject all the while to dyspnœa, and occasionally to faints lasting a few minutes. Latterly arterial tension low and heart sounds scarcely audible. Towards the end of life thrombosis took place in the radial and some other arteries.

III. A painter. No history of gout or syphilis. History of "passing gravel" in former years.

IV. *Media* greatly increased in thickness (average $\frac{6 \text{ or } 7}{2{\cdot}5}$). Larger and medium vessels much dilated $\left(\frac{29 \text{ to } 47}{20}\right)$. Marked granular degeneration in lower limbs. Some *intimal* sclerosis. *Adventitia* not increased. *Radial* $\frac{5{\cdot}17}{2{\cdot}2}$, $\frac{0{\cdot}77}{0{\cdot}27}$, $\frac{0{\cdot}22}{0{\cdot}22}$, $\frac{0{\cdot}27}{0{\cdot}11}$.

V. *Cerebral arteries.*—Media considerably thickened (*e.g.* basilar $\frac{5}{2}$) and degenerated; atheroma of smaller vessels, the lumen being dilated between the patches. Miliary softenings and thromboses in the brain in places, and one in the pons.

VI. Heart 14 ozs.; moderately dilated. Left ventricle wall $\frac{3}{4}$ inch thick. Muscular substance friable. Valves normal. *Microscopically.*—Granular swelling; interstitial increase in parts, especially near surface.

VII. *Kidneys.*—Right, $3\frac{1}{2}$ ozs.; left, 4 ozs. Slight congestion, otherwise normal. *Microscopically.*—Normal. Arterioles remain patent on section, but are normal excepting slight increase of media. On admission, sp. gr. 1024; urine normal. Later, sp. gr. 1016–1020. October, 1890, sp. gr. 1032, and a *trace* of sugar detected, which occurred occasionally till death.

VIII. Arterial hypermyotrophy, medial degeneration, and consequent dilatation. Death by cardiac failure and peripheral thrombotic lesions.

Case 49.

I. Edward P—, male, aged 76 years, admitted December 17th, 1890, for bronchitis, died April 11th, 1891, of cardiac failure.

II. Occasional attacks of giddiness before admission, in one of which he nearly fell off his cab. Pulse rapid and irregular.; arteries hard and tortuous. Dyspnœa increased; cyanosis of extremities.

III. A cab-driver, but did not admit excess of alcohol. Liver 47 ozs., firm, nutmeg in character.

IV. *Media* of medium and small arteries thickened (average about $\frac{3{\cdot}25}{2{\cdot}5}$); granular degeneration also present. Media of microscopic arteries about twice the normal thickness and less degenerated; this thickening extremely marked in the lungs and associated with pulmonary fibrosis. *Adventitia* increased in medium and small vessels. *Intima* normal, excepting some atheroma in large vessels. *Radial* $\frac{2{\cdot}31}{2{\cdot}2}$, $\frac{0{\cdot}44}{0{\cdot}27}$, $\frac{0{\cdot}22}{0{\cdot}22}$, $\frac{0{\cdot}11}{0{\cdot}11}$.

V. Cerebral arteries not examined, but no cerebral symptoms other than giddiness.

VI. Heart 19½ ozs. Both ventricles dilated and both walls hypertrophied. Valves healthy. Muscle pale and soft. *Microscopically.*—Fatty infiltration and granular degeneration. Pericardium adherent.

VII. *Kidneys.*—Right, 4½ ozs.; left, 4 ozs. Congested, cortex not diminished. Capsule not adherent nor thickened. Arterioles much thickened, but kidney substance quite healthy for age. Average sp. gr. 1019; never any albumen.

VIII. Moderate arterial hypermyotrophy without notable arterial dilatation, adequate cardiac compensation, pulmonary fibrosis, and failure of the right side of the heart. Adherent pericardium.

Case 50.

I. Francis N—, male, aged 87 years, admitted November 19th, 1890 for debility; died April 17th, 1891, of senile decay.

II. Breathlessness for some years; had previously been in the workhouse for two years and often complained of vertigo, always on assuming the erect posture; occasionally fell down. Giddiness latterly so marked as to confine him to bed. Pulse on admission could scarcely be felt; arteries thick and tortuous, heart sounds feeble. Died gradually of asthenia.

III. No information.

IV. *Media* increased (average $\frac{4{\cdot}7}{2{\cdot}5}$) in all the medium and small arteries: less marked in the arterioles. Lumen normal. Granular degeneration. Necrotic foci in places. Larger arteries considerably

dilated, and in some the media was thickened (*e.g.* brachial measured $\frac{3\cdot5}{2\cdot5}$). *Adventitia* increased in some arteries. *Intimal* sclerosis moderate but generalised. No atheroma. Marked fibrous intimal sclerosis in the lower extremities. *Radial* $\frac{2\cdot97}{2\cdot2}$, $\frac{0\cdot55}{0\cdot27}$, $\frac{0\cdot27}{0\cdot22}$, $\frac{0\cdot11}{0\cdot11}$.

V. *Cerebral vessels.*—Media showed a hardly measurable increase. Intima generally normal except for a few points of atheroma.

VI. Heart 17 ozs; both ventricles hypertrophied and dilated. Valves normal. Muscle friable, and under microscope granular swelling.

VII. *Kidneys.*—Right, 3½ ozs.; left, 3 ozs. Few cysts in cortex. Vessels patent. *Microscopically.*—Unusually healthy for age of patient. No increase of interstitial tissue. Capsule strips readily. No atrophy of cortex. Urine alkaline on admission, sp. gr. 1030, mucus, few pus-cells, no albumen then or at any time. November 28th.—Urine clear, pale, acid, 1020.

VIII. Arterial hypermyotrophy with cardiac compensation. Incipient degeneration of muscular tissue in both heart and arteries *pari passu*. Typical case of senile decay. No active disease found; the only lesions present were the cardio-vascular changes and fibrosis of lungs.

Case 51.

I. John B—, male, aged 73 years, admitted December 5th, 1890, for general debility and granular kidney. Died June 17th, 1891, of cardio-vascular failure.

II. Subject to fainting attacks for several years in the workhouse. Left hemiplegia came on suddenly without unconsciousness four years before admission, followed by recovery. *Note of April 22nd*, 1889.—"Heart sounds muffled; action irregular; pulse low tension and intermittent; arteries thickened." Had several fainting attacks after admission, in one of which he died.

III. Cabinet-maker. Somewhat alcoholic history. No further information.

IV. All the systemic vessels thickened and dilated, the thickening being mainly due to increased media. Faint granular change in the inner layers. Focal necrosis in arteries of lower extremities and brain. Atheroma in larger vessels and slightly in medium vessels. Arterioles of kidneys and other viscera showed considerable thickening of the intima. *Radial* $\frac{2\cdot64}{2\cdot2}$, $\frac{0\cdot71}{0\cdot27}$, $\frac{0\cdot27}{0\cdot22}$, $\frac{0\cdot16}{0\cdot11}$.

V Cerebral arteries dilated and atheromatous; no hypermyotrophy,

but granular degeneration and several spots of focal necrosis. Scars of old hæmorrhages in the brain.

VI. Heart 13 ozs. Somewhat hypertrophied and ventricles dilated. Valves normal. Aorta atheromatous. *Microscopically.*—Coronary vessels thickened and dilated. Granular degeneration of muscle-fibres, and some interstitial fibrosis.

VII. *Kidneys.*—Right, 2 ozs.; left, 2 ozs. Cortex diminished. Capsule thickened, and surface of kidney granular on stripping capsule. *Microscopically.*—Some interstitial increase; epithelium deficient, glomeruli atrophied and degenerated. Vessels thickened, especially inner coat. Urine clear, pale, acid; sp. gr. 1012; trace of albumen.

VIII. Case of granular kidney with cardio-arterial hypermyotrophy and degeneration, complicated in its earlier stages by small cerebral hæmorrhages. Death not from uræmia or cerebral hæmorrhage, but from cardio-arterial failure and syncope.

Case 52.

I. William S—, aged 70 years. Admitted April 26th, 1890, for catarrhal pneumonia. Died July 22nd, 1891, of senile decay.

II. For several years had had vertiginous attacks in which he tottered and fell. He recovered from the catarrhal pneumonia for which he was admitted in 1890 in the course of two months, but he never regained strength. Constantly became cyanosed and breathless on assuming the erect posture for twelve months prior to death. Pulse fairly good, but low tension, rate 80–90. The dilatation of the arteries and the degeneration of the heart seem to have diminished the effects of the hypermyotrophy. Like so many of these cases, he became restless and imbecile towards the end, putting his legs into his coat-sleeves, etc.

III. No information as to history of past life.

IV. The *media* of the medium and small arteries averaged about twice the normal thickness; granular degeneration prevalent, more marked in the lower extremities. Lumen dilated, but to less extent than in the larger vessels. *Adventitia* condensed, but only a little increased. Prevailing *intimal* sclerosis affecting mainly the larger vessels, which were considerably dilated, the media in these being apparently thin and degenerate, the measurements of the femoral, for instance, being: media $\frac{8}{10}$, adventitia $\frac{2}{2}$, intima $\frac{6}{1}$. The media in the medium arteries was more thickened than in the microscopical arteries. *Radial* $\frac{2{\cdot}42}{2{\cdot}2}$, $\frac{0{\cdot}55}{0{\cdot}27}$, $\frac{0{\cdot}27}{0{\cdot}22}$, $\frac{0{\cdot}16}{0{\cdot}11}$.

V. Cerebral vessels not examined.

VI. Heart 14 ozs. Left ventricle thickened and dilated; right ventricle slightly thickened. Muscle friable; fatty deposit outside. Valves normal. Aorta slightly atheromatous. *Microscopically.*—Muscle fairly healthy; fatty infiltration on the surface of the heart. The aorta was thickened 15 per cent. $\left(\frac{28}{24}\right)$ and atheromatous.

VII. *Kidneys.*—Right, 4½ ozs.; left, 4½ ozs. Appeared healthy. Cortex not diminished. Capsule readily stripped, leaving smooth surface. *Microscopically.*—Normal. Urine always normal, never albumen, sp. gr. varied 1012–1020.

VIII. A case of cardio-arterial hypermyotrophy followed by degeneration, dilatation, and intimal sclerosis. Death by asthenia (senile decay).

Case 53.

I. Thomas C—, male, aged 66 years, admitted July 16th, 1889, for senile vertigo. Died August 8th, 1891, of epidemic skin disease and asthenia.

II. For years while he was in the workhouse had suffered from "swimmings in the head," which were relieved by nitro-glycerine. No record of the circulatory condition on admission.

III. No information.

IV. Marked dilatation of all the arteries, large, medium, and small. *Tunica media* of medium, small, and micro arteries increased. Marked diffuse granular degeneration and necrotic foci in places. *Intimal* sclerosis of the larger vessels. Patchy atheroma in these and in the cerebral vessels, large and small. *Adventitia* condensed. *Radial* $\frac{4{\cdot}95}{2{\cdot}2}$, $\frac{0{\cdot}66}{0{\cdot}27}$, $\frac{0{\cdot}16}{0{\cdot}22}$, $\frac{0{\cdot}11}{0{\cdot}11}$.

V. Cerebral vessels, media very slightly thickened and degenerate, Cerebral vessels extremely atheromatous. No thrombosis or embolic lesions.

VI. Heart 13 ozs., hypertrophied and dilated, muscle friable; much fat. Left ventricular wall three quarters of an inch. Slight atheroma at commencement of aorta. Coronary arteries calcified. *Microscopically.*—Fatty infiltration and fat between muscle-fibres.

VII. *Kidneys.*—Right, 3½ ozs.; left, 3½ ozs. Capsule non-adherent, surface smooth. Vessels patent. *Microscopically.*—Peri-arterial fibrosis in interstitial tissue (senile); glomeruli and epithelium healthy. Urine normal.

VIII. Cardio-arterial hypermyotrophy with marked degenerative changes and dilatation in both heart and arteries. Death by an intercurrent malady (epidemic skin disease).

Case 54.

I. William H—, male, aged 75 years, admitted April 16th, 1890, for senile vertigo; died August 24th, 1891, of epidemic skin disease.

II. In workhouse many years for weakness. "Swimmings in head" for fifteen or twenty years. Occasional brief faints after admission, relieved by nitro-glycerine. On admission enlarged cardiac area; feeble apex-beat. Pulse low tension, slow (average 52), missing every third beat. August, 1890, vertigo on sitting up in bed.

III. Good health all his life. Wife stated his urine used often to get thick on standing in early life. Temperate.

IV. No record as to *calibre* of larger vessels. Considerable hypertrophy of *media* in all the medium and small arteries, associated with only a moderate degree of cloudy and granular changes. Slight increase in *intima* in places. No *atheroma* beyond slight patchy thickening of aorta. Radial not measured because specimen lost.

V. All three coats of cerebral vessels remarkably healthy, excepting a few patches of atheroma in the basilar.

VI. Heart 12 ozs.; fatty and degenerated. Left ventricle greatly dilated and thinned, barely ½-inch thick. Valves normal; muscle cells granular.

VII. *Kidneys.*—Right, 3½ ozs.; left, 3½ ozs. Normal macro- and microscopically; vessels thickened and remain patent. Urine examined twenty-three times; no albumen discovered until attacked by epidemic skin disease. Sp. gr. varied between 1008 to 1020, average 1015.

VIII. A typical case of arterial hypermyotrophy (associated as usual during life with postural vertigo) without any notable medial degeneration or other arterial disease. Marked cardiac degeneration. Death from an intercurrent malady (epidemic skin disease).

Case 55.

I. George G—, male, aged 70, admitted November 19th, 1890, for paraplegia; died September 2nd, 1891, of epidemic skin disease.

II. Dyspnœa and vertigo for some years. First severe attack of giddiness when in the infirmary in 1887; frequent afterwards. In June, 1890, felt "faint and sick" each morning on rising.

III. Long-standing history of probable lithuria. Temperate. No known history of gout or syphilis. Shoemaker.

IV. Larger arteries *dilated*, and many presented a notable increase in adventitia. *Media* of all medium, small, and micro arteries increased (average $\frac{4}{2\cdot5}$); cloudy and slight granular changes in arteries

of lower limbs where the hypermyotrophy was most marked. *Adventitia* of medium and small arteries not much altered. A notable increase in larger ones (*e.g.* brachial $\frac{4}{2}$). Splenic, renal, and pulmonary arterioles presented a good deal of periarterial fibrosis, combined with hypermyotrophy (these organs healthy otherwise).

Intima not much altered. Slight *atheroma* in usual places in aorta and popliteal. *Radial* $\frac{3{\cdot}52}{2{\cdot}2}$, $\frac{0{\cdot}44}{0{\cdot}27}$, $\frac{0{\cdot}22}{0{\cdot}22}$, $\frac{0{\cdot}14}{0{\cdot}11}$.

V. Some atheroma in larger vessels of brain, none in smaller ones. Media of cerebral arteries a shade thicker than normal (average $\frac{1{\cdot}9}{1{\cdot}7}$), not degenerated.

VI. Heart 14 ozs. Left ventricle hypertrophied, not dilated. *Microscopically.*—Muscle natural, pericardium rough and in places adherent.

VII. *Kidneys.*—Right 3½ ozs.; left 3½ ozs. Arterioles somewhat patent, otherwise healthy Capsule strips easily. Macro- and microscopically normal. Always free from albumen, sp. gr. 1020 and 1025. Passed lithates frequently when in the infirmary in July, 1887 and 1890.

VIII. Arterial hypermyotrophy relatively unmixed with degeneration or with other arterial disease; adequate cardiac compensation without degeneration associated, as in the last case, with a long history of postural vertigo. Death from epidemic skin disease.

Case 56.

I. William B—, male, aged 73 years, admitted April 25th, 1887, for senile vertigo, died Sept. 14th, 1891, of syncope. (Illustrated in Fig. 78, and referred to in the text.)

II. Since the age of 59 years he had complained of vertigo ("things appear to move like when one is in a railway train.") On admission in 1887 he was noted as having a hypertrophied and dilated left ventricle with a murmur of dilatation. The giddiness was worse in the morning on rising or whenever he stooped. It was greatly relieved by nitro-glycerine. Was under observation 4½ years. In 1890–1 he had some severe syncopal attacks. July, 1891, contracted the epidemic skin disease, developing a markedly purpuric or hæmorrhagic condition in the skin. Recovered, but died in September of a severe syncopal attack.

III. No history of gout, rheumatism or syphilis. Always healthy. Urine thick on standing from time to time for many years.

IV. *Media* of all the medium and small arteries increased to an average of about $\frac{3{\cdot}8}{2{\cdot}5}$. Considerable dilatation and tortuosity of these and of the larger arteries (average lumen $\frac{27}{20}$). Diffuse granular changes everywhere, and in places focal necrotic changes, especially in arteries of lower extremities. *Adventitia* condensed. Moderate *intimal* sclerosis in some of the arteries of the lower extremities. Slight atheroma in big vessels, none elsewhere. *Radial* $\frac{3.08}{2{\cdot}2}$, $\frac{0{\cdot}44}{0{\cdot}27}$, $\frac{0{\cdot}22}{0{\cdot}22}$, $\frac{0{\cdot}11}{0{\cdot}11}$.

V. Media of cerebral arteries in this case thickened, slightly degenerated, and lumen markedly dilated (a conservative process, perhaps). Thus, basilar—lumen $\frac{37}{26}$, media $\frac{3}{2}$. Middle cerebral—lumen $\frac{32}{21}$, media $\frac{3{\cdot}5}{1{\cdot}7}$. No atheroma.

VI. Heart 19 ozs. Left ventricle and auricle dilated. Wall hypertrophied; thick layer of fat on surface. Muscle friable. Valves healthy. Aortic arch atheromatous. *Microscopically.*—Brown induration of muscle, *i.e.* pigmentary changes with slight fibrosis. Coronaries healthy.

VII. *Kidneys.*—Right, $4\frac{1}{2}$ ozs.; left, 5 ozs. Arterioles patent. Cortex not atrophic. Capsule non-adherent. Unusually healthy for age. No evidence of fibrosis. Urine frequently examined; sp. gr. 1017. Never albumen till skin disease appeared; then sp. gr. 1028–31, with trace of albumen.

VIII. A well-marked case of arterial hypermyotrophy associated with cardiac hypertrophy, producing "senile" vertigo, especially on postural alterations. Subsequent degeneration in the muscular tissue of both heart and arteries, with marked dilatation of both. Cerebral and other vessels remarkably free from atheroma for his age. Death from syncope.

Case 57.

I. Sophia W—, female, aged 82 years, admitted May, 1887, for "cardiac asthma" and vertigo, died October 4th, 1891, of epidemic skin disease.

II. Had suffered for many years prior to 1887 from occasional attacks of breathlessness, supposed to be "asthmatic," and of giddiness, at first once or twice a year for a few weeks at a time, latterly more frequently. No physical signs in lungs on admission. A systolic

murmur at the apex appeared July, 1890 (when dilatation presumably began). Arteries very thickened and tortuous. Pulse showed senile character of virtual tension.

III. Prolonged history of lithates in the urine. No history of actual gout, syphilis, or alcoholic excess.

IV. Moderate *hypermyotrophy*, an average of $\frac{17}{10}$, of all the medium and small arteries; calibre approximately normal. Larger arteries dilated. Granular degeneration in the media and in places necrotic foci, most marked in the lower limbs. *Adventitial* sclerosis marked. *Intimal* sclerosis marked in the lower limbs and arteries of the kidneys.

Radial $\frac{1{\cdot}98}{2{\cdot}2}$, $\frac{0{\cdot}55}{0{\cdot}27}$, $\frac{0{\cdot}33}{0{\cdot}22}$, $\frac{0{\cdot}22}{0{\cdot}11}$.

V. No atheroma in cerebral vessels, excepting some of the smaller branches. Muscular coat healthy, measurement about $\frac{1}{25}$ more than normal. Basilar dilated. Brain substance normal.

VI. Heart 14½ ozs. Wall of left ventricle hypertrophied, and only slightly dilated. Right ventricle dilated. Valves normal. Muscular fibres extensively replaced by fibrosis.

VII. *Kidneys.*—Right, 5 ozs.; left, 4½ ozs. Substance very healthy both macro- and microscopically. Senile interstitial increase hardly marked at all. Urine frequently tested during four years; always normal; sp. gr. average 1016, until during skin disease, when traces of albumen appeared.

VIII. A case of moderate arterial hypermyotrophy followed by conservative dilatation of the larger vessels and intimal sclerosis, and fibrosis of the heart (with cardiac asthma), giving rise to the phenomena of senile decay. Death from an intercurrent malady, epidemic skin disease.

Group B.—13 Cases of Arterial Hypermyotrophy complicated by other Arterial Disease and Degeneration. Cases 58–70.

Case 58.

I. Richard S—, male, aged 82 years, admitted May 8th, 1888, vertiginous attacks, died June 1st, 1890, of cerebral softening (senile decay).

II. Gradual failure of mental and bodily power for thirteen years. For some years frequent attacks of giddiness, in which "his senses go away from him" while at work; occasionally fell down in these. Breathlessness latterly. Arteries described as rigid tubes. Pulse high tension till about the last four months of life. On May 16th,

1888, an attack of mental confusion followed by hemianæsthesia without paralysis ('Brain,' 1891). Recovered in two months. Two subsequent similar cerebral attacks in December, 1888, and January, 1890. Developed bedsores and cystitis, which proved fatal.

III. A locksmith. Very abstemious. Wife thinks the urine often got thick on standing in former years. No history of gout, rheumatism, or syphilis.

IV. Considerable dilatation of all arteries. *Media* only slightly increased, but marked degeneration of various kinds, in medium and small arteries. Media of the visceral arterioles much increased. Some *adventitial* sclerosis. *Intimal* sclerosis marked, especially in the lower limbs and in the arteries of the kidney. A good deal of *atheroma* in the larger vessels and many smaller ones, especially in the brain.

Radial $\frac{3{\cdot}74}{2{\cdot}2}$, $\frac{0{\cdot}68}{0{\cdot}27}$, $\frac{0{\cdot}33}{0{\cdot}22}$, $\frac{0{\cdot}22}{0{\cdot}11}$.

V. Cerebral arteries very atheromatous, with aneurysmal dilatation between the patches of atheroma. No obvious hypermyotrophy, but degenerated media. Large softening localised in gyrus fornicatus and numerous smaller ones elsewhere.

VI. Heart 10½ ozs. Marked hypertrophy of left ventricle, ⅞ inch thick; muscle firm. Valves normal. Aorta atheromatous. *Microscopically.*—Marked interstitial fibrosis in places, especially around some arteries. Granular degeneration of muscular fibres.

VII. *Kidneys.*—Right, 4 ozs.; left, 5½ ozs. Arterioles remain patent. Condition quite normal for age. *Microscopically.*—Senile condition as regards interstitial tissue. Glomeruli not atrophied. Arterioles thickened; both media and intima thickened; minute extravasations of red blood-cells here and there. Once, after a chill, faint trace of albumen (May 23rd, 1888), but sp. gr. 1018. At other times during 1888 and January to June, 1890, normal. Sp. gr. 1014–1021. During last few weeks it was ammoniacal and contained pus.

VIII. A case of arterial sclerosis which probably originated as hypermyotrophy (judging from the arterioles of the kidneys and other organs); medial degeneration very marked; intimal sclerosis also marked (probably compensatory of dilatation); and a good deal of atheroma, especially in the brain; in an aged person who died with multiple cerebral softenings.

Case 59.

I. John H—, male, aged 76 years, admitted January 31st, 1890, for hemiplegia. Died October 4th, 1890, of asthenia.

II. Progressive loss of mental and physical vigour for ten to fifteen

years or more. Attacks of "giddiness" for several years. On admission, heart-sounds scarcely audible. Arteries thick and tortuous; pulse slow (56) and irregular; tracing shows square-top character of "senile pulse"—virtual tension (Broadbent). Left hemiplegia (due to localised thrombosis) supervened suddenly, in June, 1889; partial recovery; ultimate death from asthenia, which set in somewhat suddenly, June, 1890.

III. Many attacks of gout since age of 36. History of lithates in urine from time to time all his life. Long history of alcoholic excess. Syphilis at 17.

IV. Irregular fusiform *dilatation* of all the arteries. *Media* thickened in places, but degenerate and much encroached upon by *atheroma* and by *intimal* sclerosis, particularly in the dilated parts. Thus, in the brachial in one place lumen normal, media $\frac{3\cdot3}{3\cdot0}$, intima $\frac{1\cdot7}{1}$; in another place lumen dilated $\frac{14}{10}$, media $\frac{2\cdot3}{3\cdot0}$, intima $\frac{3}{1}$. In the lower extremities lumen considerably diminished by intimal sclerosis. *Radial* section in one place $\frac{2\cdot65}{2\cdot2}$, $\frac{0\cdot27}{0\cdot27}$, $\frac{0\cdot22}{0\cdot22}$, $\frac{0\cdot27}{0\cdot11}$, and in another place $\frac{2\cdot1}{2\cdot2}$, $\frac{0\cdot44}{0\cdot27}$, $\frac{0\cdot22}{0\cdot22}$, $\frac{0\cdot22}{0\cdot11}$.

V. Extensive atheroma of cerebral vessels, which are irregularly dilated and tortuous. Old softenings in internal capsule and elsewhere

VI. Heart 12 ozs. Left ventricle increased, but muscle friable. Slight dilatation. Valves and aorta rather atheromatous, but no incompetence or stenosis. *Microscopically.*—Granular condition of muscle-fibres; pigmentary degeneration and fatty degeneration commencing in places. Coronary arteries thickened and dilated.

VII. *Kidneys.*—Right, 6 ozs.; left, 6½ ozs. Congested substance. Capsule strips readily. *Microscopically.*—Congestion, but no notable increase in interstitial tissue or other microscopic change. Repeated examinations; sp. gr. average 1016; no albumen; excess of lithates from time to time.

VIII. A case of mixed arterial sclerosis, probably originating as arterial hypermyotrophy (evidences of which still existed), but at the time of death, at the age of 76, found to be much mixed with intimal sclerosis and atheroma, both of systemic and cerebral arteries, and with arterial dilatation; cardiac hypertrophy (also associated with degeneration at the time of death); localised cerebral softenings; death by asthenia (senile decay). Long history of gout and alcohol. Kidneys normal.

Case 60.

I. Mary N—, female, aged 76 years, admitted January 1st, 1891, for uræmic coma. Died same day.

II. Lived in the workhouse, and said to have been in her usual health until the day of her death. No particulars obtainable excepting that she was subject to "swimmings" in the head.

III. No information.

IV. *Lumen* of larger and medium arteries dilated. *Media* of medium, small, and micro-arteries twice normal thickness. Granular degeneration. Slight *adventitial* sclerosis. Marked generalised *intimal* sclerosis, especially in larger and medium arteries, and in the micro-arteries of the kidneys. Atheroma in all the larger systemic and in the cerebral arteries. *Radial* $\frac{3{\cdot}30 \quad 0{\cdot}71 \quad 0{\cdot}33 \quad 0{\cdot}16}{2{\cdot}20' \quad 0{\cdot}27' \quad 0{\cdot}22' \quad 0{\cdot}11'}$

V. Extensive atheroma of the cerebral arteries. No cerebral lesions.

VI. Heart $16\frac{1}{2}$ ozs. Valves normal. Left ventricle $\frac{7}{8}$ in. thick, not dilated; substance flabby. Right ventricle dilated and hypertrophied. *Microscopically.*—Fibres healthy except for pigmentary change and commencing fibrosis around vessels.

VII. *Kidneys.*—Right, $2\frac{1}{2}$ ozs.; left, $2\frac{1}{4}$ ozs. Typical contracted granular kidneys naked-eye and microscopically. Crystal of urate on surface. Arterioles patent, media and intima thickened. No urine obtained during life.

VIII. A case of granular contracted kidney with cardio-arterial hypermyotrophy; dilatation of larger vessels; degeneration of the media. Extensive cerebral atheroma, but no consequences thereof in the brain. Death by uræmia.

Case 61.

John G—, male, aged 74 years, admitted February, 1886, for chronic gouty arthritis. Died June 30th, 1891, of strangulated hernia.

II. During five years in infirmary suffered from attacks of vertigo and breathlessness, at first rarely, later frequently. A note of this kind frequently occurs: "October 8th, 1888.—Giddiness, great exhaustion, and breathlessness on least exertion; pulse compressible, arteries thick; great benefit from nitroglycerine $\mathfrak{m}\frac{1}{100}$ quartis horis." Two faints and two attacks of epistaxis in 1889; petechial eruption August, 1890, which before death covered the body, and large subcutaneous hæmorrhages (resembling scurvy) also occurred then.

III. Attacks of acute and chronic gout and gouty arthritis for twenty-five years. Had frequently passed "gravel." No alcoholic excesses. No history of syphilis.

IV. Widespread dilatation of lumen of larger and medium arteries, some measuring twice the normal, and very tortuous. *Media* much increased, even in dilated arteries and arterioles. Advanced granular degeneration. Moderate *adventitial* and *intimal* sclerosis. Atheroma of larger systemic and of cerebral arteries. *Radial* $\frac{4{\cdot}73}{2{\cdot}20}$, $\frac{0{\cdot}36}{0{\cdot}27}$, $\frac{0{\cdot}27}{0{\cdot}22}$, $\frac{0{\cdot}11}{0{\cdot}11}$.

V. Marked atheroma of arteries, but no circulatory lesions in brain.

VI. Heart 17 ozs. Some fatty infiltration. Left ventricle hypertrophied; somewhat dilated, $\frac{5}{8}$ to $\frac{6}{8}$ inch. Valves normal. *Microscopically.*—Muscle, brown atrophy, and in places slight fibrosis.

VII. *Kidneys.*—Right, $2\frac{1}{2}$ ozs.; left, $2\frac{1}{2}$ ozs. Typical granular kidney, arteries stand out. *Microscopically.*—Marked increase of interstitial tissue. Thickening of intima, and to a less extent of the media. In earlier days of residence in infirmary urine normal and good sp. gr.; but from October, 1886, to January, 1891, it showed a trace of albumen, and the sp. gr. varied between 1006 and 1014.

VIII. Granular contracted kidney, arterial hypermyotrophy with advanced medial degeneration and dilatation, and considerable cardiac hypertrophy. Purpura and other hæmorrhagic consequences, but no cerebral hæmorrhage or thrombosis in spite of cerebral atheroma. Death from strangulated hernia.

Case 62.

I. Ann G—, female, aged 74, admitted March 29th, 1888, for chronic bronchitis. Died April 16th, 1891, of acute lobar pneumonia.

II. Attacks of "weakness" in head of late years. Noted March 29th, 1888: "Heart no definite murmur, but first sound at apex ill-defined and prolonged; second sound hardly audible. Arteries very tortuous. Subject to fainting fits."

III. No information.

IV. On naked-eye examination arteries remained patent and media was inelastic and protruding from between other coats. Several sections of the radial showed some degeneration of the *media.* No microscopic measurements made. Some atheroma of aorta and big arteries, none of the other arteries or cerebral vessels. Radial not measured.

V. Normal to naked-eye examination. No atheroma.

VI. Heart $9\frac{1}{2}$ ozs. Patient a very small woman. Left ventricle dilated, muscle pale, flabby, and moderately tough. Right ventricle dilated. *Microscopically.*—Muscular fibres atrophied and replaced by fibrous tissue (fibroid degeneration).

VII. *Kidneys.*—Right, $3\frac{1}{2}$ ozs.; left, 5 ozs. Capsule stripped

readily. Cortex not diminished. Vessels patent. No fibrosis. March, 1888: urine 1025, lithates, no albumen. December, 1890: 1024, clear, acid, no albumen.

VIII. Moderate arterial hypermyotrophy without much cardiac hypertrophy, but marked fibroid degeneration of the heart muscle. No renal disease. Death by acute pneumonia.

Case 63.

I. John C—, male, aged 61 years, admitted April 23rd, 1891, for phthisis and thrombosis of femoral vein; died next day. Old cicatrix in brain.

II. Failing bodily health for "years." Dizziness from time to time since aged 50, more frequent of late; had also breathlessness, but date of its commencement unknown. At age of 53 had an attack of hemiplegia from which he recovered. Phthisis said to have begun nine weeks before admission. Thrombosis of femoral vein a few days before admission. Admitted in a state of collapse, with cardiac action very feeble.

III. Formerly a bootmaker. No other information.

IV. Larger and median arteries *dilated*, especially the larger arteries. Medium and smaller arteries tortuous and hardly more than normal calibre. Thickening of tunica *media* of all vessels, very marked in medium and smaller vessels. Cloudy and moderate granular degeneration in lower limbs. *Adventitia* of larger and medium arteries thickened. *Intima* normal. No atheroma anywhere.

V. Old apoplectic cicatrix in left internal capsule of eight years' standing. Cerebral arteries quite free from atheroma. No discoverable change in the media.

VI. Heart 12½ ozs. Muscular substance friable. Both cavities dilated. Valves healthy. *Microscopically.*—Marked fatty infiltration at time of death.

VII. *Kidneys.*—Right, 4½ ozs; left, 4½ ozs. Capsule strips readily. Kidneys very healthy. Arterioles a trifle thickened. *Microscopically.*—No interstitial increase. Glomeruli and epithelium healthy. Urine reported as "normal."

VIII. Arterial hypermyotrophy and cardiac hypertrophy followed, at the age of 53, by a limited cerebral hæmorrhage; recovery. Subsequent cardio-arterial degeneration and dilatation; death from pulmonary tuberculosis and thrombosis of the femoral vein at the age of 61.

Case 64.

I. Jesse C—, male, aged 74 years, admitted May 21st, 1891, for

moist gangrene of both legs; died May 23rd, 1891, of gangrene and cardiac failure.

II. Failing strength six or eight years. Frequent attacks of breathlessness for three or four years; no information as to vertigo. Heart beat and pulse extremely feeble. Apex beat one inch outside nipple line; pulse 120, dicrotic. Moist gangrene of both legs (right one sloughing due to thrombosis in the popliteal veins).

III. No history of alcohol. Syphilis? No history of gout. Cow-keeper.

IV. All the systemic arteries thickened and tortuous, and calibre considerably dilated. *Media* of all arteries increased, showing advanced granular degeneration. *Adventitia* everywhere condensed and increased. Widespread *intimal* sclerosis. Slight atheroma of aorta, not of the arteries of brain or elsewhere. Radial not measured.

V. Cerebral arteries free from atheroma but much dilated. No evidences of old circulatory accidents.

VI. Heart 16 ozs.; adherent pericardium. Both ventricles much dilated. Walls much thicker than normal, but soft and friable. Valves normal. *Microscopically.*—Muscle-fibres swollen; fatty infiltration and degeneration in places.

VII. Each kidney weighs 8 ozs. Much congested. Capsule strips easily. Substance soft. Cortex not diminished. No fibrosis. Epithelium slightly granular. Urine retained; 2½ pints twice drawn off; contained blood and therefore faint trace of albumen; sp. gr. 1016, otherwise normal. Case of hæmorrhage from prostate.

VIII. Probably a case of arterial hypermyotrophy in its origin, followed by extreme degeneration of the muscular tissue in both heart and arteries, complicated by adherent pericardium. Death by cardiac degeneration and gangrene.

Case 65.

I. Eliza G—, female, aged 80 years, admitted April 25th, 1891, for "senile decay"; died August 8th, 1891, of asthenia, complicated by cerebral pachymeningitis and granular kidney.

II. Progressive feebleness of mind and body extending over 25 years. For several years subject to occasional falls and dizziness, and dyspnœa on very slight exertion. Described on admission as a "healthy-looking but feeble old lady without paralysis anywhere." Senile dementia supervened latterly.

III. No history of any illness or alcoholic excess. No information on other points.

IV. Tunica *media* of medium and small arteries thickened and degenerated. Larger vessels much dilated and somewhat atheromatous

in places. Universal *intimal* sclerosis most marked in the lower limbs.

Radial $\frac{2{\cdot}75}{2{\cdot}2}$, $\frac{0{\cdot}47}{0{\cdot}27}$, $\frac{0{\cdot}27}{0{\cdot}22}$, $\frac{0{\cdot}14}{0{\cdot}11}$.

V. Cerebral arteries slightly atheromatous in places. Media not degenerated. Lumen dilated. Very marked cerebral pachymeningitis (meninges $\frac{1}{8}$–$\frac{1}{4}$ inch thick) over vertex.

VI. Heart 10 ozs. Left ventricle barely $\frac{3}{8}$ in. thick; rest is fat outside muscle. Dilatation, soft, flabby, and fatty *Microscopically.*—Advanced fatty infiltration. Coronary arteries much thickened and very slightly atheromatous.

VII. *Kidneys.*—Right, $2\frac{1}{2}$ ozs.; left, 3 ozs. Capsule thickened and adherent. Cortex diminished. Vessels patent. *Microscopically.*—Interstitial tissue, slight increase; epithelium and glomeruli atrophied and in places absent (granular kidney). Urine clear, pale, acid, copious; sp. gr. 1008–1018; no sugar; twice albumen; latterly retention followed by incontinence.

VIII. A case which probably originated as one of arterial hypermyotrophy associated with granular kidney, followed by marked muscular degeneration of heart and arteries and complicated by pachymeningitis. Death at the age of 80 of progressive asthenia.

Case 66.

I. John P—, aged 70 years, admitted June 17th, 1891, for gout and chronic Bright's disease, died August 13th, 1891, of pulmonary tuberculosis.

II. Progressive weakness for many years. Used to have dizziness; of late years, faint feelings. Cardiac sounds very feeble; apex not localisable. Pulse very soft and rapid at times. No signs discovered in lungs during life, but shortly before death coughed up a large quantity of pus.

III. A painter. Long history of gout.

IV. *Media* throughout the arterial system moderately thickened; considerably degenerated; associated with dilatation and tortuosity, most marked in the larger vessels. Slight atheroma in the usual places, namely, aortic arch and bifurcation of aorta. None elsewhere.

Radial $\frac{3{\cdot}35}{2{\cdot}20}$, $\frac{0{\cdot}55}{0{\cdot}27}$, $\frac{0{\cdot}25}{0{\cdot}22}$, $\frac{0{\cdot}08}{0{\cdot}11}$.

V. Cerebral vessels. No atheroma. Media healthy.

VI. Heart $9\frac{1}{2}$ ozs. Left ventricle thin and dilated, $\frac{1}{8}$ inch thick at apex. Substance soft. Valves normal. *Microscopically.*—Perivascular fibrosis, muscle-fibres very granular, with fat between.

VII. *Kidneys.*—Right, 4 ozs.; left, $2\frac{1}{2}$ ozs.; contain crystals.

Cortex diminished. Capsule trifle thickened and adherent. *Microscopically.*—Moderate increase in fibrous stroma. Glomeruli shrunken and capsules thickened. *Lungs* riddled with abscesses. Urine, always a trace of albumen, sp. gr. 1010–1016.

VIII. A case of contracted granular kidney associated with medial thickening and degeneration and inadequate cardiac compensation (heart dilated, degenerated). Death from pulmonary tuberculosis.

Case 67.

I. Harriet T—, female, aged 81 years, admitted July 15th, 1889, for right hemiplegia; died, October 17th, 1891, of epidemic skin disease.

II. Used to "come over dizzy" for some years. Heart's action feeble, radials thickened, dilated and tortuous. After admission fell in several of her giddy attacks, but was never unconscious. Had several recurrences of hemiparesis in 1889 and 1890. Contracted the epidemic skin disease in the infirmary and died.

III. Abstemious. Severe attacks of "indigestion" all her life.

IV. Larger and medium arteries somewhat dilated and tortuous, but lumen often diminished by intimal disease (see below). Tunica *media* increased to an average of about $\frac{3}{2\cdot\bar{5}}$, but a good deal encroached on in places by dense fibro-plastic intimal sclerosis, more especially in the lower extremities. Media showed granular degeneration, and in places necrotic foci in the lower extremities. *Adventitia* slightly increased. Perivascular fibrosis of organs. *Intimal sclerosis* was almost universal and was marked in the arteries of the lower extremities. Widespread *atheroma*, in some places almost obliterating the lumen (*e.g.* in the anterior tibial, Figs. 70, 71) in the lower extremities, but not attended by embolic or thrombotic consequences here.

Radial $\frac{3\cdot35}{2\cdot\bar{2}0}$, $\frac{0\cdot55}{\bar{0}\cdot\bar{2}7}$, $\frac{0\cdot22}{0\cdot22}$, $\frac{0\cdot05}{\bar{0}\cdot\bar{1}1}$.

V. Cerebral arteries, both large and small, the seat of patchy atheroma; *numerous fusiform dilatations between. Media,* marked granular degeneration. Numerous localised softenings, old and recent and general atrophy of the cortex of the brain.

VI. Heart 11 ozs. Left ventricular wall thickened, but very degenerated and fatty. Hypertrophy with dilatation. *Microscopically.*—Some interstitial perivascular fibrosis.

VII. *Kidneys.*—Right, 2½ ozs.; left, 3 ozs. Capsule thin, readily strips. Surface smooth. No disproportion of cortex to medulla. Vessels remain patent. *Microscopically.*—Quite normal for age. Trace of albumen on admission; none subsequently during two years under observation. Sp. gr. always good.

VIII. Widespread intimal sclerosis (so-called obliterative fibrous endo-arteritis) was the leading feature of this case, associated with a certain degree of medial thickening and medial degeneration. There was marked patchy atheroma of the cerebral arteries, and scattered patches elsewhere. The systemic intimal sclerosis threw a strain upon the arteries of the brain and led to dilatation between the atheromatous patches and numerous small circulatory accidents in the brain. Death at the age of 81 from an intercurrent disorder, epidemic skin disease.

Case 68.

I. Elizabeth M—, female, aged 70 years, admitted May 30th, 1890, for ulcer of leg, died October 24th, 1891, of asthenia after epidemic skin disease.

II. Weakness for indefinite period. Frequent swimming in the head, and once (May 16th, 1890) followed by a fall. Various paralyses from localised cerebral lesions. On admission pulse small (av. 90, regular). Arteries thickened and tortuous. Coldness of extremities at times on assuming the erect posture.

III. Very moderate drinker. Lithates in excess while in infirmary, and (?) previously.

IV. Lumen of vessels appeared to be normal because where dilatation has taken place the lumen is reduced by intimal sclerosis. Tunica *media* of all the systemic arteries increased and degenerated. *Adventitia* condensed, but not much increased. Widespread *intimal* sclerosis, especially in the lower limbs and in some of the larger arteries. In the femoral, for instance, the intima averages $\frac{30}{1}$. Patchy atheroma in the large vessels. *Radial* $\begin{matrix} 2{\cdot}75 & 0{\cdot}44 & 0{\cdot}22 & 0{\cdot}11 \\ 2{\cdot}20' & 0{\cdot}27' & \overline{0{\cdot}22}' & 0{\cdot}11' \end{matrix}$

V. *Cerebral arteries.*—Media thinned and somewhat degenerated. Marked atheroma even to the smallest ramifications, dilated between the patches. Numerous small localised hæmorrhages and cicatrices of indefinite duration.

VI. Heart 11 ozs. Left ventricle hypertrophied and rather dilated. Valves normal. *Microscopically.*—Commencing fibrosis. Muscle-cells granular. Coronary arteries much thickened by fibrous endarteritis. Patient and all her organs were small.

VII. *Kidneys.*—Right, 2½ ozs.; left, 3½ ozs. Fibrosis; granular kidney. Eighteen months under observation. Occasional trace of albumen, and low sp. gr. Occasional excess of lithates.

VIII. A case of contracted granular kidney, moderate cardio-arterial hypermyotrophy, marked intimal sclerosis and atheroma.

Numerous cerebral circulatory accidents (compare remarks on Case 67). Death from asthenia after epidemic skin disease.

Case 69.

I. James A—, aged 76 years, admitted April 20th, 1890, for vertigo and syncopal attacks; died December 8th, 1891, of acute lobar pneumonia.

II. Attacks of giddiness and fainting (sometimes "went quite off") for some years; at first separated by long intervals, latterly more frequent. October, 1890, heart hypertrophied. Respiration often noted as "sighing." Pulse tension high. November, 1891. heart dilated, sounds irregular and very weak. Pulse 132, small, weak, irregular.

III. Gastric derangement from time to time. No alcohol, syphilis or gout.

IV. Larger vessels dilated and the seat of chronic fibrous endarteritis (intimal sclerosis); medium and smaller vessels, same changes to a less extent. *Media* thickened throughout the arterial system and degenerated, granular in some places, necrotic in others. Microscopic arteries not so much hypertrophied as the medium-sized vessels.

Radial $\frac{2{\cdot}31}{2{\cdot}\overline{20}}$, $\frac{0{\cdot}66}{\overline{0{\cdot}27}}$, $\frac{0{\cdot}38}{\overline{0{\cdot}22}}$, $\frac{0{\cdot}14}{\overline{0{\cdot}11}}$.

V. Cerebral arteries remarkably healthy. No softenings or hæmorrhages.

VI. Heart 13½ ozs., hypertrophied and dilated. Friable. Valves normal. *Microscopically.*—Muscle-fibres granular, healthy otherwise.

VII. *Kidneys.*—Right, 4 ozs.; left, 5½ ozs. No disproportion of cortex. Capsule neither thickened nor adherent. *Microscopically.*—Healthy. Under observation for 1¾ years, but no albumen. Sp. gr., average 1013–1016. Trace of albumen towards the end.

VIII. Cardio-arterial hypermyotrophy, associated with intimal sclerosis; subsequent degenerative changes in the media of the systemic arteries. Media and intima of cerebral arteries healthy. No cerebral lesions; no renal disease. Senile vertigo; syncopal attacks. Death by lobar pneumonia.

Case 70.

I. William J—, male, aged 75 years, admitted September 21st, 1890, for vertigo and debility; died December 18th, 1891, of asthenia.

II. First admitted in 1889 with a long previous history of "giddy faints." These fainting sensations were a prominent feature of the case, and latterly would come on when he was lying still in bed. September, 1890, pulse feeble, senile characters, 80. Fainting sensa-

tions and sometimes cyanosis of the extremities on any postural alteration. July, 1891, epidemic skin disease; recovered, but died of weakness in December.

III. No information. Said to be always healthy.

IV. Hypermyotrophy of all the medium and small arteries, average increase $\frac{4{\cdot}5}{2{\cdot}5}$. Moderate granular degeneration in the *media* in the arteries of the lower limbs, only cloudy changes in the upper. Larger arteries considerably dilated; medium and small vessels also dilated, (average $\frac{27}{20}$). *Intima* slightly thickened. *Atheroma* in the larger vessels.

Periarterial fibrosis in organs. *Radial* $\frac{2{\cdot}97}{2{\cdot}20}$, $\frac{0{\cdot}60}{0{\cdot}27}$, $\frac{0{\cdot}22}{0{\cdot}22}$, $\frac{0{\cdot}22}{0{\cdot}11}$.

V. Cerebral arteries unusually healthy; no hypermyotrophy or degeneration. Slight atheroma in larger arteries.

VI. Heart 14 ozs.; hypertrophied $\frac{3}{4}$ inch, very flabby. Muscle granular. Valves normal. *Microscopically.*—Very early stage of radiating sclerosis (periarterial fibrosis).

VII. *Kidneys.*—Right, 3 ozs.; left, 2 ozs. Capsule not adherent. No disproportion between cortex and medulla. Arterioles patent. *Microscopically.*—Normal. Urine: Numerous examinations. September, 1890, to May, 1891, clear, pale, acid: sp. gr., average 1016; no albumen. May to December, 1891, deposit of lithates; sp. gr., average 1021; no albumen, except August, 1891, during skin disease.

VIII. Arterial hypermyotrophy with adequate and not excessive cardiac compensation. Larger arteries dilated. Subsequent degeneration of muscular tissue most advanced in heart, hence the fainting sensations, and death by progressive cardiac failure. No cerebral circulatory complications.

DISCUSSION.

Professor Allbutt.

At the time of the discussion between Gull and Sutton on the one hand, and George Johnson on the other, I had the opportunity of seeing the preparations of both disputants and of personal explanations with them, as Dr. John Ogle had asked me to write a summary of the argument for the 'Medico-Chirurgical Review.' Although for many reasons I was attracted by the interpretations of Gull and Sutton, yet I was so much impressed by the demonstrations of George Johnson that I was never able to dismiss the evidence of

arterial hypertrophy from my mind. This evidence fell into some neglect, partly, perhaps, on account of Johnson's dubious logic; it was, therefore, of great interest to me to read Dr. Savill's observations, which tended to restore this evidence in greater strength to the field of pathology. The observations of Gull and Sutton and of Johnson also (although I think that this criticism applies to Gull and Sutton chiefly because their researches were much wider) were inconclusive because of the fallibility of the histological methods then in use. In this respect Dr. Savill has advantages which his predecessors had not. Of late years I have lost some touch with histological methods; but as from the clinical side I was much in want of such investigations as these of Dr. Savill, I put myself at once in communication with him. I was in want of such support for the full explanation of certain clinical observations which had occupied me since the year 1875. About this date it was that I began to follow the course of a case—since published in abstract more than once—in which first I perceived that in a certain class of cases of "arterio-sclerosis" this process owes its origin to a gradual and persistent rise in blood-pressure. I must plead the indulgence of the Society if once more I summarise the results to which clinical observation had led me, results often published already. Summarily they are these (excluding all cases of chronic Bright's disease, with which at this time it is impossible to deal)—that arterio-sclerosis is met with clinically in three forms, forms if superficially alike, yet very different in nature and causation. These three are:

(*a*) Toxic (that is, the effect of lead, of certain of the infective diseases, such as syphilis, etc., of diabetes, and so forth).

(*b*) Involutionary (that is, senile decay)—a change which may appear before the terms of the Psalmist.

(*c*) Secondary, the effect of arterial hyperpiesis—the form in which the muscular coat of the arteries is hypertrophied.

The forms (*a*) and (*b*) are not necessarily attended by rise of arterial pressures, but (*c*) essentially depends on hyperpiesis for its initiation. At the time of speaking there is a case of diabetes in the Addenbrooke's Hospital in a girl aged 14 in whom there is general arterial disease; but the arterial pressure is rather below normal than above it. In syphilitic arterial disease

again, hyperpiesis, if present at all—and it is commonly absent—is but incidental.

Cases of the involutionary class, (*b*), in which, again, widespread arterial disease with great deformation is found without hyperpiesis and without hypertrophy, are to be found in numbers in workhouses and in private practice. Such persons often attain great ages, and are wont to die, not of cerebral hæmorrhage, but of the atrophies which ensue upon vascular thromboses and obliterations. Forms (*b*) and (*c*) may concur in the same patient, but this is not the rule. In the involutionary cases calcification is more prone to occur, and the disease is more disposed to attack all the coats of an artery than in hyperpiesis. In form (*b*), again, the heart, as we should expect, is not hypertrophied or dilated, or only in the slighter degrees; it is often in fairly good working order, and death does not depend upon strain of the heart.

In many aged persons, especially in those who inherit length of years, the involutionary form of arterial disease does not appear; and as its causes are unknown, prevention or retardation of the process is not specifically within our powers. Fortunately, many of the patients in whom it appears live to extreme age, without serious loss of the conversation and amenities of life; defect of endurance of bodily and mental work may be their chief or only complaint.

It is on Class (*c*) that the discussion of this evening will mainly turn, and this story is a very different one. I believe that for many years I stood alone in teaching that in the cases of this class the first apparent factor is a rise of arterial pressure, and that the arterial disease is a mechanical consequence of the sustained hyperpiesis, instead of the converse, as is generally believed. I say, the first apparent factor: but this factor probably depends in its turn upon some alterations of the blood, and the alterations of the blood, again, upon some more or less specific, at any rate very common, perversion of metabolism. The chemistry of the body is perverted, the blood is altered, and whether by this alteration the fluid becomes more viscous and so traverses its channels more reluctantly, or receives some quality irritating to the vessels which by their responsive contraction hinder its flow, we cannot discuss now. Suffice it to say that for some reason the blood offers an abnormal resistance in the periphery, the pressure rises, the vessels are dilated, and

dilatation is counteracted, as it is likewise in the heart, by hypertrophy. By this means a new balance is brought about, and circulation is carried on, though with excessive expenditure in labour and plant. There is little doubt that as a more or less transitory phase this rise of pressure is common enough, and not in elderly persons only. The watchful physician will note it in young persons also, especially in boys; in mature and elderly persons, however, although often transitory, either by virtue of remedies or of the cessation of its causes, it is too often permanent. If the conditions abide, the muscular walls of the vessels deteriorate (of the intima I say nothing at present), and those of the heart, also overwrought, give way; the excessive arterial pressure which while sustained may have concealed from both patient and physician the stealthy advance of the disorder, falls to normal and below it; venous pressures rise and the signs of dissolution become rapidly manifest.

Of late years I have noticed with pleasure and no little surprise that even in old people arterial hyperpiesis may establish itself, and yet by appropriate means be permanently reduced. Five or six years ago Mr. Hartley, of Bishop Stortford, and myself observed this state of things in an eminent degree in a lady then of some eighty-five or eighty-six years, but by careful management the circulation was restored to normal conditions, and the quondam patient is now living and well at some four score years and ten. With Mr. Maund, of Newmarket, about two years ago, I observed the same excessive arterial pressures, also in a lady, still of fine physique at eighty-three years of age; this lady quickly recovered and is now in good health. In these and such cases the muscular coat of the arteries increases no doubt, but with the removal of the cause this passes away. From the later phase of arterio-sclerosis they are preserved. Unfortunately, but too often, when the patient seeks formal advice the disorder has been too long ageing for cure; the vessels are permanently stretched and spoilt. In many such cases pressure can be reduced, but if the patient's circulation has got a permanently abnormal set, medical treatment can be but a compromise. In other cases, in many of which, indeed, the damage to the arteries—so far as they are accessible—does not seem extravagant, no means avail to reduce the hyperpiesis, or if it be reduced for a passing moment, it rises again obstinately

to its excessive degrees. In such cases cerebral hæmorrhage is imminent. Of the pathogeny of Class (*c*), we know a little more than of Class (*b*). But even here the borders of our knowledge are soon reached. A sedentary life and high feeding will produce it in many persons, perhaps in most; on the other hand, I see it in not a few temperate persons. Dr. Nyle, of Cambridge, asked me a few weeks ago to see a man of some seventy years, whose arterial tree had been stretched by high arterial pressure into the state of an old glove; yet he was a man of active habits, a teetotaller of many years' standing, and so small a meat-eater that for four years past he could hardly be said to have touched it. Nevertheless, his arterial disease was certainly not of the involutionary or (*b*) type, but of the hyperpietic. That repletion relative or positive—*i.e.* tempered or untempered by air and exercise—is at the bottom of the majority of the cases is made more probable by the generally good effects of alteration and deobstruent medication. Some of these patients are gouty; most of them present no such features.

Into the symptoms of arterial hyperpiesis this is not the place to enter; but I may say that the group has definite characters, and that from my first patient in 1875 I was able to formulate a clinical type which has proved sufficient for the numerous succession of cases in my own experience.

Dr. George Oliver.

Dr. Savill has, I think, done a good service to the study of arterial wall changes in bringing prominently forward the part which the musculature of the arteries plays in disease. I am sure that that *rôle* is not fully and sufficiently recognised. Dr. Savill has here furnished us with valuable positive data, which make our clinical records on circulatory derangements and our reasonings thereon much more reliable and real. Here we have a fact that bears testimony to a corresponding clinical fact; it is the tell-tale of that fact. Guided by clinical observation, I entertain no doubt that Dr. Savill is right in attaching high importance to the *rôle* which the musculature of the arteries plays in health and in disease. It is essentially the functioning tissue of the arterial system, elasticity being its comparatively subordinate co-worker. In health, its main object is apparently

to shield the delicate capillary wall from the undue stress and strain of the high and intermittently jarring arterial pressure, its physiological intent being preservative and regulative. In disease this conservative intent assumes a much more active and pronounced form, the scattered peripheral muscular fibres becoming the antagonists, as it were, of the central bundle; and there is developed a vicious circle of interaction between the cardiac and the arterial musculatures—the latter resisting the outflow of blood and the former striving to overcome the increased peripheral resistance thus established. This is well illustrated by the state of the circulatory organs in chronic interstitial nephritis, and in chronic goutiness (quite apart from renal complication). Using the arteriometer and blood-pressure gauge, I have, for many years, been enabled to recognise this large and important group of chronic ailments, and to interpret the circulatory facts in the manner I have just indicated. But until the publication of Dr. Savill's work, the *post-mortem* evidence in support of this view has not been forthcoming. Now, we cannot regard the development of arterial hypermyotrophy as otherwise than a result. But it is a result of morbid interaction of great importance from a clinical standpoint. It is itself probably the main, if not the sole, cause of increased arterial pressure, with its inevitable strain on arterial walls and its possible eventuality, cerebral hæmorrhage. My clinical experience has frequently confirmed this connection. But that is only one of the accidents of a raised arterial pressure. The pathological interaction between the cardiac and the peripheral musculatures frequently terminates in the failure and vanquishment of the former. How frequently do we see dilatation of the ventricle (with its inevitable sequelæ) from the overmastering effect of the increased peripheral resistance, which is mainly muscular! As all these disturbing factors (the increased activity of the circulatory musculatures, the consequently raised arterial pressure, and the clinical incidents thereof) are but results, what is the underlying cause or causes?

From the data of an inquiry on which I am now engaged, I am disposed to conclude that we all have within us physiological chemical products which, when allowed to accumulate, are efficient enough of themselves to set up and to maintain all these disturbances. I shall hope to refer to this matter in the

near future, elsewhere. I take it that the main point—the kernel, as it were—of Dr. Savill's important communication is that arterial hypermyotrophy indicates the most serious form of arterial thickening. That is a position which I can support with my clinical experience, and with the clinical facts relating to circulatory disturbances which I have recorded for many years past. Over and over again I have met with thickened arteries—under whatever name we may call them, whether atheroma or arterio-sclerosis—in the elderly or in subjects past middle life, which apparently have signified very little in regard to the enjoyment of average good health, and which have not curtailed life by circulatory accidents—providing in such cases, above all things, that the arterial pressure was not permanently raised. My observations have all shown that this clinical fact separates the comparatively innocuous forms of arterial thickening from the much more important class in which the musculatures of the circulatory apparatus are involved. It has always seemed to me that in the former varieties the thickening may only involve, as a rule, the middle-sized vessels, which may be regarded as mere conduits of the blood, and does not include the small-sized arteries and the arterioles, in which the muscular tissue may be doing its normal work; and so long as the peripheral resistance is not increased, the blood-pressure remains normal; and so long as it does continue normal, life is not threatened in any way from the state of the circulation. Atheroma, too, as is well known, is apt to be patchy and local. But, on the other hand, when the musculature of the arteries is implicated, the whole of the circulatory apparatus becomes involved, and this general involvement spells risk and danger ahead.

Dr. John Broadbent.

In discussing this subject, it seems to me essential that we should take into consideration the degenerative changes in the aorta and smaller vessels known as "atheroma," as the two conditions are, etiologically and pathologically, closely allied. I do not look upon the hypertrophy of the muscular coats of the arteries and of the heart as a disease, but rather as a response on the part of the vascular system to cope with additional work imposed upon it by increased or abnormal peripheral

resistance from various causes. As a result of the high arterial tension thus induced, we, sooner or later, have evidence of disease in the degenerative changes which take place in the sub-endothelial layers of the smaller vessels, more especially those of the cerebral system, and in the wall of the aorta.

I have recently investigated some sixteen cases of cerebral hæmorrhage, which is one of the commonest accidents associated with arterio-sclerosis, examining microscopically the condition of the cerebral vessels, the aorta, the radial artery, the coronary artery of the heart, and the kidney. In two instances the subjects were eighty years of age and the hæmorrhage was due to senile degenerative changes in the vessels.

Of the remainder, seven were associated with granular kidney and seven with a type of kidney in which the most characteristic changes were thickening and hyaline degeneration of the inner coat of the vessels. The kidneys were of about normal size, the cortex not appreciably diminished, and the capsule stripped, leaving an almost smooth surface. In all these fourteen cases the heart and muscular coat of the radial artery were greatly hypertrophied, but in no instance did the latter show signs of degeneration. The cerebral vessels, on the contrary, were dilated, thin, and hyaline, or studded with small white patches, which microscopical examination showed to consist of localised thickening with degeneration of the sub-endothelial tissue, over which the muscular coat, thin and atrophied, could be traced. In four cases there was advanced atheroma of the aorta, in the remainder, slighter degenerative changes just above the aortic valves. The main clinical characteristics were high arterial tension and hypertrophy of the heart. The high arterial tension was, I take it, due to increased peripheral resistance from a tonic contraction of the arterioles and capillaries, induced by some toxic substance in the circulation. In granular kidney the toxin is the result of imperfect elimination by the diseased organ.

In the second group of cases the toxin was not due to imperfect elimination by the kidney. The high arterial tension probably antedated by many years disease of the kidney vessels, and the toxins which induced hypertonicity in the peripheral arterioles also gave rise to thickening and degenerative changes in the renal vessels. These toxins might be introduced from without—*e.g.* lead—or they might be generated in the body,

and, as Professor Clifford Allbutt has already suggested, be due to imperfect metabolism. In this class of case heredity and the gouty diathesis are important factors. The increased peripheral resistance induces hypertrophy of the heart and muscular coat of the systemic vessels, but the cerebral vessels, being unsupported and poorly provided with muscular tissue, become dilated under the constant and increasing pressure; their nutrition is interfered with; thickening and degenerative changes occur in the subendothelial tissue; the muscular coat becomes atrophied and thinned over the bulging necrotic tissue, and rupture frequently occurs. This type of degeneration, common in the aorta and cerebral vessels, is not met with in the kidney, in which thickening and hyaline degeneration of the intima and adventitia and hyaline degeneration of the glomeruli are the most characteristic lesions. From the analogy of amyloid degeneration which is produced by some prolonged toxæmia, and to which hyaline degeneration is akin, I think it probable that toxic products in the circulation are the predominant factors in vascular degenerations in the kidney, while high arterial tension is mainly responsible for the lesions in the cerebral vessels.

In regard to degenerative changes in the aorta, with which aneurysm is so frequently associated, intermittent strain associated with arduous occupations, as Professor Clifford Allbutt originally suggested, is doubtless responsible in many instances. Syphilis is, however, in a large proportion of cases an important etiological factor. Clinically, from the age and occupation of the patient, the history of the case, the condition of the vessels, and the presence or absence of high arterial tension, it is possible in the majority of cases to arrive at a correct diagnosis as to the etiology of the lesion. *Post mortem*, from the macroscopical appearance of the aorta, it is not possible to come to any definite conclusion. Dr. Mott has called attention to endarteritis obliterans of the vasa vasorum in syphilis, and in several instances I have, on microscopic examination, found endarteritis obliterans of the vasa vasorum corresponding to diseased areas in the aorta: in two cases there was a clear history of syphilis. It is possible, therefore, that microscopical examination of an atheromatous aorta may give us a clue as to the etiology, syphilitic or otherwise, of the condition; but I should not, at present, venture to make any definite statement to that effect.

DR. F. PARKES WEBER

observed that, admitting the justness of Dr. Savill's contention that the unstriped muscle ought to be considered the parenchymatous tissue of the arterial walls in the same sense that cardiac muscle was termed the parenchymatous tissue of the heart walls, he (Dr. Weber) thought it followed that arterial hypermyotrophy bore the same relation to arteriosclerosis that cardiac hypermyotrophy bore to cardiosclerosis. The discussion that evening had centred rather on arterial hypermyotrophy than on arteriosclerosis. Dr. Weber thought that in most cases the hypertrophy in the muscular part of the arterial walls served a useful (that was, a compensatory[1]) purpose and illustrated the laws of *action and reaction* which governed vital phenomena in general. Apparent exceptions were, however, to be found in cardiac or arterial hypermyotrophy of nervous origin, such as the cardiac hypermyotrophy sometimes met with in persistent or frequently recurrent tachycardia without valvular disease (some cases of Graves's disease) and the arterial hypermyotrophy sometimes met with in limbs affected by conditions allied to erythromelalgia and Raynaud's symptom-complex. These apparent exceptions to the general rule of vital reaction doubtless arose from portions of the nervous system (concerned in the reactions in question) themselves being abnormal. Owing to the part played by the nervous system in regulating the circulation of blood (vasomotor reactions) it was obvious that disordered conditions of the nervous system (and, therefore, chronic and frequently recurrent worry, pain, and unnatural excitement, also the abuse of tea and coffee and of foods and drugs acting on the nervous system) might play an important *rôle* in the etiology of chronic diseases of the blood-vessels—and in regard to the treatment of individual patients this was a point for consideration. As a possible, though very rare, cause of arterial hypermyotrophy Dr. Weber instanced a condition on which Professor Osler and others had recently written, in which the blood was

[1] The arterial hypermyotrophy should not therefore, in Dr. Weber's opinion, be regarded as a true senile change. On the contrary, given any cause for frequent vaso-constriction, the hypermyotrophy occurs more readily in middle life than in old age.

about twice as rich as it normally ought to be in red corpuscles. Such an extreme increase in the proportion of corpuscles must necessarily augment friction and render the passage of the blood through the arterioles and capillaries more difficult.

Since this discussion Dr. Weber has, with the kind assistance of Dr. J. H. Watson, succeeded in experimentally proving that, other conditions being similar, a great increase in the percentage of corpuscles does decidedly raise the resistance to the passage of blood through capillary channels—that is to say, it raises the viscosity of the blood. Professor J. McFadyean kindly provided them with a glass vessel containing 1000 c.c. of fresh horse's blood, in which clotting had been prevented by the addition of 10 grammes of a 50 per cent. aqueous solution of potassium citrate. The corpuscles were given time to sink to the bottom of the vessel until two distinct strata were formed—a lower opaque red one containing almost only blood-corpuscles, and an upper clear yellow one consisting of blood-plasma. It was then easy by the help of a pipette to obtain samples suitable for the proposed purpose, as follows: (1) A sample of the blood-plasma of specific gravity 1025; (2) A sample of the corpuscular stratum; (3) A sample obtained by mixing one part of the corpuscular stratum with three parts of the plasma, the specific gravity of the mixture being about 1040; (4) A sample obtained by mixing one part of the corpuscular stratum with seven of the plasma, the specific gravity being about 1030. By means of a Thoma-Zeiss hæmocytometer, it was found that the proportion of red cells in the first mixture (that is, No. 3) was four millions per cubic millimetre; therefore, the proportion in the other mixture (No. 4) was about two millions per c.m. The four different samples were then compared in regard to viscosity by allowing them to run through a long glass capillary tube with a bulb in the upper part (for the pattern for which they were indebted to the kindness of Professor A. Schuster, F.R.S., of Manchester), the time taken by the upper surface of the liquid to pass from a mark on the glass tube above the bulb to another mark below the bulb being carefully noted in each case. Distilled water took 43 seconds; the blood-plasma (No. 1) took 65½ seconds; the second mixture (No. 4) took 84 seconds. The first mixture (No. 3) took 110 seconds. The exact time taken by the sample of corpuscular stratum (No. 2) was not ascer-

tained, as it evidently would have taken half an hour or longer. The temperature was constant during these experiments, and as the specific gravities of the different samples were obtainable, it would have been easy, as Professor Schuster pointed out, to find out the coefficient of viscosity of each sample. All that was required, however, was to prove, as was actually done, that increase of the corpuscular elements was accompanied by a decided rise in the viscosity of the blood.

Vide Weber and Watson, "Ueber die Abhängigkeit der Viscosität—innerer Reibung—des Blutes von der Zahl der Blutkörperchen," *Folia Hæmatologica*, Berlin, July, 1904, vol. i, p. 392; see also Weber and Watson, "Chronic Polycythæmia with Enlarged Spleen," *Transactions of the Clinical Society of London*, vol. xxxvii, and Weber, "Polycythæmia with Enlarged Spleen and Chronic Erythromelalgia of the Left Foot," *ibid.*

32. *On the cytology of malignant growths.*

By C. E. Walker.

[With Plate IX.]

De neoplasmatum malignorum cytologiâ.

(Cum tabulâ IX.)

Summarium.

In neoplasmatum malignorum cytologiâ indagandâ ego cum collegis meis, J. B. Farmer et J. E. S. Moore, fissionem "heterotypicam" in cellulis progredi inveniebamus.

In findendo hæ cellulæ deminutionem in chromosomatum numero ostendunt, atque, insuper, adsunt illæ chromosomatum formæ quæ ad telam generativam pertinent.

Has formas "heterotypicas" in omnibus neoplasmatum malignorum exemplis a nobis indagatis inveniebamus; in aliis telis, ex contrario, aut normalibus aut morbidis, non inveniuntur.

Tela, deinde, ex quâ neoplasma malignum constat, aliis modis ad similitudinem telæ normalis generativæ accedit.

Aliquibus modis insignibus, tamen, hæ telæ inter se discrepant. Et similitudines et dissimilitudines indicamus nomine "gametoides," quod nomen cellulis neoplasmatum malignorum maturis imponimus, ut hæ cellulæ distinguantur ab cellulis illis gameticis quæ ex telâ gametogenicâ oriuntur.

Indicium nullum certum cellularum sexus unquam adhuc notavimus; et nucleorum conjunctionis exempla ab aliis auctoribus descripta, aut suspecta, aut saltem perpauca et ad conclusiones deducendas inutilia esse judicamus.

In neoplasmatibus quibusdam fissio homotypica maxime frequenter apparet. In cellularum generationibus multis fissio homotypica fissionem heterotypicam consequi videtur.

In hoc modo cellulæ animalium gameticæ gametoidesque inter se maxime differunt. In plantis, tamen, fissio homotypica per multas cellularum generationes fissionem heterotypicam consequi potest. Cellulæ quæ, chromosomatum numero deminuto, se findunt, forsitan cum signis parasiticis induuntur.

Hæc est in nonnullis plantis ratio telæ gametogenicæ normalis.

Postquam fissionem heterotypicam in neoplasmatum malignorum cellulis descripseramus (Proceedings of the Royal Society, London, December, 1903), idem ab aliis (Bashford et Murray) in neoplasmatibus malignis non ex homine solum sed ex animalibus vertebratis descriptum est.

De fissionis, chromosomatum numero deminuto, causis dicere solum possumus stimulos quosdam mitosem heterotypicam in plantis aliquibus celeriter incitare.

Cellula somatica, stimulis aptis adhibitis, se findere posse videtur, numero chromosomatum deminuto: posthac

cellula illa sine fertilisatione signa somatica non recuperare potest.

Valde utiles esse credimus observationes de mitose in neoplasmatum naturâ diagnosticandâ, quum in neoplasmatibus benignis nulla mitosis aut heterotypica aut homotypica appareat.

(*Mense Maio*, 1904.)

ADDENDUM.

De Spermatogenesis et neoplasmatum malignorum cytologiâ comparatâ.—Post dissertationem præcedentem ego et collegæ mei indagare potuimus fissionis in cellulis modum qui ad spermatogenesem humanam pertinet.

Ratio brevis modi quem testis cellulæ monstrant et illius qui ad neoplasmata maligna pertinet probat investigationes nostras posteriores cum re prius indagatâ rationem habere.

In corpore humano spermatogenesis hoc modo in cellulis progreditur.

(*a*) Fissio somatica in cellulis extremis tubulorum testis.

(*b*) Formæ synapticæ; *i.e.* in cellulis videntur nuclei earum formarum quæ fissioni heterotypicæ semper antecedunt.

(*c*) Fissionis heterotypicæ formæ hic illic in insulis dispositæ.

(*d*) Fissionis homotypicæ formæ fissionem heterotypicam subsequentes, hic illic in insulis dispositæ.

(*e*) Spermatidum transmutatio in spermatozoa.

Modi omnes sub litteris (*a*), (*b*), (*c*), (*d*), enumerati cum eis in neoplasmatibus malignis nuper a nobis descriptis omnino congruunt.

Indicia autem haud obscure demonstrant in neoplasmatibus malignis quasdam post-homotypicas cellularum generationes pro (*e*) substitutas fuisse; hoc absolute affirmare, tamen, non ausi sumus. Similitudines, præterea,

insignes inter neoplasmata maligna et telas gametogenicas normales reperiuntur.

Fieri potest ut nuclei sine cytoplasmatis fissione se findant; cellulæ multinucleatæ sæpe inveniuntur, et cellulæ quoque, igitur, quæ aspectum se findendi habent cum polis pluribus, aut quæ duas fissionis formas distinctas continent.

Reperiuntur insuper fissionis modi qui formas hypochromatosis et hyperchromatosis auctoris Hansemann gerunt, necnon formæ in quibus aliquæ e chromosomatibus ejici videntur.

De his formis autem, indagatio sedula docet chromosomata supra dicta quæ sese ejectura esse videntur, haud secus esse quam chromosomatum pauca quædam quæ præmature centrosomata appropinquaverunt et in cellulis ex fissione orituris apparerent.

(*Mense Julio*, 1904.)

A description of what Professor Farmer, Mr. Moore, and I have observed in malignant growths will be facilitated by a brief sketch of what happens in cells which divide mitotically.

In the case of somatic cells—that is, cells which are going to form the ordinary body tissues in both the higher animals and plants—a definite number of small rod-like bodies known as chromosomes appear during the process of division. The number of these chromosomes is constant in each species. When the chromosomes are upon the spindle they are arranged horizontally upon its equatorial plane in the form of delicate rods or V's. They split lengthwise, half of each chromosome going to each resulting daughter cell. It will thus be seen that all the cells forming ordinary body-tissues possess the potentiality of the number of chromosomes proper to the species of animal or plant to which they belong, and exhibit this number during the process of division.

At some time, however, during the life of the organism a time comes when definite sexual elements are produced. The cells which produce these undergo a form of division entirely different to the somatic. This is known as the heterotype division.

In the heterotype division the chromosomes appear in only half the number found in the somatic cells. Besides this important and striking reduction in number to half that normally found in the cells of the organism, the form and manner of arrangement of the chromosomes upon the spindle are also very unlike that seen in somatic division figures. The heterotype chromosomes appear as rings, loops, etc., much thicker in diameter than the somatic; they are arranged at right angles to the equatorial plane of the spindle; and lastly, they divide transversely instead of lengthwise. It will now be realised that the heterotype mitosis is generally easily distinguishable from the somatic, even when it is impossible to count the number of chromosomes.

The cells which are destined to undergo the heterotype mitosis are distinguishable from those which are not, sometimes even two or three generations beforehand. The cells following the heterotype mitosis divide in a manner similar to the somatic form of division, except that these cells only exhibit half the somatic number of chromosomes. This post-heterotype division is known as homotype, and though in mammalia there is only one homotype between the heterotype division and the production of spermatozoa, in plants there is often a great number of generations of reduced cells, which sometimes even form a separate organism.

When Professor Farmer, Mr. Moore, and myself studied the minute cytology of malignant growths, we found heterotype division figures. We have found them in all the malignant growths we have examined, and we have not found them in any other body tissues, whether normal or pathological. In some tissues—*e.g.* inflammatory tissue—there is a large number of somatic divisions, but nothing like a heterotype.

The tissue forming malignant growths resembles normal sexual reproductive tissue in other respects than in the presence of the heterotype division figures. There are, however, some marked points of difference between them. We have emphasised both the similarity and differences by designating the mature malignant cells as "gametoid," to distinguish them from the gametic cells which arise from gametogenic tissue.

Up to the present we have not seen anything in gametoid tissue which could be interpreted into the production of definite

sexual elements. Homotype divisions are very numerous in some growths, and several generations of cells seem to be produced subsequent to the heterotype division, all being exactly similar to the homotype—that is, the first division after the heterotype.

In these points lies the greatest difference between gametic and gametoid cells in the case of animals. In the case of plants, however, the heterotype division is followed, not by only one homotype mitosis, but by a variable and often large number of cell generations which all divide homotypically (*i.e.* retain the reduced number of chromosomes). These cells may form a definite tissue or even a separate organism, only certain of the cells of which ever finally differentiate into sex cells. It will thus be seen that there is nothing inherently impossible or even improbable in the occurrence of a number of homotype generations in cells that have gone through the heterotype division, though circumstances are such that this does not occur in the production of sexual elements in animals.

The facts that are already known with regard to the behaviour of tissue formed of cells which are destined to undergo or have undergone a reduction division seem to point to the probability that such tissue, under certain conditions at any rate, possesses parasitic characteristics. In some plants gametogenic tissue normally acts thus.

It may be taken as a general rule that unless reduced cells are fertilised, they cannot produce somatic tissues. The gametogenic tissue which normally gives rise to the only reduced cells occurring in the body is, in the case of animals at any rate, immediately turned into sexual elements, and the normal somatic number of chromosomes is restored in the fertilisation of the ovum, the nuclei of the spermatozoon and ovum each containing half the somatic numbers, fusing to attain this end. Up to the present we have seen nothing in malignant growths which could be seriously interpreted as evidence of such fertilisation or fusion. The occurrence of reduced cells naturally suggests the probability or possibility of fusion, and to us it did so particularly in view of what happened in the case of certain ferns observed by Professor Farmer, Mr. Moore, and Miss Digby more than a year ago. Here the application of suitable stimuli to prothallial tissue caused the nuclei of adjacent cells to fuse,

EXPLANATION OF PLATE IX,

Illustrating the communication by Mr. C. E. Walker on the "Cytology of Malignant Growths." (P. 4[illegible].)

Fig. 1. Showing spindle and chromosomes [illegible] in a somatic division. Note the long [illegible] spitting [illegible] diagrammatic.

Fig. 2. Showing spindle and chromosomes [illegible] in a heterotype division. Note the greater thickness [illegible] various shapes, and the transverse division shown in one of them (semi-diagrammatic).

Fig. 3. Showing spindle and chromosomes in a somatic division occurring at the edge of an epidermal [illegible] of the tongue.

Fig. 4. Showing a common arrangement of the chromosomes in a heterotype division (semi-diagrammatic).

Fig. 5. Showing another common arrangement of the chromosomes in a heterotype division (semi-diagrammatic).

Fig. 6. Showing the arrangement of the chromosomes in a homotype division (polar view) occurring in [illegible].

Fig. 7. Prophase of the heterotype division (synaptic prophase). From human testis.

Fig. 8. The same stage in a cellular epithelioma of the penis.

Fig. 9. Heterotype aster from human testis showing the arrangement and [illegible] approached one [illegible] considerably before the [illegible].

Fig. 10. Heterotype aster from [illegible] of rectum.

Fig. 11. Heterotype aster from [illegible] of tongue.

Fig. 12. Heterotype aster from [illegible] testis.

Figures 1, 2, 4, 5 are given as general illustrations, and are not taken [illegible].

TABULA IX.

[illegible] certationem "De Neoplasmatum Malignorum Cytologia" illustrandam.

C. E. Walker. (P. 149.)

[illegible] curam somata atque cellulae fusus ut in [illegible]

[illegible] chromosomata atque cellulae fusus ut in [illegible] Chromosomatum notandae sunt [illegible] fissio [illegible] versa.

[illegible] chromosomata atque cellula fusus in fissione [illegible]

Fig. 4. [illegible] dispositio vulgaris ut in [illegible]

[illegible] dispositio alia vulgaris [illegible]

[illegible] positio et forma chromosomatum [illegible] in cellula ex carcinomate [illegible]

[illegible] heterotypica [illegible]

[illegible] in cellula ex penis carcinomate [illegible] in cellula ex teste humano [illegible] Notandum est quod [illegible] adhuc ad equatorem [illegible] in cellula ex intestini recti [illegible] in cellula ex linguae carcinomate [illegible] in cellula ex teste humano [illegible] figurae 1, 2, 4, 5 non repraesentant.



Fig. 1.

Fig. 2.

Fig. 3.

Fig. 4.



Fig. 5.

Fig. 6.

Fig. 7.

Fig. 8.

Fig. 9.

Fig. 10.

Fig. 11.

Fig. 12.

EXPLANATION OF PLATE IX,

Illustrating the communication by Mr. C. E. Walker on the "Cytology of Malignant Growths." (P. 449.)

FIG. 1.—Showing spindle and chromosomes as they appear in a somatic division. Note the longitudinal splitting of chromosomes (semi-diagrammatic).

FIG. 2.—Showing spindle and chromosomes as they appear in a heterotype division. Note the greater thickness of the chromosomes, their various shapes, and the transverse division shown in one of them (semi-diagrammatic).

FIG. 3.—Showing spindle and chromosomes in a somatic division occurring at the edge of an epithelioma of the tongue.

FIG. 4.—Showing a common arrangement of the chromosomes in a heterotype division (semi-diagrammatic).

FIG. 5.—Showing another common arrangement of the chromosomes in a heterotype division (semi-diagrammatic).

FIG. 6.—Showing the arrangement and form of the chromosomes in a homotype division (polar view) occurring in an epithelioma.

FIG. 7.—Prophase of the heterotype division (synaptic prophase). From human testis.

FIG. 8.—The same stage in a cell in an epithelioma of the penis.

FIG. 9.—Heterotype aster from human testis, showing the arrangement and form of the chromosomes. Note that two chromosomes have approached one of the poles considerably before the others.

FIG. 10.—Heterotype aster from carcinoma of rectum.

FIG. 11.—Heterotype aster from epithelioma of tongue.

FIG. 12.—Heterotype aster from human testis.

Figures 1, 2, 4, 5 are given as general illustrations, and are not taken from human tissue.

TABULA IX.

Ad dissertationem "De Neoplasmatum Malignorum Cytologiâ" illustrandam.

C. E. Walker. (P. 449.)

FIG. 1.—Monstrantur chromosomata atque cellulæ fusus ut in fissione somaticâ apparent.

FIG. 2.—Monstrantur chromosomata atque cellulæ fusus ut in fissione heterotypicâ apparent. Chromosomatum notandæ sunt crassitudo, formæ diversitas, et cujusdam fissio transversa.

FIG. 3.—Monstrantur chromosomata atque cellulæ fusus in fissione somaticâ ut in linguæ carcinomate videntur.

FIG. 4.—Monstratur chromosomatum dispositio vulgaris ut in fissione heterotypicâ apparet.

FIG. 5.—Monstratur chromosomatum dispositio alia vulgaris ut in fissione heterotypicâ apparet.

FIG. 6.—Monstrantur dispositio et forma chromosomatum, ex polo conspectorum, ut in fissione homotypicâ in cellulâ ex carcinomate apparent.

FIG. 7.—Monstratur prophasis fissionis heterotypicæ (prophasis synaptica) in cellulâ ex teste humano.

FIG. 8.—Monstratur phænomenon idem in cellulâ ex penis carcinomate.

FIG. 9.—Astrum heterotypicum in cellulâ ex teste humano; monstrantur dispositic et chromosomatum forma. Notandum est quod duo chromosomata ad unum e fusi polis appropinquaverint, aliis adhuc ad equatorem relictis.

FIG. 10.—Astrum heterotypicum in cellulâ ex intestini recti carcinomate.

FIG. 11.—Astrum heterotypicum in cellulâ ex linguæ carcinomate.

FIG. 12.—Astrum heterotypicum in cellulâ ex teste humano.

Cellulas ex telis humanis figuræ 1, 2, 4, 5 non repræsentant.



Fig. 1

Fig. 2

Fig. 3

Fig. 4

Fig. 5



Fig. 6



Fig. 7

Fig. 8

[illegible] IX,

[illegible] F. Walz [illegible]

[illegible]

[illegible] heterotype

[illegible]

[illegible] From

[illegible]

[illegible]

[illegible]

ssertatio[illegible]tum M[illegible]ytologia [illegible]

[illegible]

[illegible]

[illegible]

Fig. 1.

Fig. 2.

Fig. 3.

Fig. 4.



Fig. 5.

Fig. 6.



Fig. 7.



Fig. 8.

Fig. 9.



Fig. 10.

Fig. 11.

Fig. 12.

fertilisation and the production of the succeeding generation taking place in some cases without any sexual elements appearing.

We regard the alleged cases of nuclear fusion in malignant growths as too doubtful or at any rate too few, to provide a sound basis for any generalisation.

The facts that heterotype division figures are less numerous than the somatic at the growing margin of the tumour, that at a certain zone within this the heterotypes are most numerous,

FIG. 82.

Group of homotype cells from a carcinoma of the uterus.

EXPLICATIO FIGURÆ.

Sectio microscopica ex uteri carcinomate, cellularum quarumdam fissionem homotypicam monstrans.

and that the homotypes occur in localised areas within the growth in large numbers, are all points of resemblance between malignant growths and gametogenic tissue.

We attach great importance to the occurrence of the heterotype mitosis, and regard it and the consequent production of reduced tissue as being intimately connected with the malignant character of the growths in which it is found. Since, on December 10th last, we recorded its presence in carcinomata and sarcomata occurring in man in a communication to the Royal Society, its presence in malignant growth occurring in

many other vertebrates as well as in man has been recorded by the representatives of the Cancer Research Fund.

As to the causes bringing about the reduction division, it is possible only to draw suggestions from what happens in the case of certain plants. Here we know that the application of appropriate stimuli—for instance, particular coloured light, variations in moisture or dryness, abundance and absence of food—will bring about the heterotype mitosis rapidly. One thing seems quite certain: given the proper stimulus or stimuli, any somatic cell may go through a reduction division and cannot regain its somatic characteristics without fertilization.

As an aid to diagnosis in doubtful cases of new growth we have found the observation of the heterotype and homotype mitoses to be of considerable practical value. I can call to mind two cases in particular where a further operation followed the removal of a small portion of a new growth upon our having found numerous heterotype figures in them. Ordinary pathological methods failed to show that the portions of the growths first removed were malignant. The subsequent operations in both cases confirmed our diagnosis absolutely. To put it briefly: if heterotype mitosis is found in a new growth, that growth is malignant. As the homotype mitosis follows the heterotype, its presence is equally diagnostic. Hitherto we have almost always found both these mitotic figures to be very abundant in malignant growths. The only exception to this is in the case of slowly growing tumours (*e.g.* scirrhus of the breast), where mitotic figures are not numerous.

In order to obtain material in which mitotic figures can be observed with any degree of certainty, it is necessary to use cytological methods of fixation and staining. This, however, is by no means necessarily a lengthy proceeding. It is easy, without any undue hurry, to have material fixed in acetic and alcohol, embedded in paraffin, cut, stained, and mounted in Canada balsam within three hours of removal from the body. Among the specimens under the microscopes to-night is one of an epithelioma of the tongue removed after four o'clock this afternoon by Mr. Clutton.

I am glad that I have been given this opportunity of correcting certain misconceptions which are apparent in recent

criticisms and comments upon our paper communicated to the Royal Society in December last.

May 17th, 1904.

ADDENDUM.

Spermatogenesis and the Cytology of Malignant Growths.

Since my communication in May last my collaborators and I have had the opportunity of studying the cytological changes which occur in the human testis during spermatogenesis.

Up to this time we had not been able to compare the heterotype and homotype division figures which we had found in malignant growths with similar figures occurring normally during the production of definite sexual elements in man. Although throughout the animal and vegetable kingdoms there is a remarkable resemblance between the heterotype figures occurring in different species, there are also points of difference apart from the number of chromosomes. There was, therefore, some doubt as to whether the figures we had found in malignant growths, though undoubtedly heterotypes and homotypes, were the form of heterotype and homotype normal in man. A study of the normal heterotype has shown us that the forms found in malignant growths in man are—a large number of them, at any rate—exactly similar to the normal form found in the functional testis.

Broadly speaking, the following may be said to be the sequence of events in the cell changes preceding the production of spermatozoa : (*a*) Cells upon the periphery of the tubule of the testis, destined eventually to produce spermatozoa, continue to divide somatically—that is, they show the same number of chromosomes and the same figures as the cells which are dividing to produce ordinary body tissues, and as the preceding generations of cells which have produced them (the peripheral cells). (*b*) Following this—that is, in the cells immediately within those adjacent to the periphery—are found cells which are in the synaptic prophase. A brief explanation of the synaptic prophase is here necessary. Before a somatic cell divides, in the vast majority, if not in the case of all animal and plant tissues, the chromatin arranges itself in the form of a long thread within the nuclear membrane. This thread (the spiréme) at the next stage forms the somatic chromosomes. In the case, however, of

a cell which is going to divide heterotypically, and is therefore on the road to produce sexual elements, a series of other changes take place in the chromatin. The spiréme, among other changes, contracts, taking the form of large loops, all apparently rising from approximately the same base. Such a figure is found only before a heterotype division of the cell in which it appears; it never precedes the somatic or homotype division. It is found only during the "synaptic prophase."

(*c*) Patches of heterotype division figures.

(*d*) Homotype division figures, following the heterotype, are also found in patches.

(*e*) Conversion of spermatids into spermatozoa.

The phases included under (*a*), (*b*), (*c*), and (*d*) all correspond with what my collaborators and I have found in malignant growths. In the latter, however, there seems to be good evidence to show that there are several generations of post-homotype divisions, exactly similar in character to the homotype.

Further very important points of resemblance between normal gametogenic tissue and malignant growths are: The nuclei not infrequently divide without the cytoplasm dividing, so that cells with multiple nuclei, and consequently pluripolar division figures, or cells containing two or more independent division figures are not uncommon: Divisions which might readily be construed into the hypo- and hyper-chromatosis of von Hansemann, and figures in which some of the chromosomes are apparently being thrown off. We do not, however, think that the last-named figures can be truly interpreted in this manner, as there seems to be very good evidence, after a careful study of the cells exhibiting them, that these chromosomes which are apparently being thrown off are simply chromosomes which have approached the centrosomes a little earlier than the rest, and are retained in the resulting daughter cells.

July 9th, 1904.

INDEX.

SUBJECTS.

(*For List of Authors see p. 460.*)

PAGE

ARTERIAL SCLEROSIS, opening address in a discussion on (T. D. Savill) . 375
„ — — (C. Allbutt) 438
„ — — (J. Broadbent) 444
„ — — (G. Oliver) 442
„ — — (F. P. Weber) 447

BACILLUS CARNIS (E. Klein) 74
BACILLUS ENTERITIDIS SPOROGENES, a method of detecting, in water (R. T. Hewlett) 123
BACILLUS PYOCYANEUS, pyæmia due to, following otitis media (T. J. Horder) 140
BILE SALTS, estimation of (O. Grünbaum) 55
BLOOD, new method of counting corpuscles (W. M. Strong and C. G. Seligmann) 39
BRAIN, angioma arteriale racemosum (J. H. Drysdale) . . 66
„ dermoid tumour (E. F. Buzzard) 330
BREAST, calcifying chondrosarcoma of (C. A. Morton) 327

COLON, unusual form of obstruction of (C. A. Morton) . . . 329
COUNTING corpuscles of the blood, a new method for (W. M. Strong and C. G. Seligmann) 39
CRETINISM in calves, congenital (C. G. Seligmann) . . . 1

DYSENTERY, agglutination in (R. T. Hewlett) 51
„ epidemic or bacillary; an experimental inquiry concerning (R. H. Firth) 340

GANGRENE, emphysematous, caused by the colon bacillus (L. S. Dudgeon and P. W. G. Sargent) 107

HÆMATOPORPHYRINURIA, a survey of cases, not due to sulphonal (A. E. Garrod) 142
HETEROTYPICAL MITOSIS in malignant tumours (C. E. Walker) . 449

KIDNEY, cystic disease of, and of the liver (C. B. Blackburn) . . 203

LEUKANÆMIA (F. P. Weber) 287
LIVER, cystic disease of, and of the kidney (C. B. Blackburn) . . 203
„ primary sarcoma of, in an infant (E. P. Baumann and J. G. Forbes) . 336

NEPHRITIS, the glomerular lesions of diffuse (parenchymatous) (W. P. Herringham and J. H. Thursfield) 283
NUTROSE-AGAR, preparation of (J. W. H. Eyre) . . . 91

ORBIT, plexiform neuroma of (W. C. Rockliffe and J. H. Parsons) . 27

PAGE

PROSTATE, enlarged, examination of specimens of (S. G. Shattock) . 76
PROSTATECTOMY, an anatomical criticism of the procedure known as total (C. S. Wallace) 255
PSEUDO-LIPÆMIA, sarcoma of the pancreas associated with (J. Fawcett) 332

RHEUMATIC FEVER, the relation of *Staphylococcus pyogenes aureus* to (F. J. Poynton and W. V. Shaw) 126

SERUM, Dr. Otto Schmidt's; carcinoma treated by (R. N. Salaman) . 119
STAPHYLOCOCCUS PYOGENES AUREUS, the relation of, to rheumatic fever (F. J. Poynton and W. V. Shaw) 126
STOMACH, sarcoma of (R. N. Salaman) 296

THYMUS, a contribution to the pathology of the (L. S. Dudgeon) . 151
THYROID, carcinoma of (H. A. Lediard) 60
TUMOUR, angioma arteriale racemosum, brain (J. H. Drysdale) . . 66
„ calcifying chondrosarcoma of breast (C. A. Morton) . . 327
„ carcinoma of thyroid (H. A. Lediard) 60
„ chondroma of knee-joint (R. Johnson) 20
„ dermoid, of brain (E. F. Buzzard) 330
„ malignant, cytology of (C. E. Walker) 449
„ plexiform neuroma of orbit (W. C. Rockliffe and J. H. Parsons) . 27
„ sacro-coccygeal, congenital (H. J. Curtis) 22
„ sarcoma of pancreas associated with pseudo-lipæmia (J. Fawcett) . 332
„ sarcoma of the stomach (R. N. Salaman) 296
„ sarcoma, primary, of liver in an infant (E. P. Baumann and J. G. Forbes) 336

AUTHORS.

ALLBUTT (C.), arterial sclerosis 438

BAUMANN (E. P.) and **FORBES** (J. G.), primary sarcoma of the liver in an infant 336
BLACKBURN (C. B.), cystic disease of the liver and kidney . . 203
BROADBENT (J.), arterial sclerosis 444
BUZZARD (E. F.), a case of dermoid tumour of the brain . . 330

CURTIS (H. J.), congenital sacro-coccygeal tumour . . . 22

DRYSDALE (J. H.), angioma arteriale racemosum . . . 66
DUDGEON (L. S.) and **SARGENT** (P. W. G.), emphysematous gangrene caused by the colon bacillus 107
DUDGEON (L. S.), a contribution to the pathology of the thymus gland . 151

EYRE (J. W. H.), the preparation of nutrose-agar . . . 91

FAWCETT (J.), sarcoma of the pancreas associated with pseudo-lipæmia . 332
FIRTH (R. H.), an experimental inquiry concerning epidemic or bacillary dysentery 340
FORBES (J. G.) : see *Baumann, E. P.*

GARROD (A. E.), hæmatoporphyrinuria not due to sulphonal . . 142

PAGE

GRÜNBAUM (O.), estimation of bile salts 55

HERRINGHAM (W. P.) and **THURSFIELD** (J. H.), the glomerular lesions of diffuse (parenchymatous) nephritis 283
HEWLETT (R. T.), agglutination in cases of dysentery 51
„ detection of *Bacillus enteritidis sporogenes* in water 123
HORDER (T. J.), pyocyaneus pyæmia following otitis media . . . 140

JOHNSON (R.), pedunculated chondroma of knee-joint 20

KLEIN (E.), bacillus carnis 74

LEDIARD (H. A.), thyroidal carcinoma 60

MORTON (C. A.), calcifying chondrosarcoma of the breast . . . 327
„ an unusual form of obstruction of the colon 329

OLIVER (G.), arterial sclerosis 442

PARSONS (J. H.): see *Rockcliffe* (*W. C.*).
POYNTON (F. J.), and **SHAW** (W. V.), relation of *Staphylococcus pyogenes aureus* to rheumatic fever 126

ROCKCLIFFE (W. C.) and **PARSONS** (J. H.), plexiform neuroma of orbit . 27

SALAMAN (R. N.), epithelioma treated by Dr. Otto Schmidt's serum . 119
„ sarcoma of the stomach 296
SARGENT (P. W. G.): see *Dudgeon* (*L. S.*).
SAVILL (T. D.), arterial sclerosis; opening address in a discussion on . 375
SHATTOCK (S. G.), examination of specimens of enlarged prostate . 76
SHAW (W. V.): see *Poynton* (*F. J.*).
SELIGMANN (C. G.), congenital cretinism in calves 1
„ see *Strong* (*W. M.*).
STRONG (W. M.) and **SELIGMANN** (C. G.), new method of counting corpuscles in the blood 39

THURSFIELD (J. H.): see *Herringham, W. P.*

WALKER (C. E.), cytology of malignant growths 449
WALLACE (C. S.), an anatomical criticism of the procedure known as total prostatectomy 255
WEBER (F. P.), a case of leukanæmia 287
„ arterial sclerosis 447

PRINTED BY ADLARD AND SON, LONDON AND DORKING.

ρ

3 2044 102 983 24

44 102 983 244